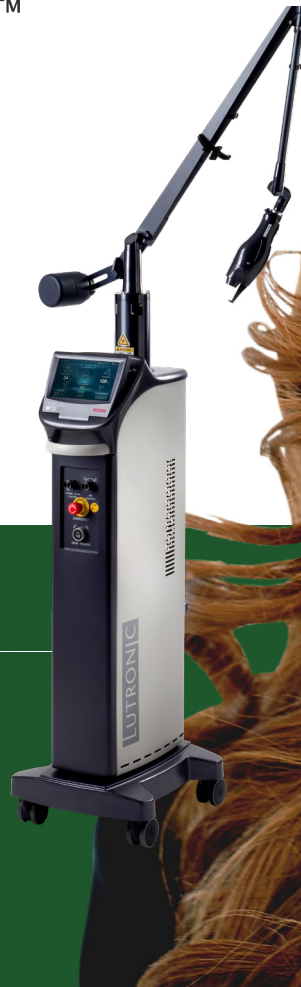

# eCO2 Plus™

Uncovering Youth One Patient At A Time

## Indications

- Acne scars
- Hypertrophic scar
- Traumatic scars
- Deep wrinkles
- Fine wrinkles
- Perioral wrinkles
- Periorbital wrinkles
- Skin laxity
- Pigmentation
- Nevus
- Syringoma•
- Wart
- Others



# SKIN CONCERNS



Want to treat  
**scars?**



Want to improve  
**wrinkles?**



Want to restore skin  
**firmness?**



Want to remove  
**pigmentation?**

# eCO2 PLUS TREATMENTS

eCO2 Plus treatment is a perfect solution that has various benefits.

## **Fractional Laser Treatment**

reduces downtime and brings the best result

## **Controlled Chaos Technology (CCT)**

minimizes heat build-up and side-effects

## **Various Scan Type**

provides ideal scan types to fit your treatment areas

## **Globally Proved**

result and safety are globally proven by thousands of cases

# INDICATIONS



Scan QR code to watch video



## Scars

- Acne scars
- Hypertrophic scar
- Traumatic scars

## Wrinkles

- Deep wrinkles
- Fine wrinkles
- Perioral wrinkles
- Periorbital wrinkles

## Skin laxity

## Syringoma

## Pigmentation

## Wart

## Nevus

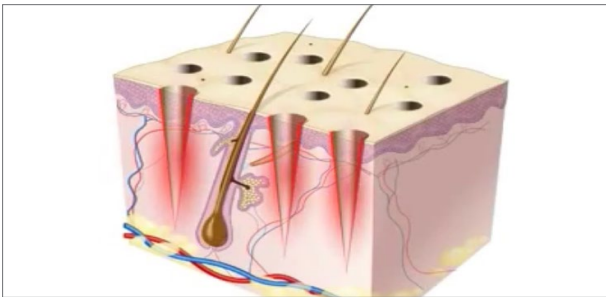
## Others



# HOW DOES ECO2 PLUS WORK?

Fractional resurfacing by eCO2 Plus promises to reduce skin imperfections and promote collagen regeneration for long term result.

Laser energy micro-ablates tissue leaving small micro-wounds bridged by healthy tissue. Your body's natural healing process stimulates the creation of new tissue and collagen for a younger more youthful appearance of the skin.

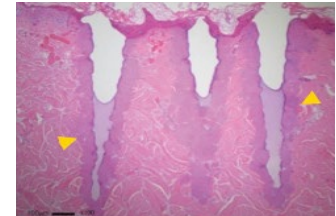


Scan QR code to watch video



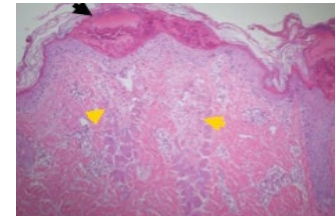
## IMMEDIATELY AFTER

The laser creates micro-ablated columns to stimulate cells. The surrounding healthy tissue promotes rapid healing



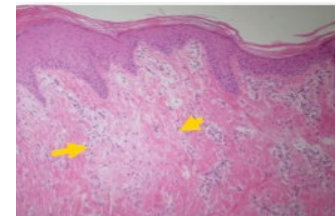
## 2 DAYS POST

Skin is healing creating new collagen during wound healing process.

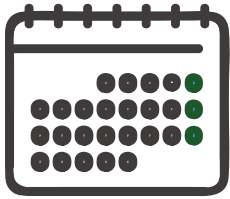


## POST 14 DAYS

Outer layer of skin is completely healed and collagen remodeling continues for up to nine months.



# eCO2 Plus Treatment



## TREATMENT SESSIONS

Your physician will advise you how many sessions you need depending on our conditions.



## CLINICAL RESULTS

Within a few days, new skin will appear that is smoother and more even-toned. Your skin will continue to improve over six to nine months.



## PAIN LEVEL

There is a certain level of pain during treatment. However, your doctor will minimize your discomfort by giving topical or oral anesthetic.

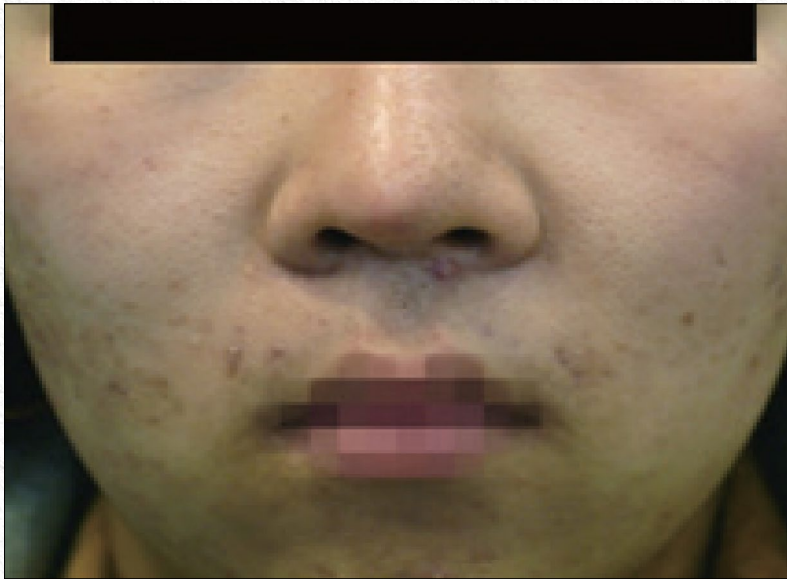


## SAFETY

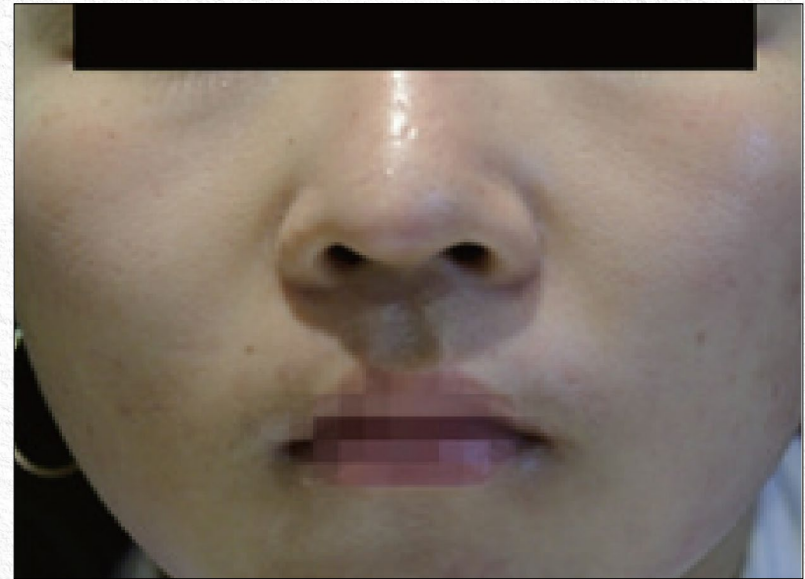
The eCO2 Plus is designed with the finest operating features possible to provide you and your doctor the greatest margin of safety during the procedure.

CLINICAL PHOTOS

# Acne Scars



**Before**



**After**

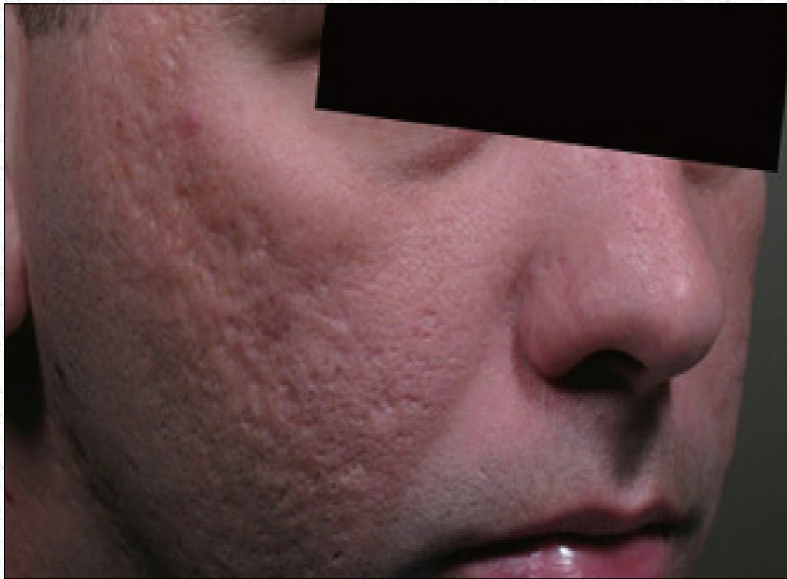*Courtesy of KT Hong, MD, South Korea*

*\* Results may vary by individuals.*

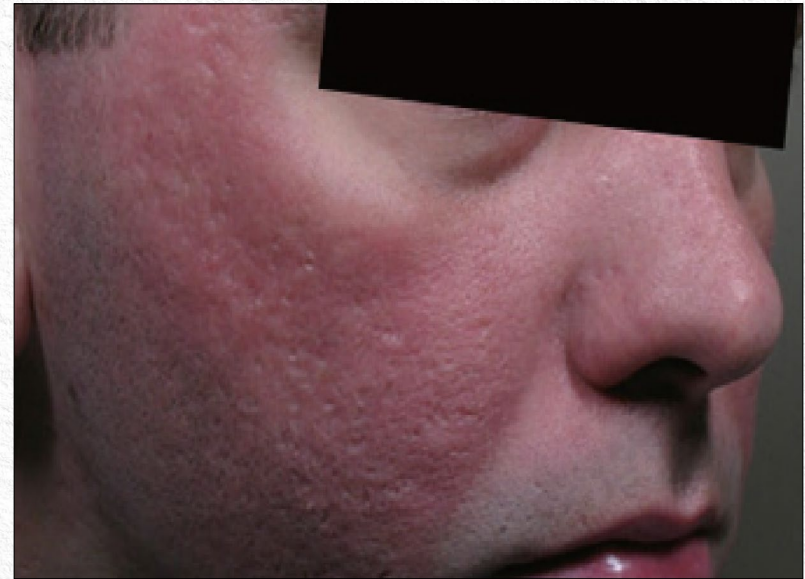

CLINICAL PHOTOS

# Acne Scars



**Before**



**After**

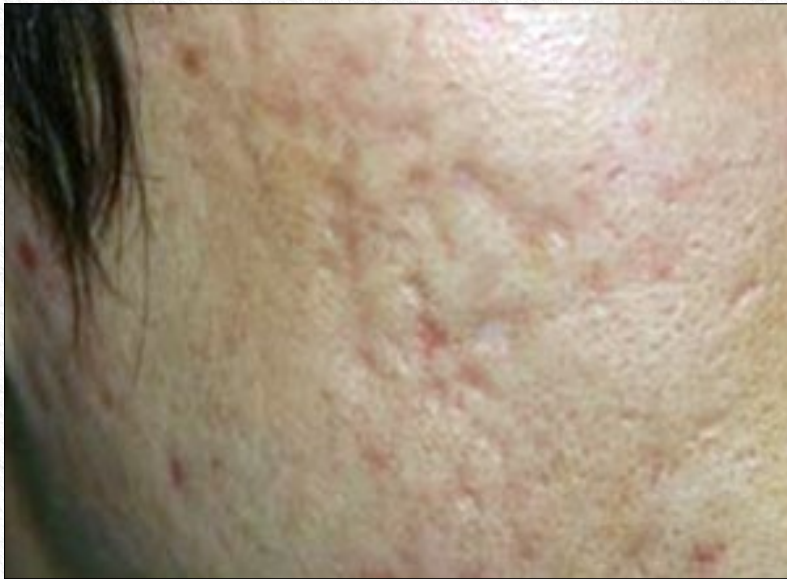*Courtesy of Jeffrey Rappaport, MD, USA*

*\* Results may vary by individuals.*

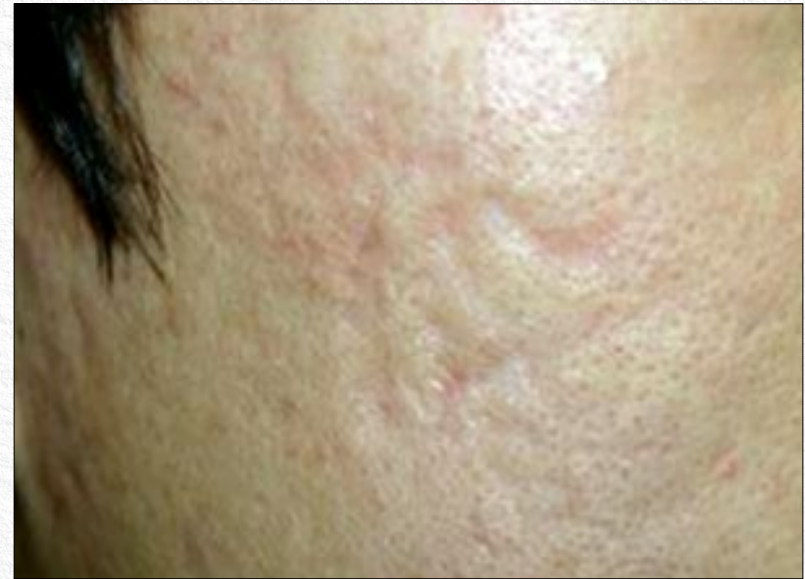

CLINICAL PHOTOS

# Acne Scars



**Before**



**After**

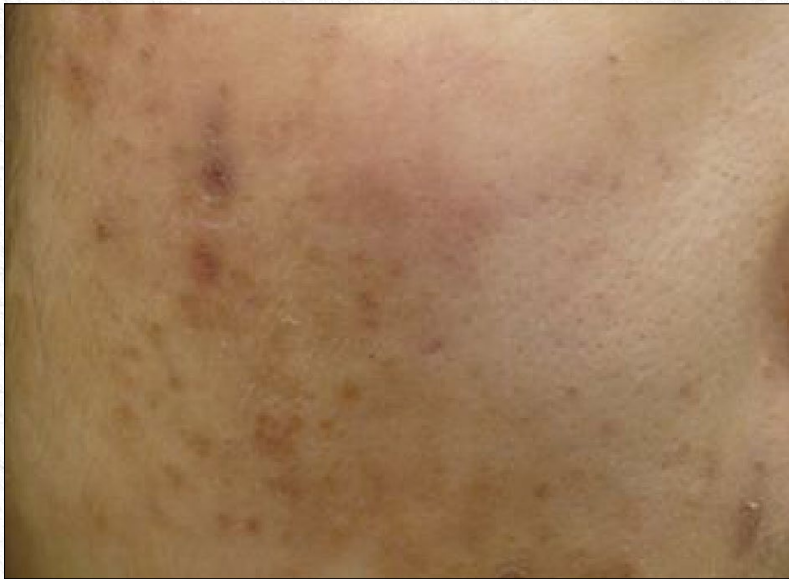
*Courtesy of WS. Kim, MD, South Korea*

*\* Results may vary by individuals.*

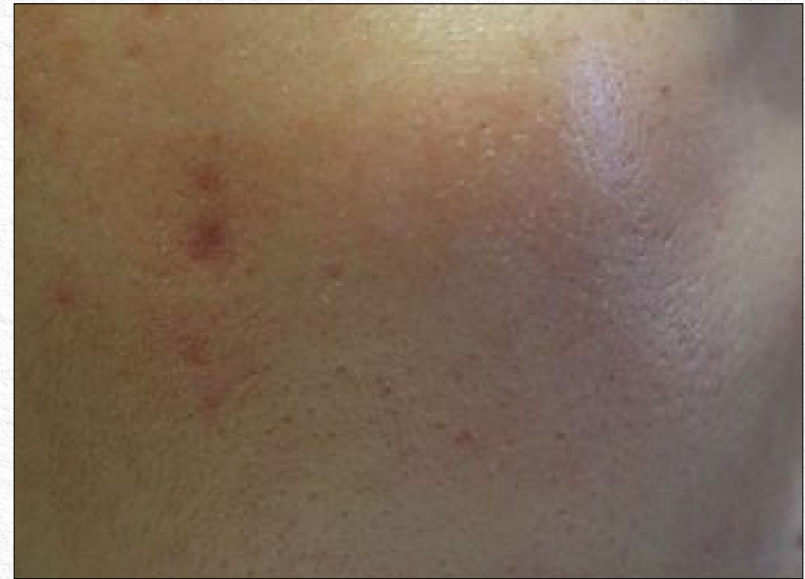

CLINICAL PHOTOS

# Acne Scars



**Before**



**After**

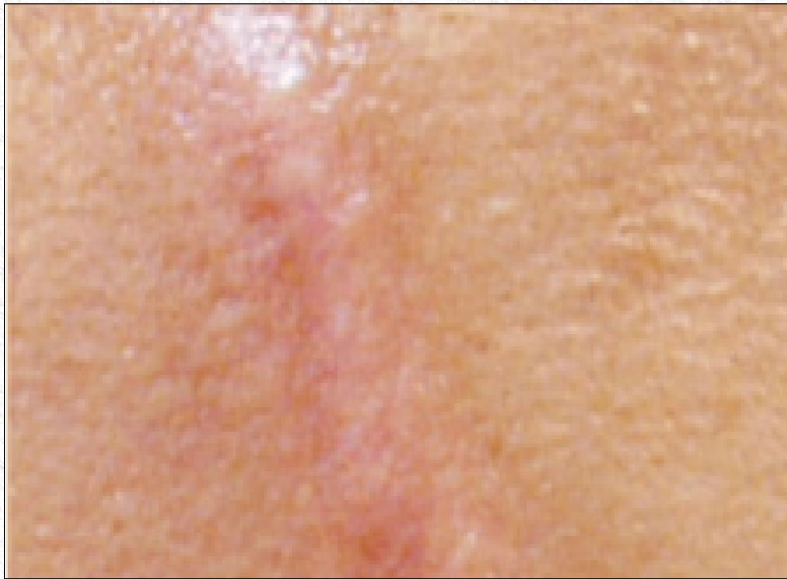*Courtesy of KT Hong, MD, South Korea*

*\* Results may vary by individuals.*

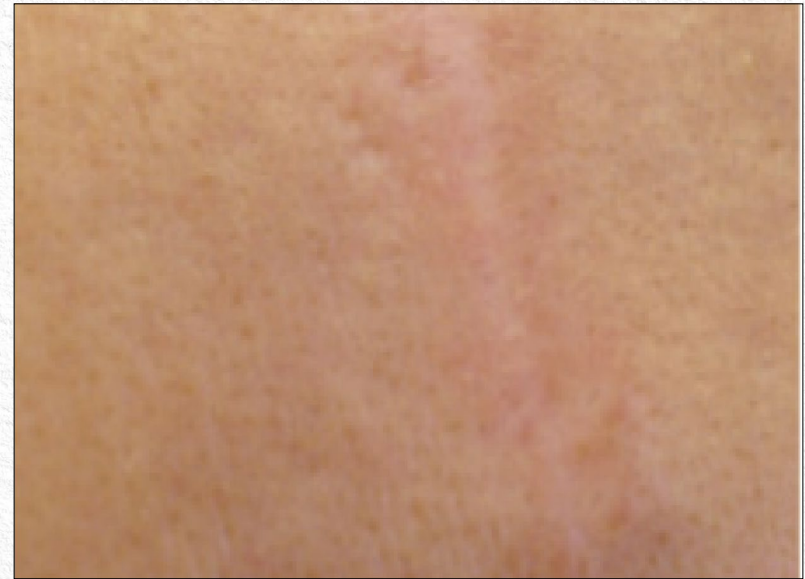

CLINICAL PHOTOS

# Hypertrophic Scar



**Before**



**After**

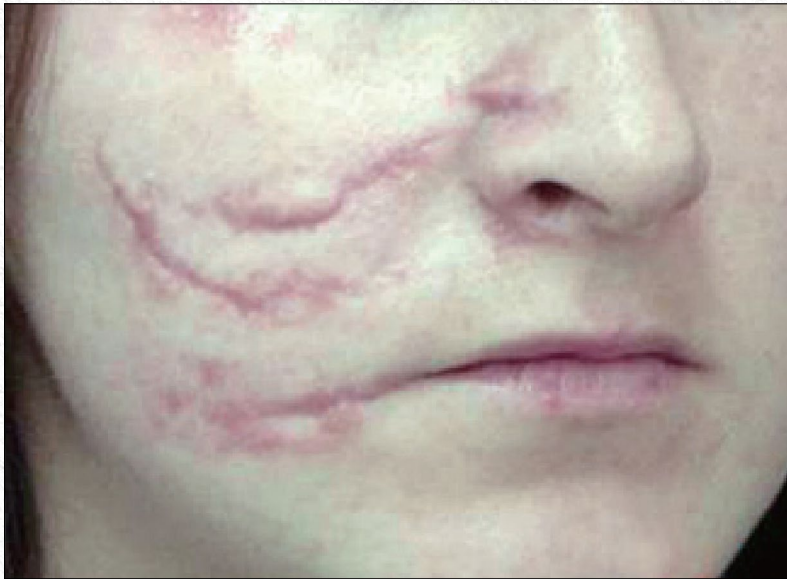*Courtesy of KT Hong, MD, South Korea*

*\* Results may vary by individuals.*

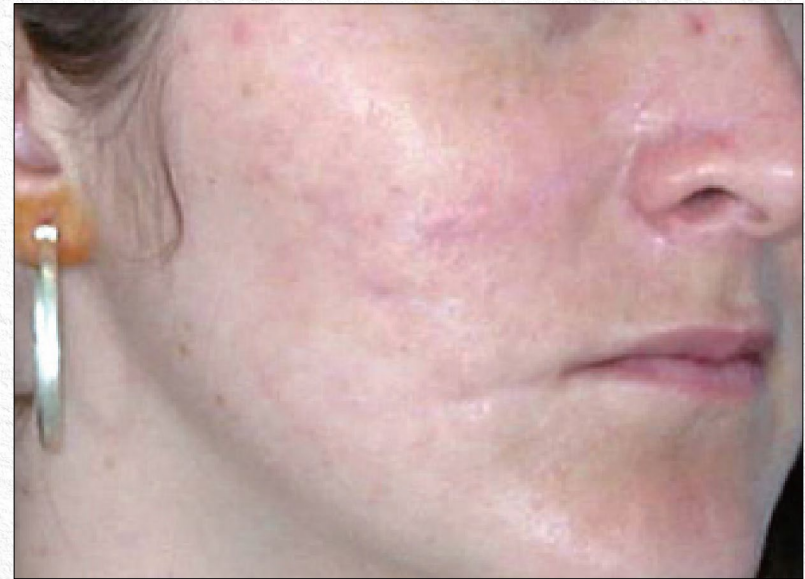

CLINICAL PHOTOS

# Traumatic Scars



**Before**



**After**

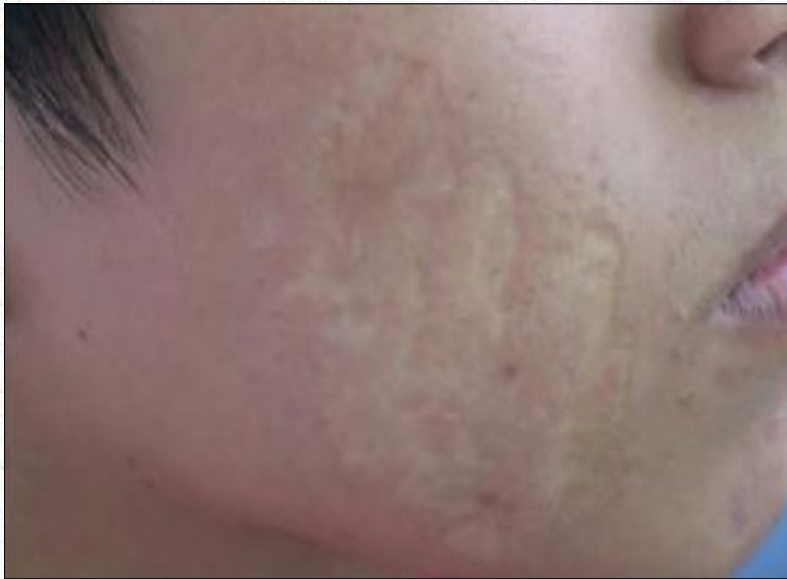*Courtesy of Hernando Harker, MD, Colombia*

*\* Results may vary by individuals.*

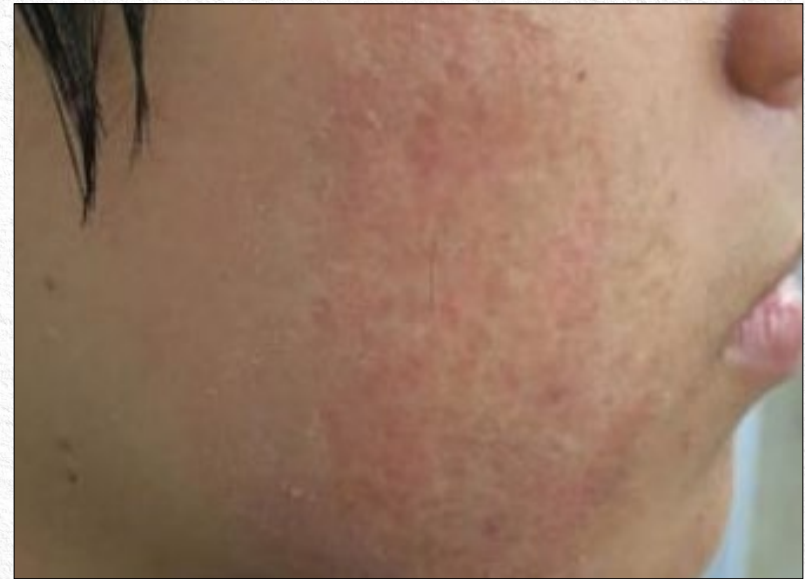

CLINICAL PHOTOS

# Burn Scar



**Before**



**After**

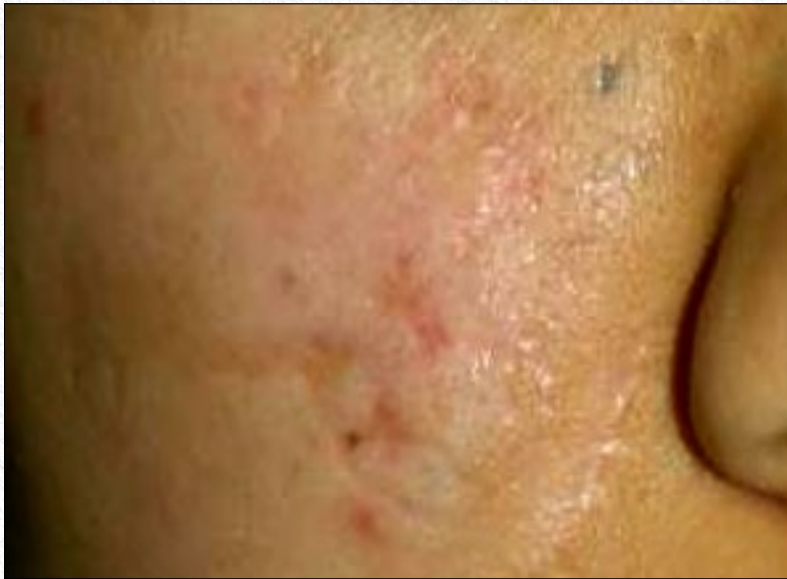*Courtesy of Kateryn Pérez Willis, MD, Peru*

*\* Results may vary by individuals.*

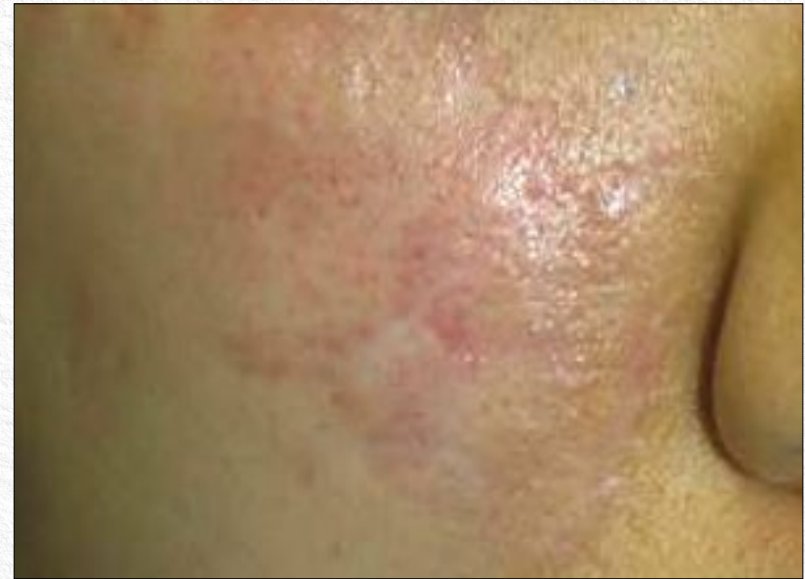

CLINICAL PHOTOS

# Burn Scar



**Before**



**After**

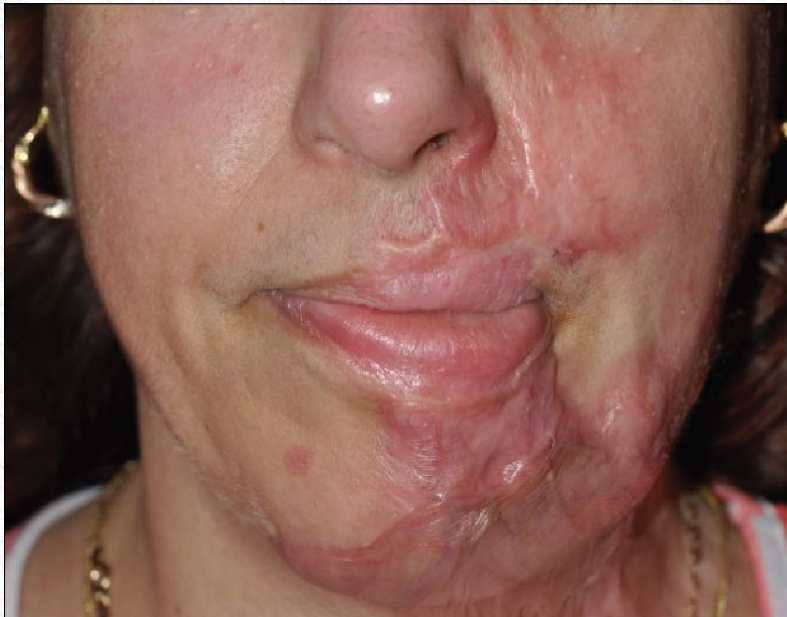*Courtesy of WS Kim, MD, South Korea*

*\* Results may vary by individuals.*

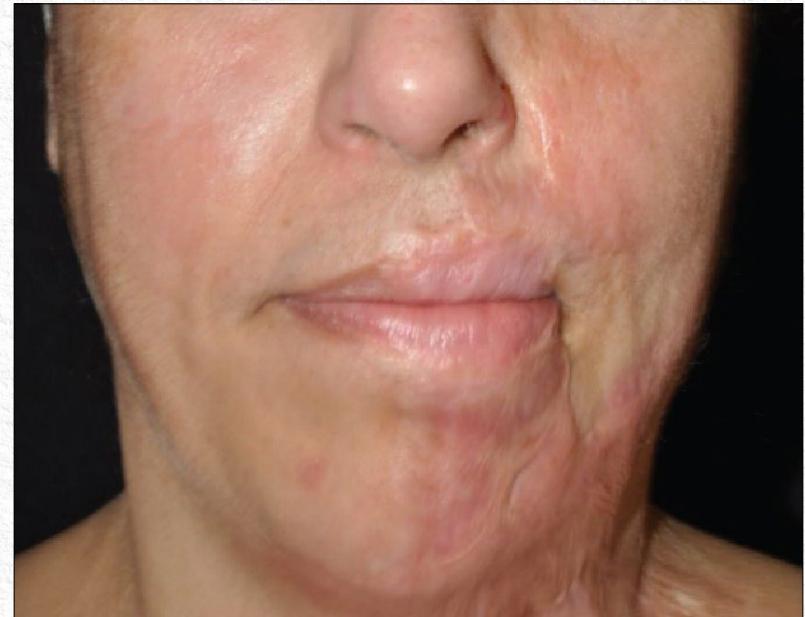

CLINICAL PHOTOS

# Burn Scar



**Before**



**After**

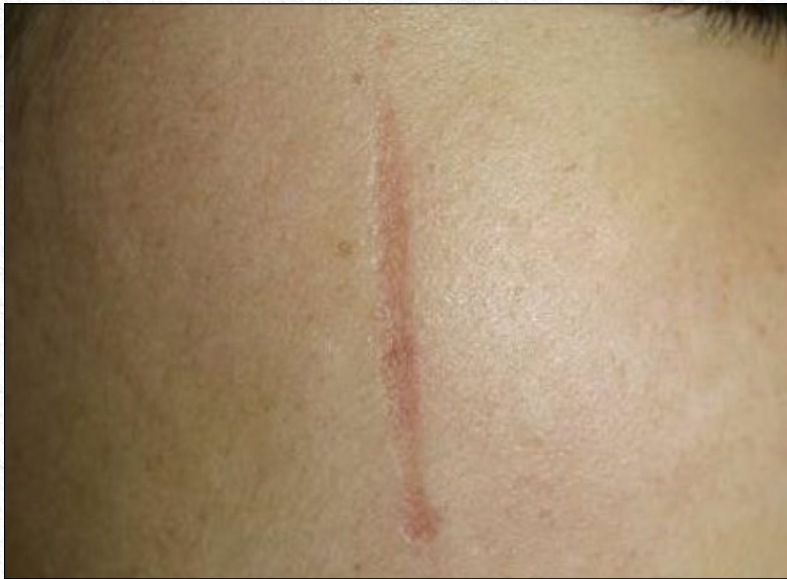*Courtesy of Jill Waibel, MD, USA*

*\* Results may vary by individuals.*

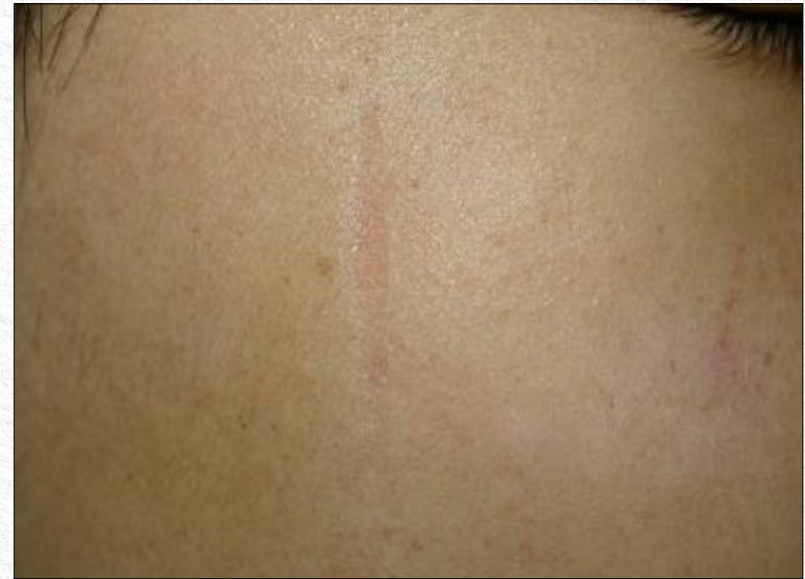

CLINICAL PHOTOS

# Atrophic Scar



**Before**



**After**

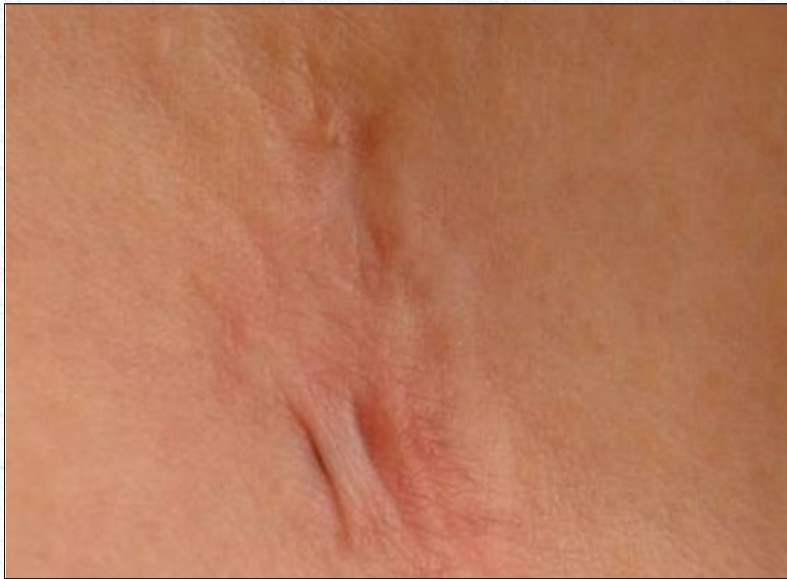*Courtesy of WS Kim, MD, South Korea*

*\* Results may vary by individuals.*

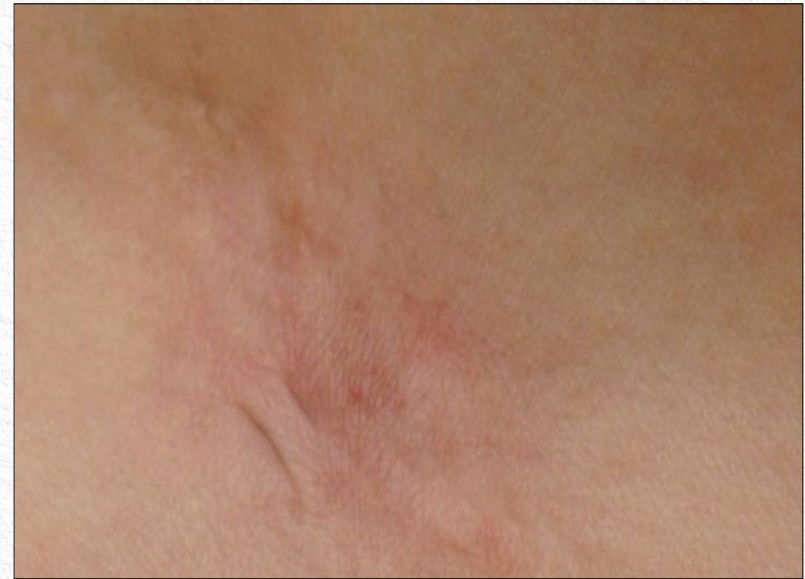

CLINICAL PHOTOS

# Atrophic Surgical Scar



**Before**



**After**

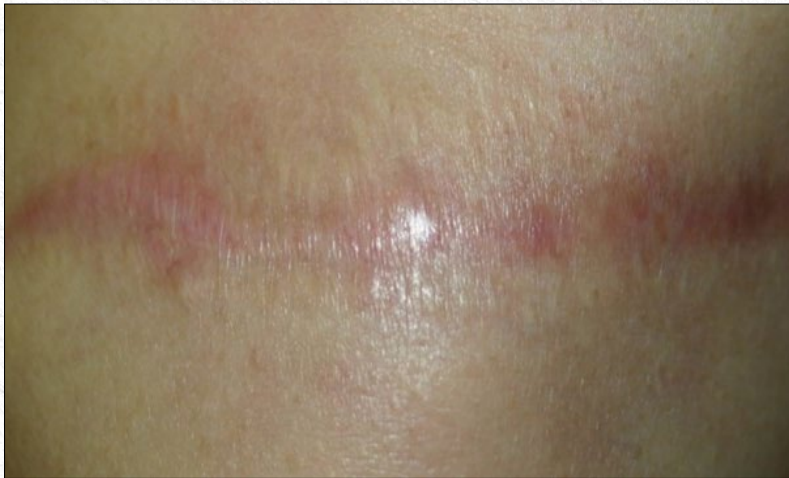*Courtesy of M Lee, MD, South Korea*

*\* Results may vary by individuals.*

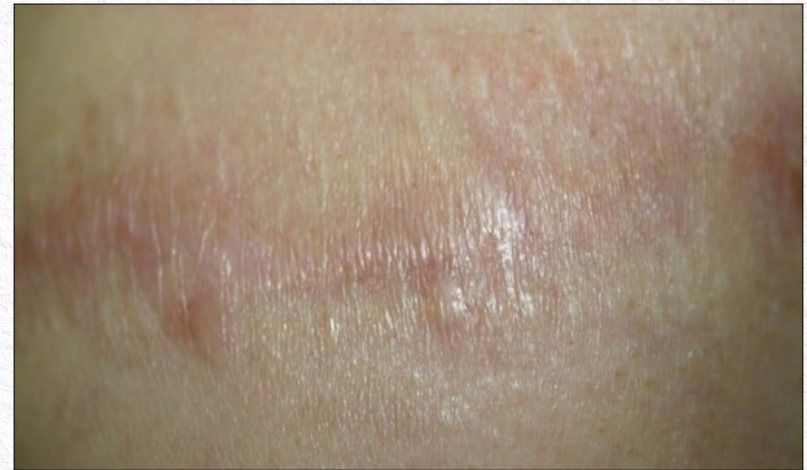

CLINICAL PHOTOS

# Hypertrophic Scar



**Before**



**After**

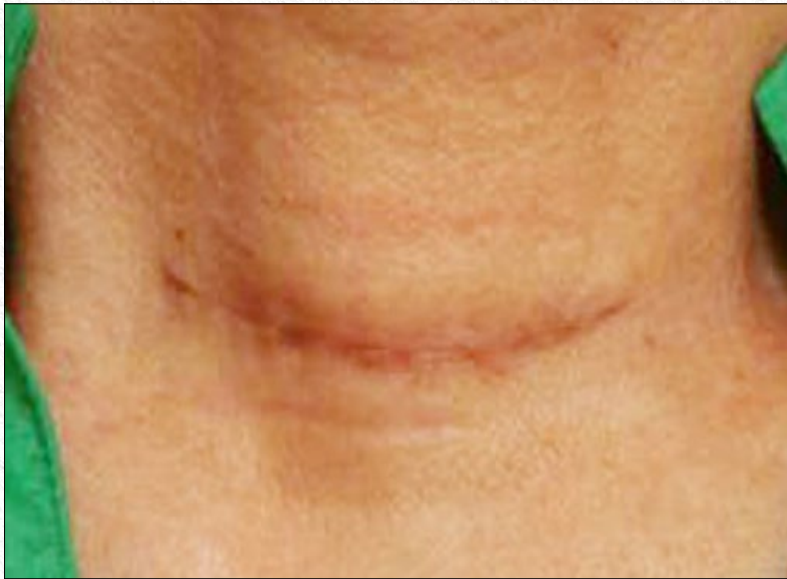*Courtesy of WS Kim, MD, South Korea*

*\* Results may vary by individuals.*

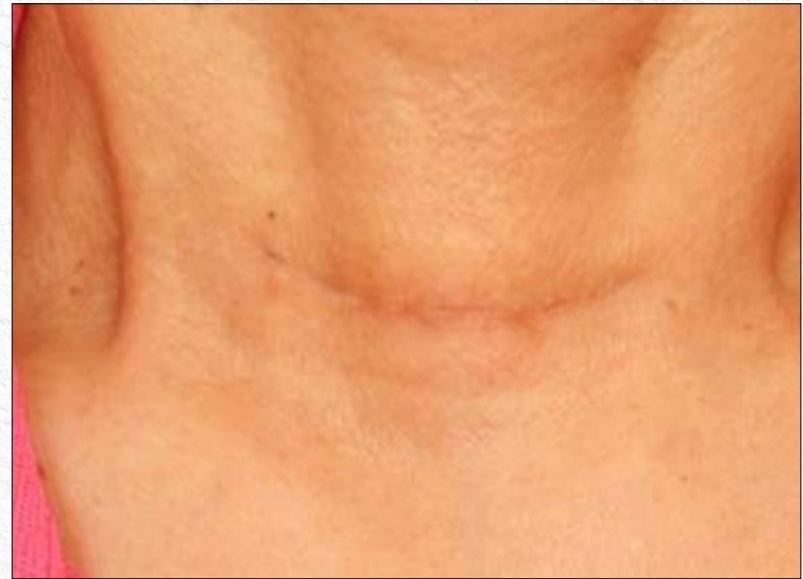


CLINICAL PHOTOS

# Surgical Scar Revision



**Before**



**After**

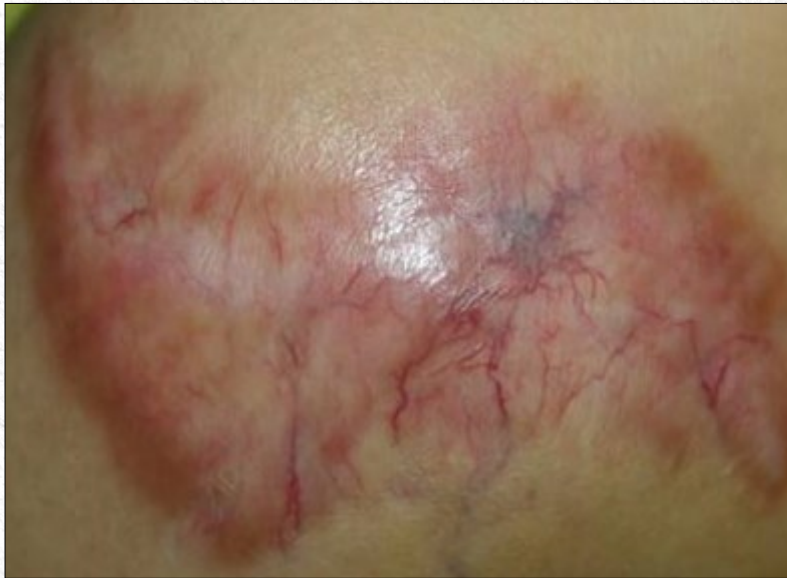*Courtesy of JY Jung, MD, South Korea*

*\* Results may vary by individuals.*

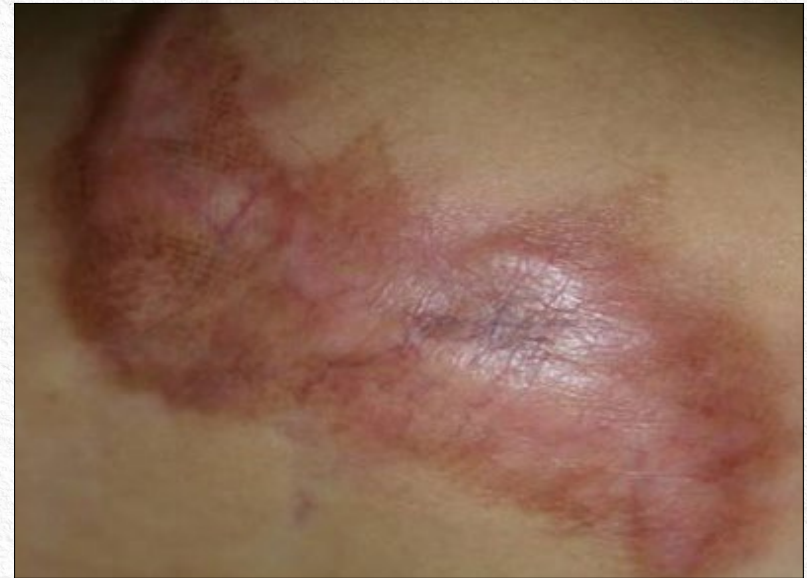

## CLINICAL PHOTOS

# Transdermal Drug Delivery with Bleomycin for Keloid Scar



**Before**



**After**

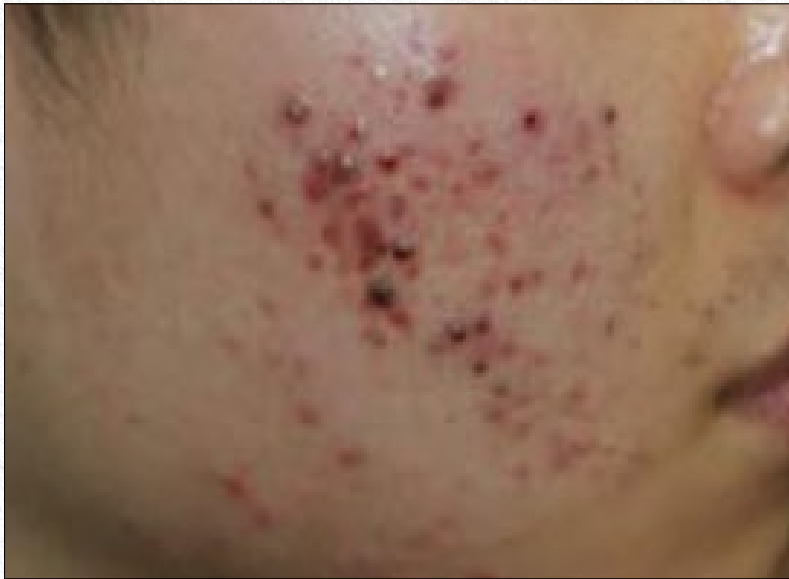*Courtesy of WS Kim, MD, South Korea*

*\* Results may vary by individuals.*

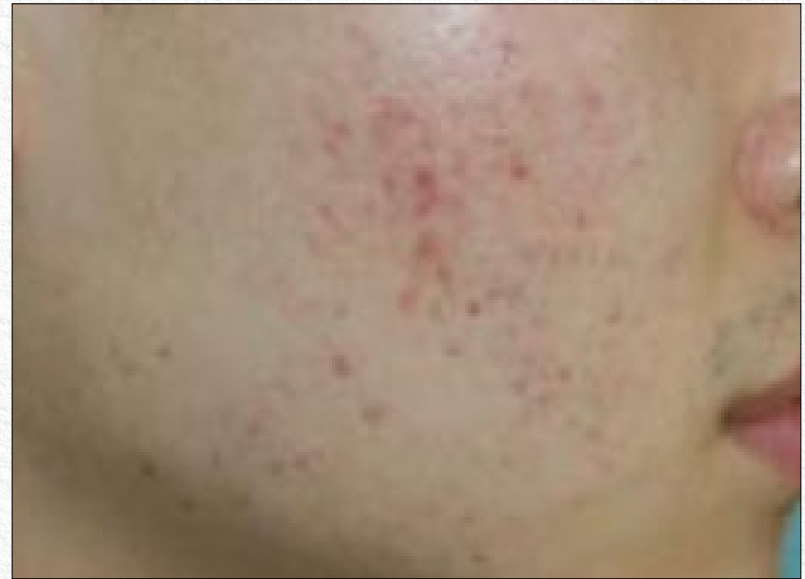

CLINICAL PHOTOS

# Moderate Pustular Acne Vulgaris



**Before**



**After**

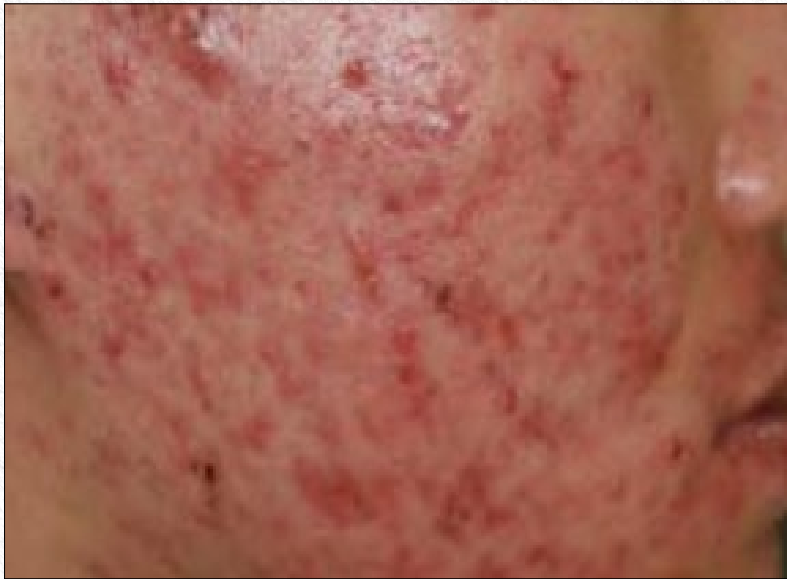*Courtesy of SB Cho, MD, South Korea*

*\* Results may vary by individuals.*

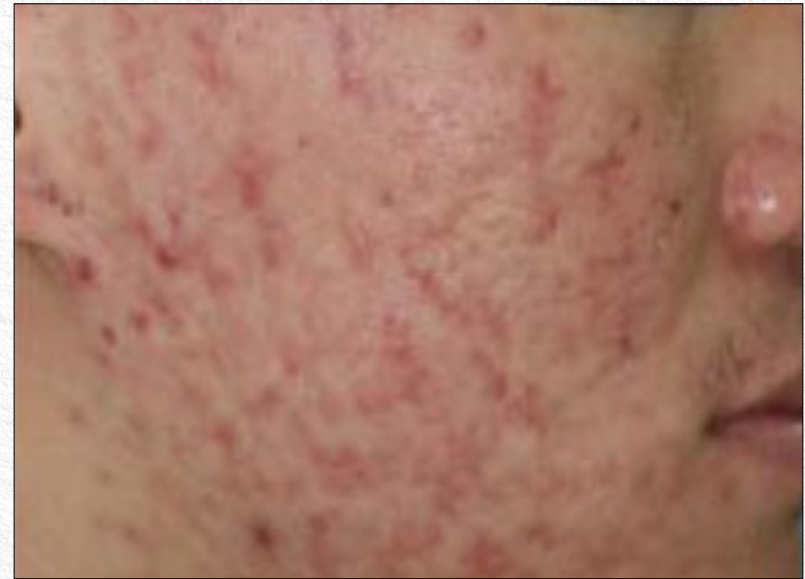

CLINICAL PHOTOS

# Severe Pustular Acne Vulgaris



**Before**



**After**

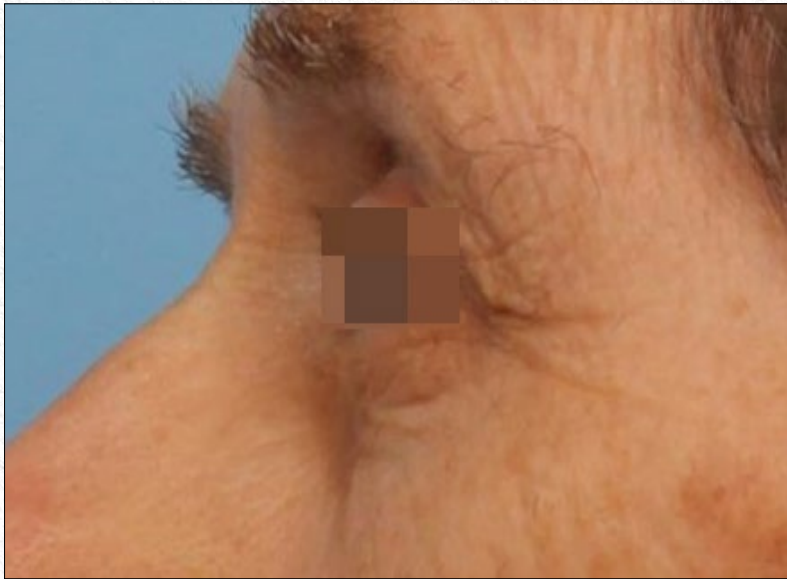*Courtesy of SB Cho, MD, South Korea*

*\* Results may vary by individuals.*

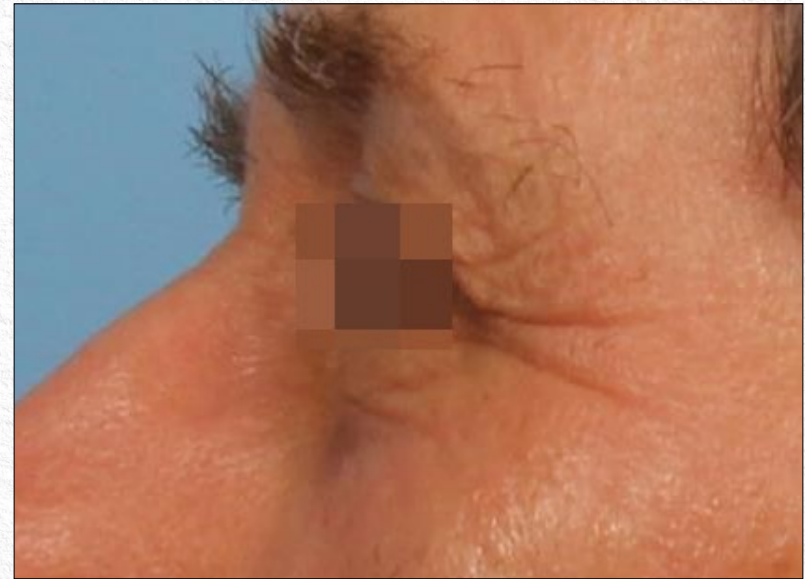


CLINICAL PHOTOS

# Wrinkles & Pigment



**Before**



**After**

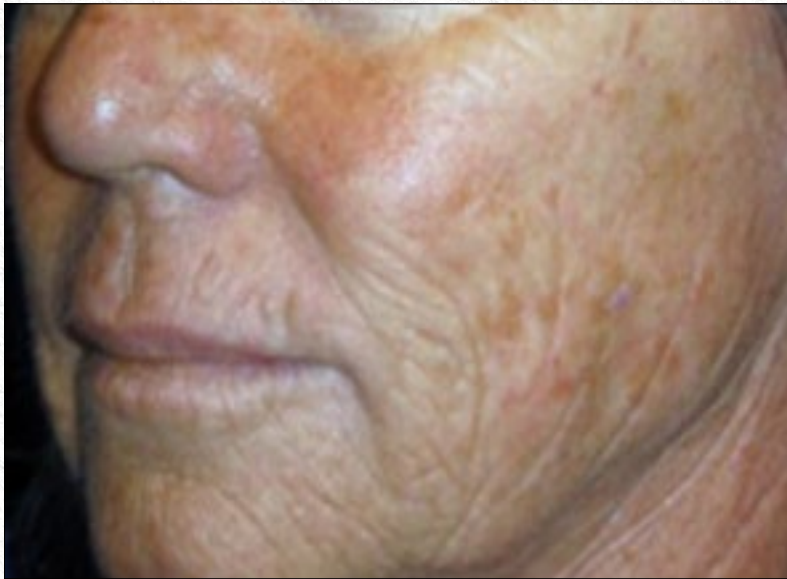*Courtesy of Melanie Palm, MD, USA*

*\* Results may vary by individuals.*

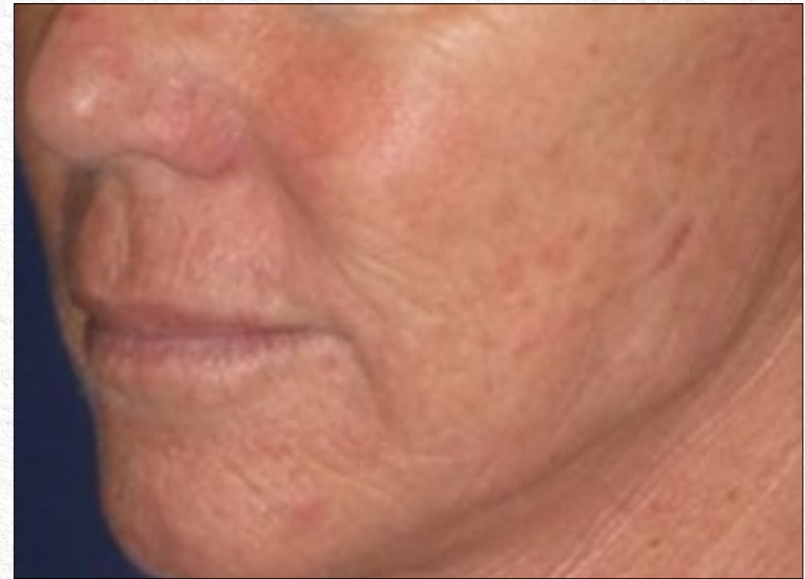

CLINICAL PHOTOS

# Wrinkles & Pigment



**Before**



**After**

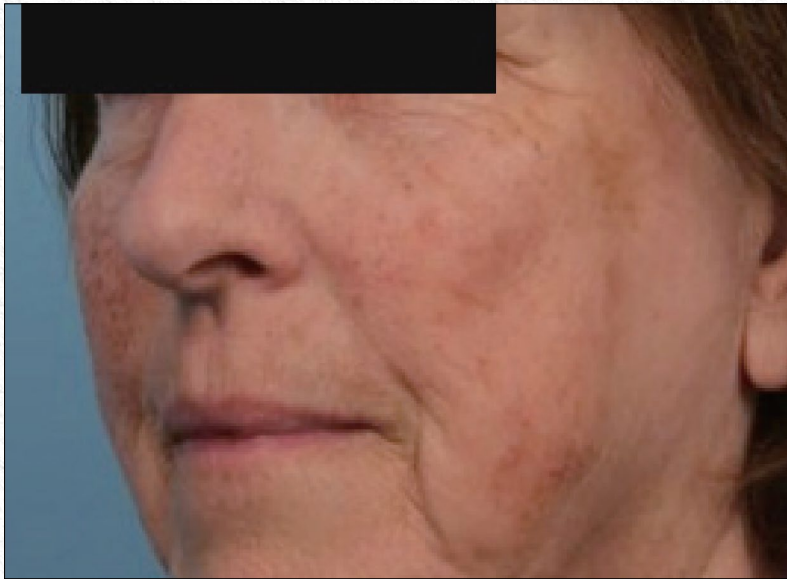*Courtesy of Farhan Taghizadeh, MD, USA*

*\* Results may vary by individuals.*

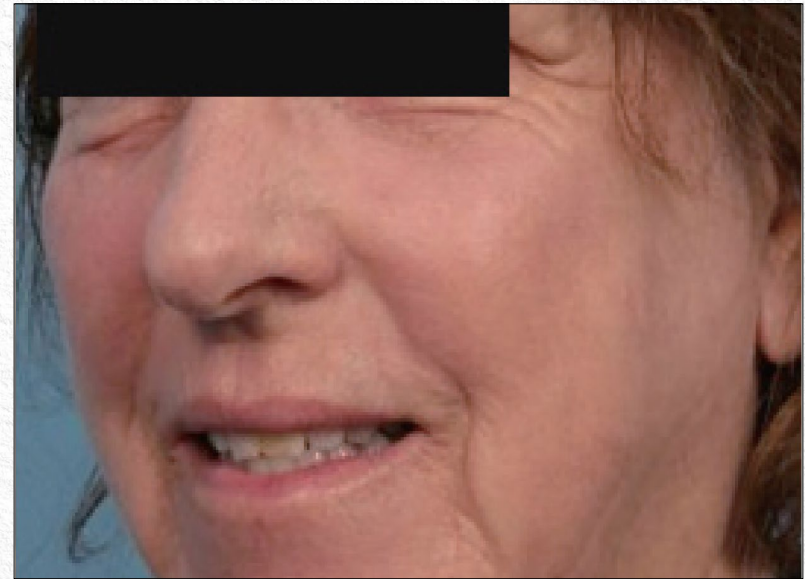

CLINICAL PHOTOS

# Wrinkles & Pigment



**Before**



**After**

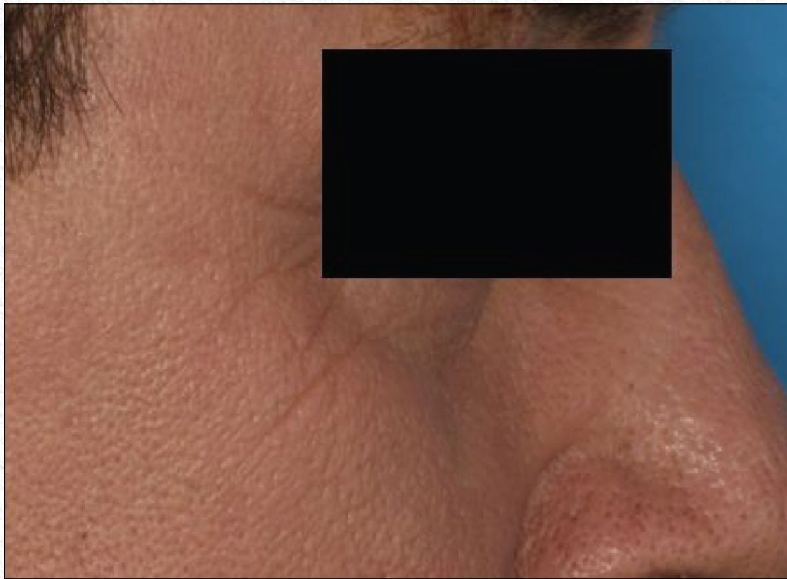*Courtesy of Melanie Palm, MD, USA*

*\* Results may vary by individuals.*

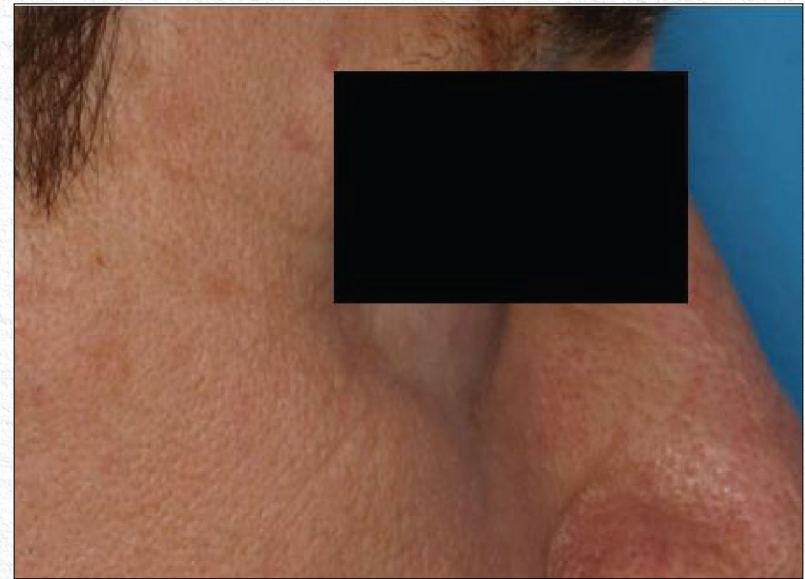

CLINICAL PHOTOS

# Wrinkles



**Before**



**After**

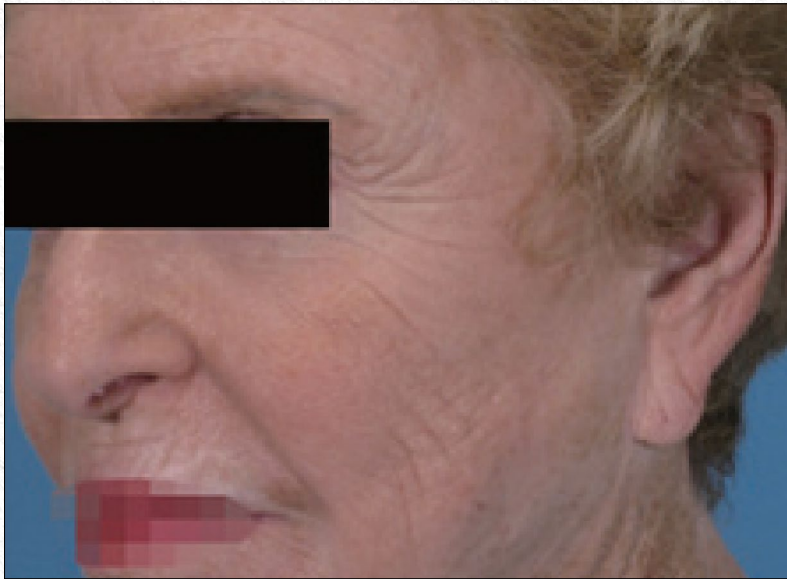*Courtesy of JD Holcomb, MD, USA*

*\* Results may vary by individuals.*

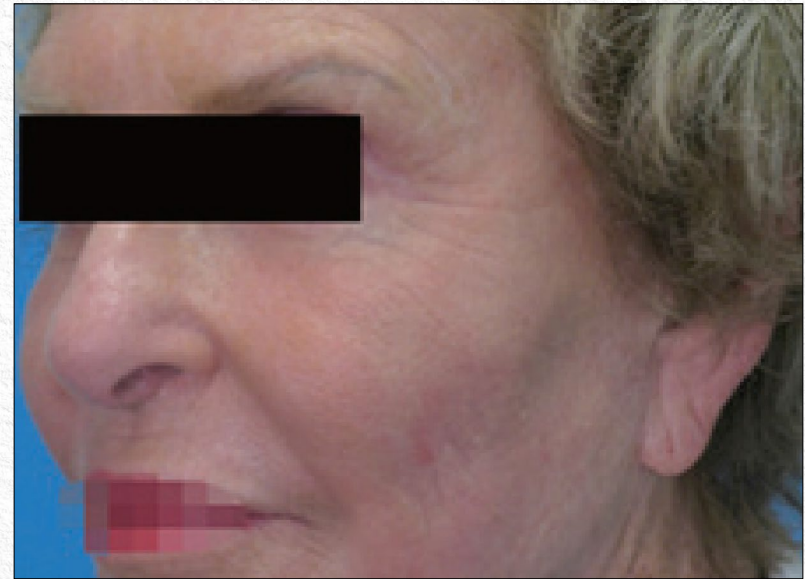

## CLINICAL PHOTOS

# Wrinkles



**Before**



**After**

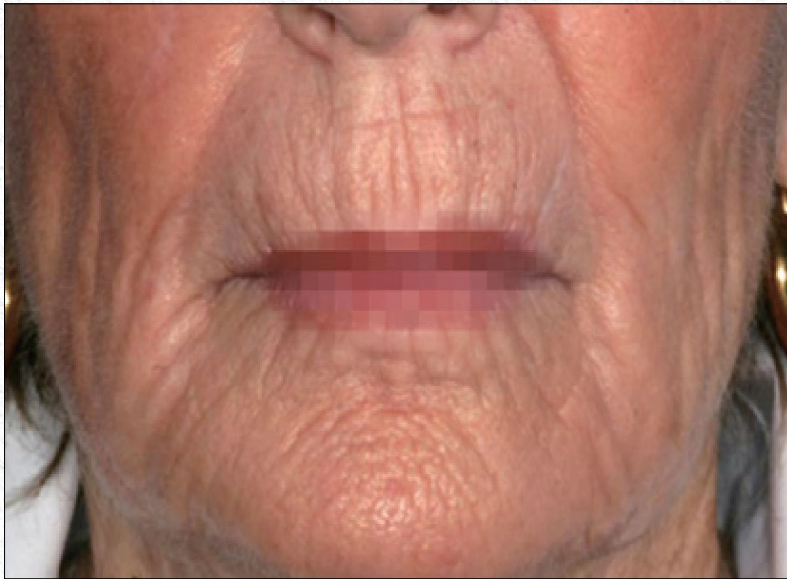*Courtesy of Daniel Man, MD, USA*

*\* Results may vary by individuals.*

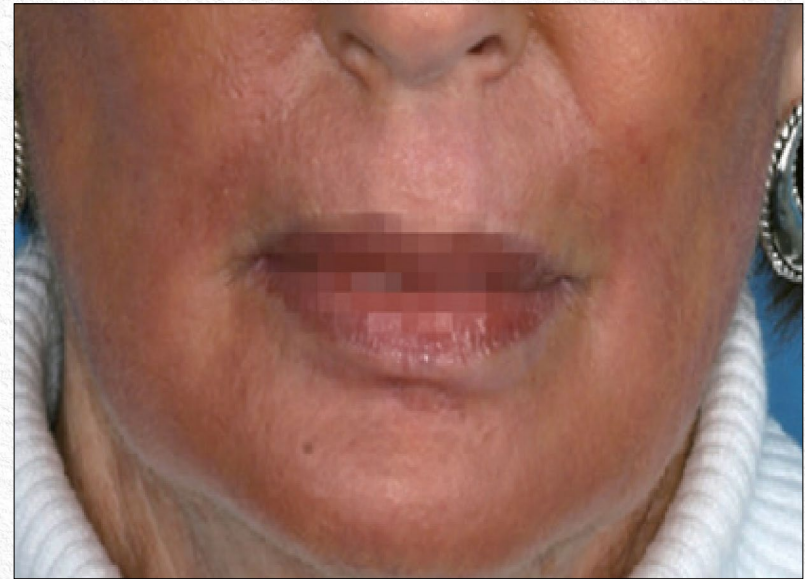

CLINICAL PHOTOS

# Perioral Wrinkles



**Before**



**After**

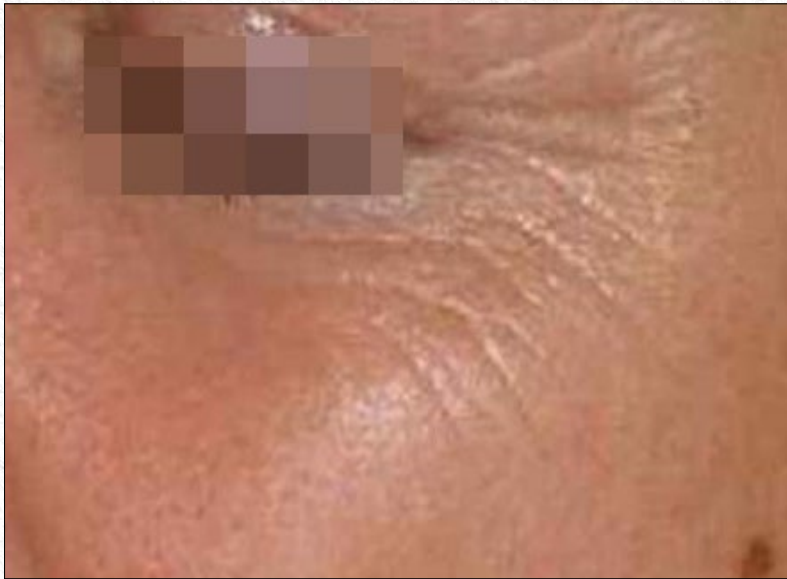*Courtesy of David Holcomb, MD, USA*

*\* Results may vary by individuals.*

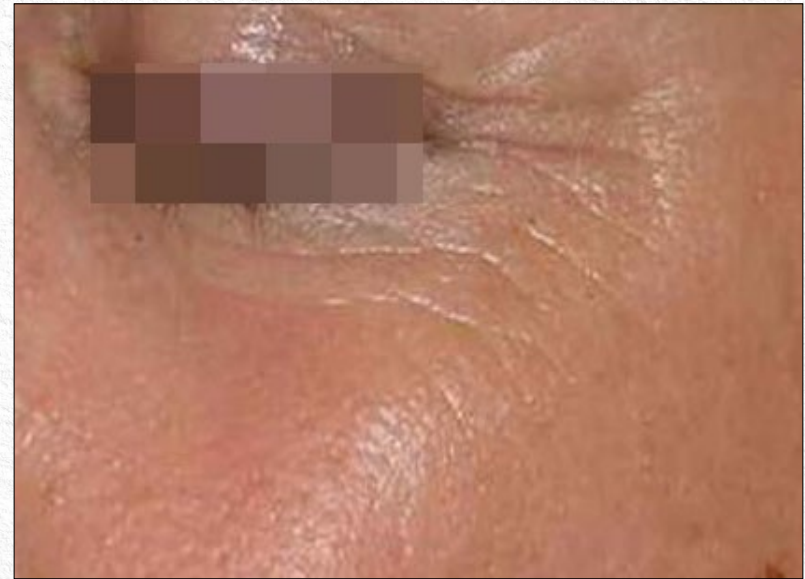

CLINICAL PHOTOS

# Periorbital Wrinkles



**Before**



**After**

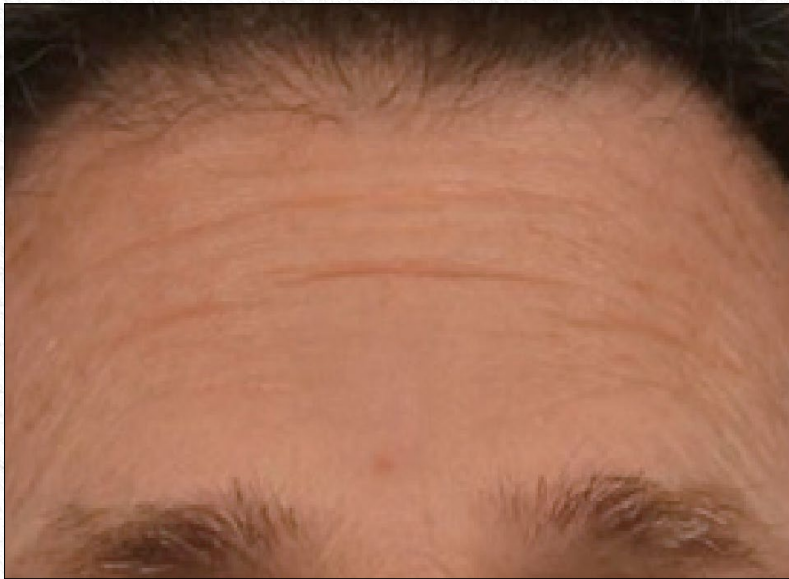*Courtesy of MG Rubin, MD, USA*

*\* Results may vary by individuals.*

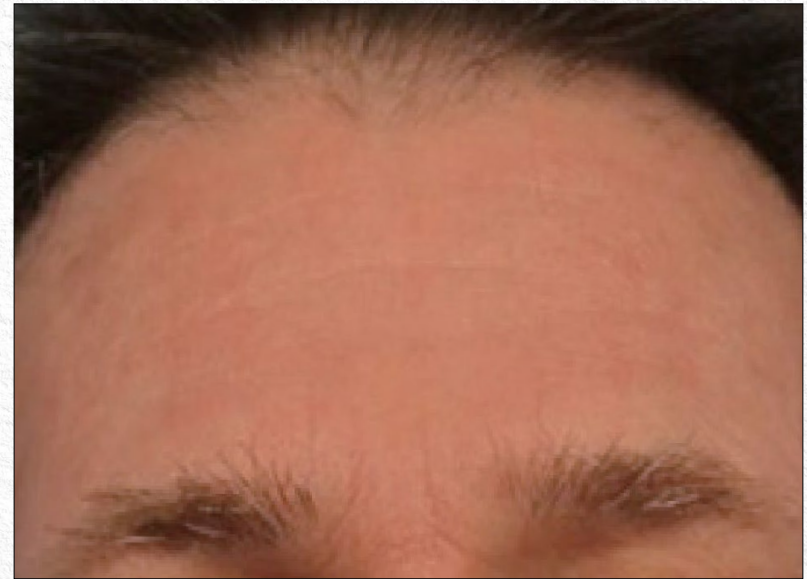

CLINICAL PHOTOS

# Deep Wrinkles



**Before**



**After**

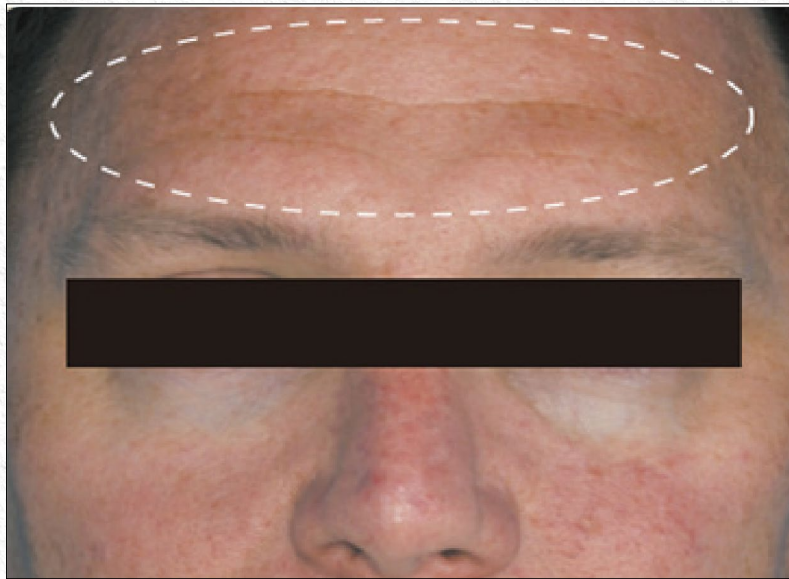*Courtesy of Melanie Palm, MD, USA*

*\* Results may vary by individuals.*

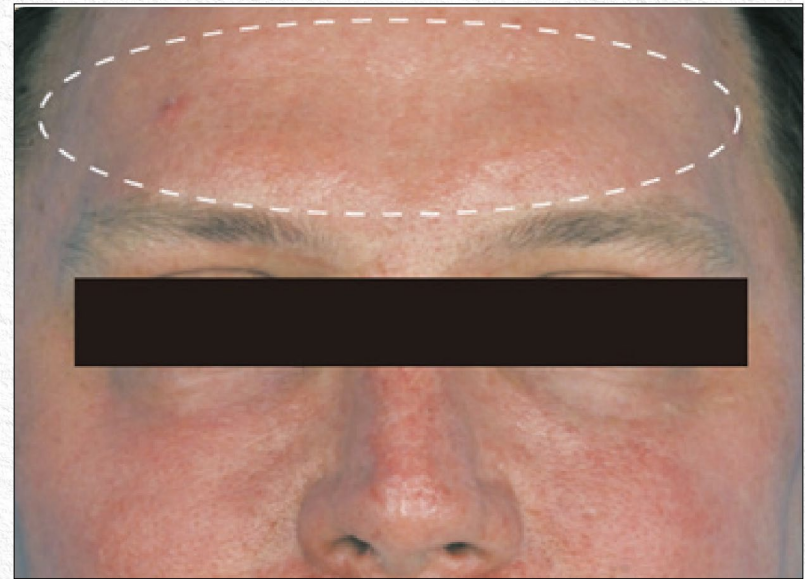

CLINICAL PHOTOS

# Deep Wrinkles



**Before**



**After**

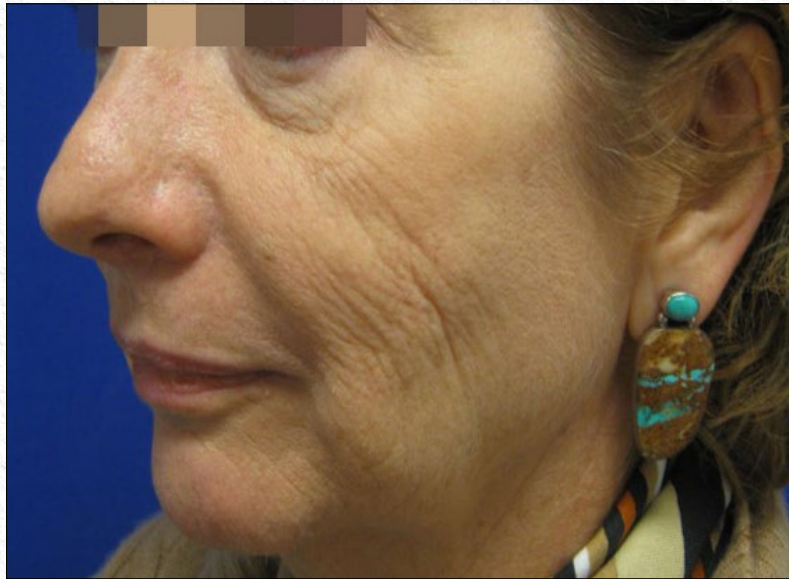*Courtesy of David Holcomb, MD, USA*

*\* Results may vary by individuals.*

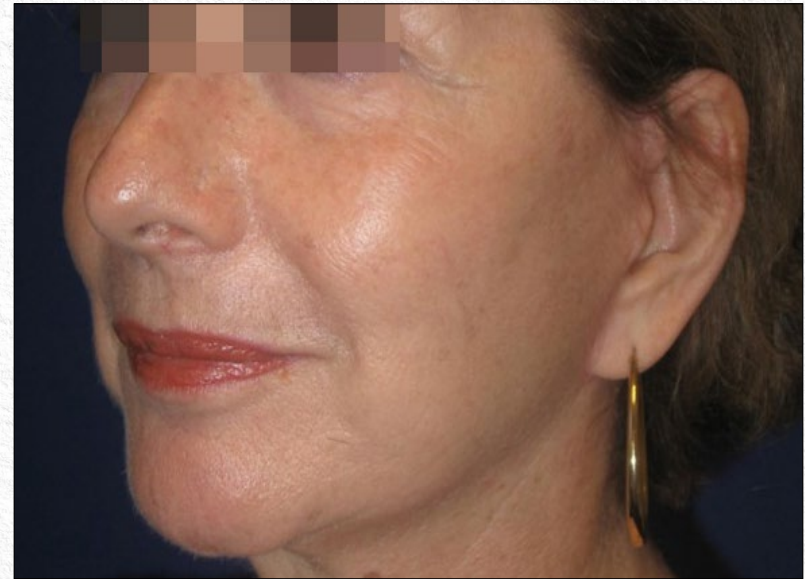

CLINICAL PHOTOS

## Wrinkles & Texture (Combined with Facelift)



Before



After

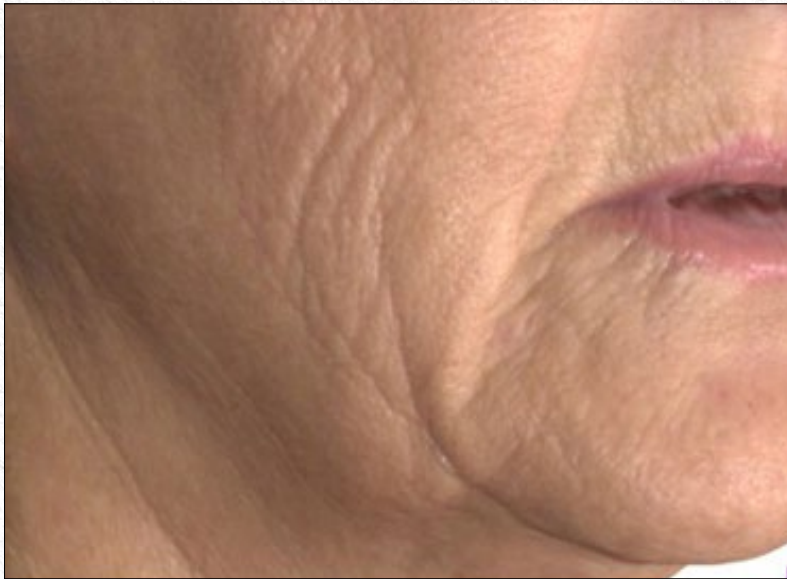*Courtesy of Farhan Taghizadeh, MD, USA*

*\* Results may vary by individuals.*

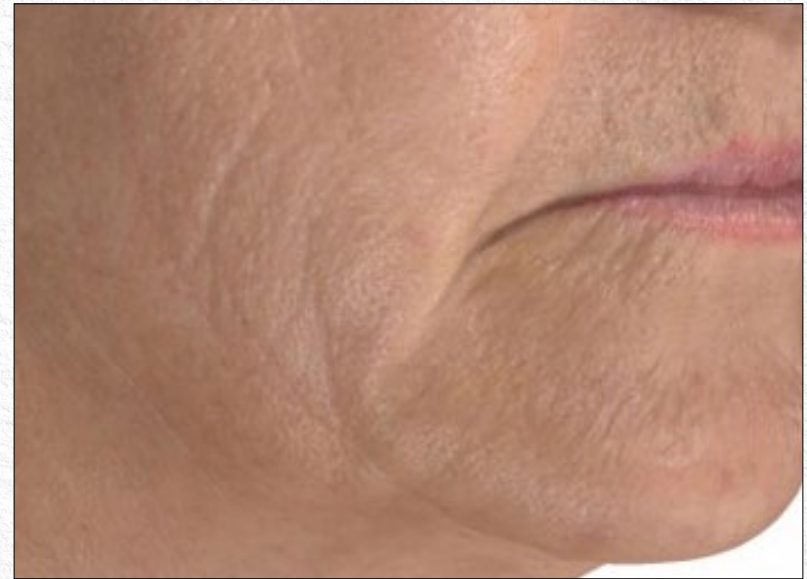

CLINICAL PHOTOS

## Wrinkles & Texture (Combined with Facelift)



**Before**



**After**

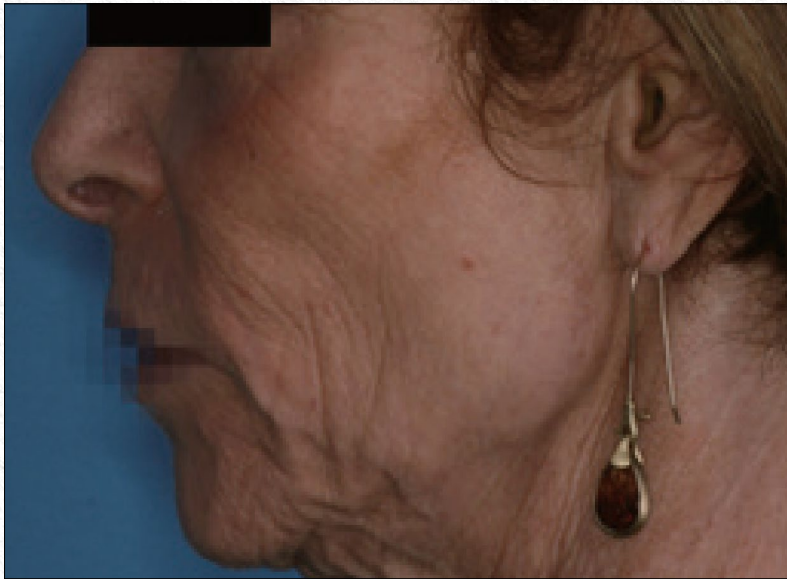*Courtesy of Farhan Taghizadeh, MD, USA*

*\* Results may vary by individuals.*

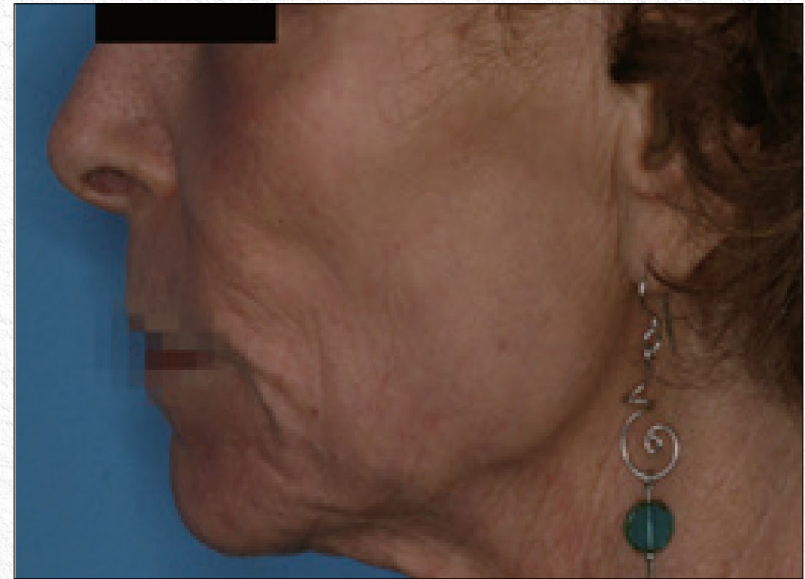

CLINICAL PHOTOS

# Skin Laxity



**Before**



**After**

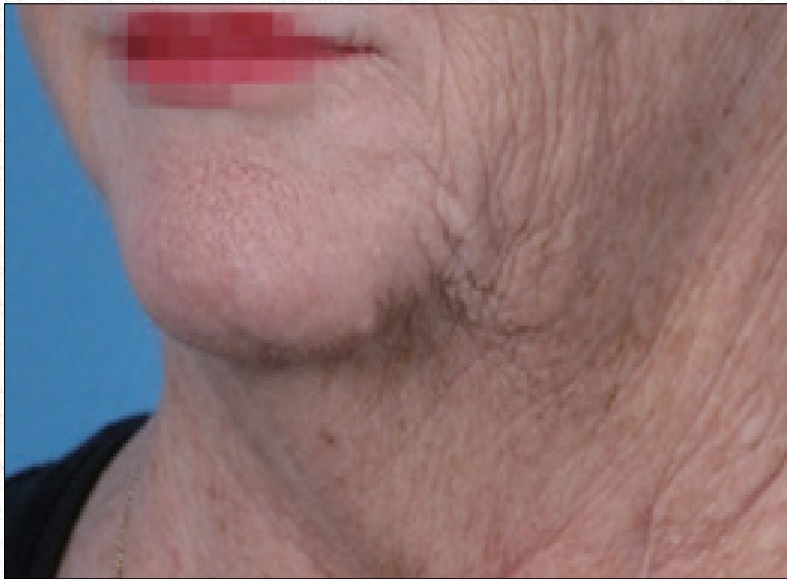*Courtesy of David Holcomb, MD, USA*

*\* Results may vary by individuals.*

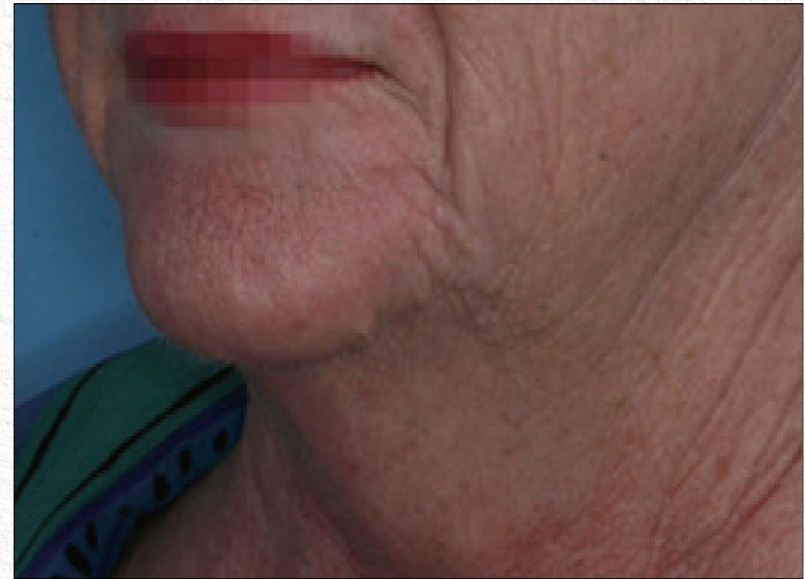

CLINICAL PHOTOS

# Skin Laxity



**Before**



**After**

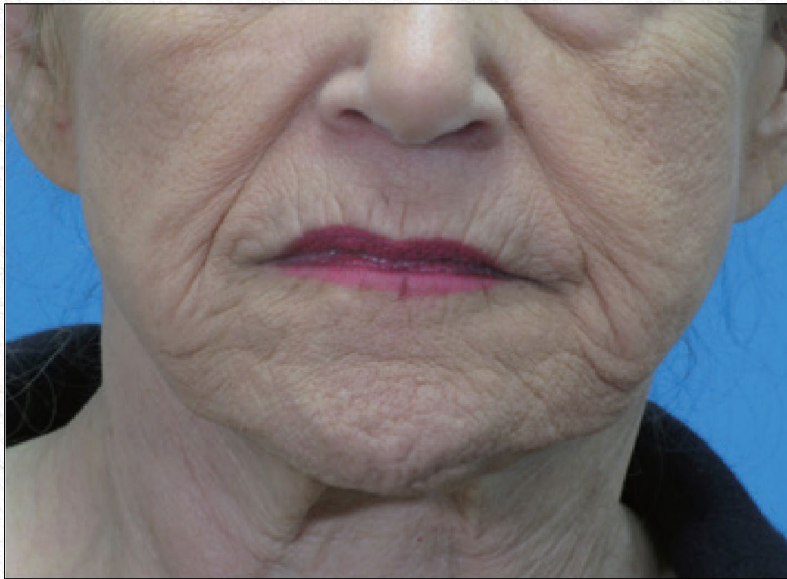*Courtesy of David Holcomb, MD, USA*

*\* Results may vary by individuals.*

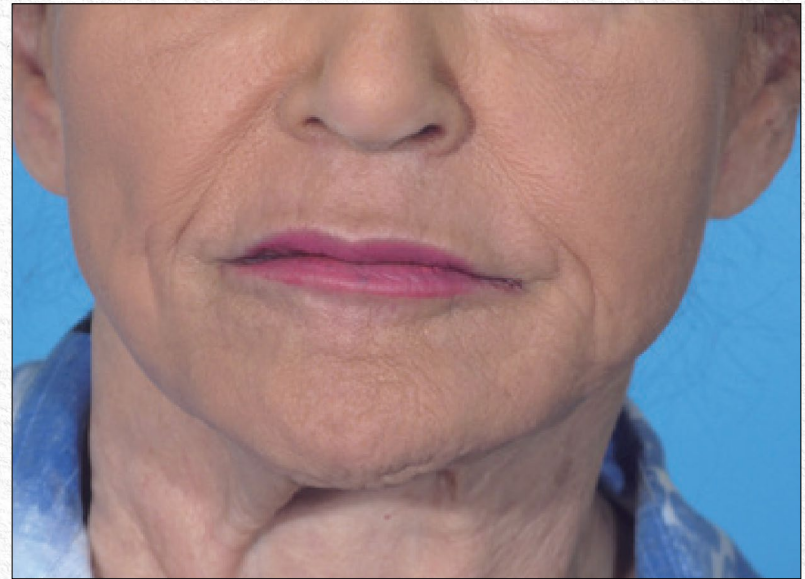

CLINICAL PHOTOS

# Skin Laxity



**Before**



**After**

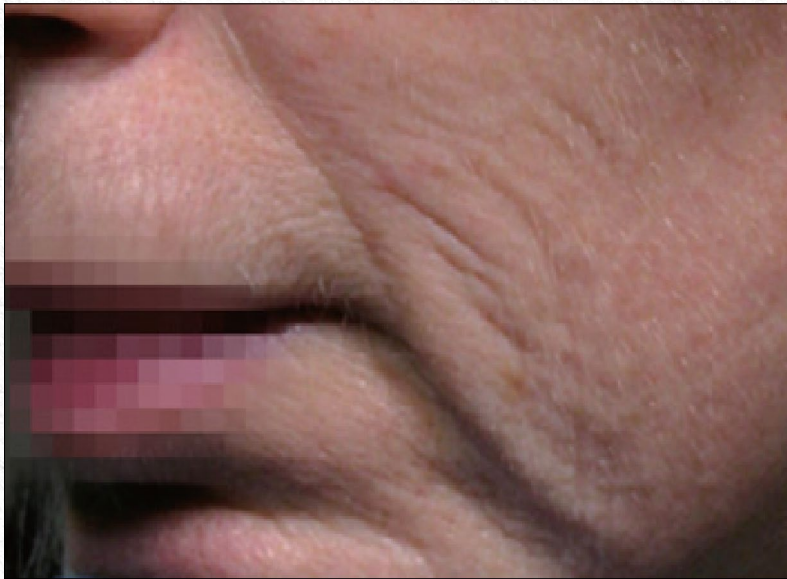
*Courtesy of Daniel Man, MD, USA*

*\* Results may vary by individuals.*

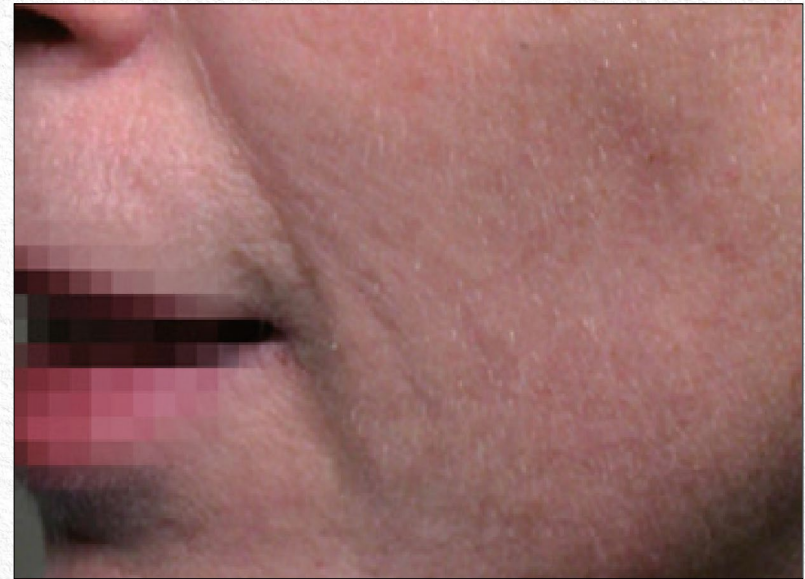

CLINICAL PHOTOS

# Skin Laxity



**Before**



**After**

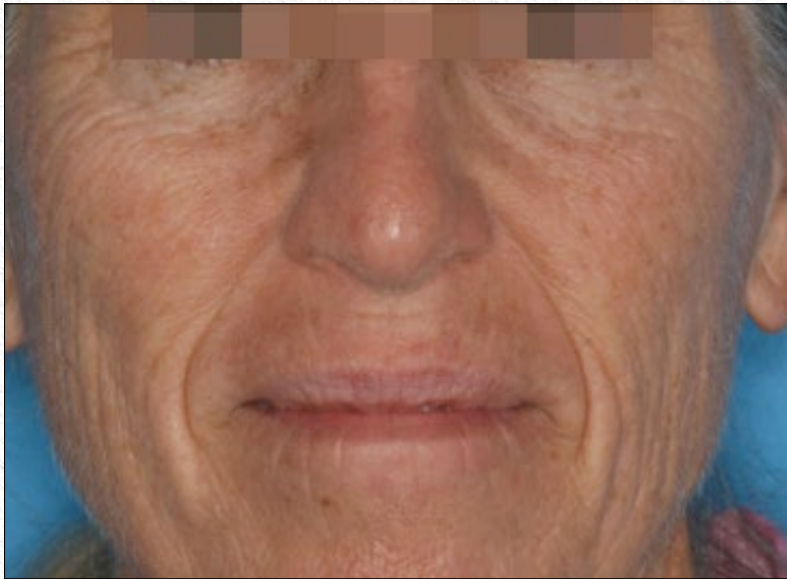*Courtesy of Jeffrey Rapaport, MD, USA*

*\* Results may vary by individuals.*

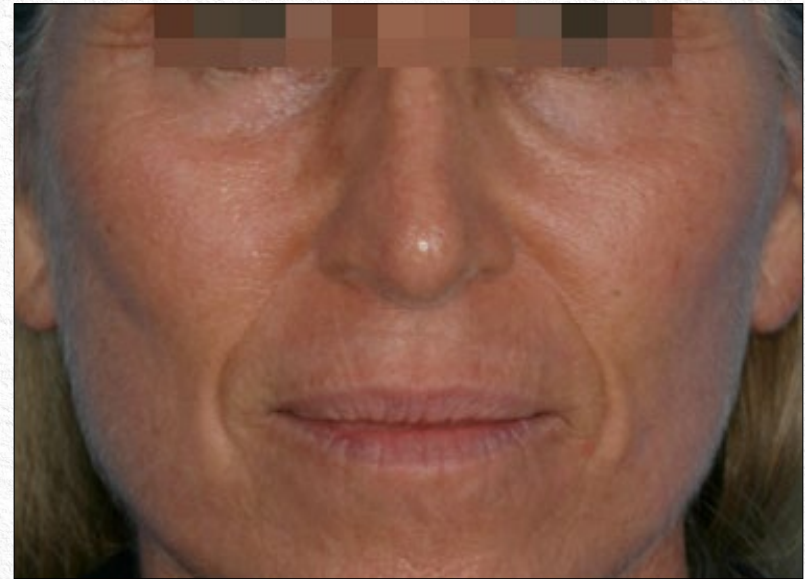

CLINICAL PHOTOS

# Skin Laxity



**Before**



**After**

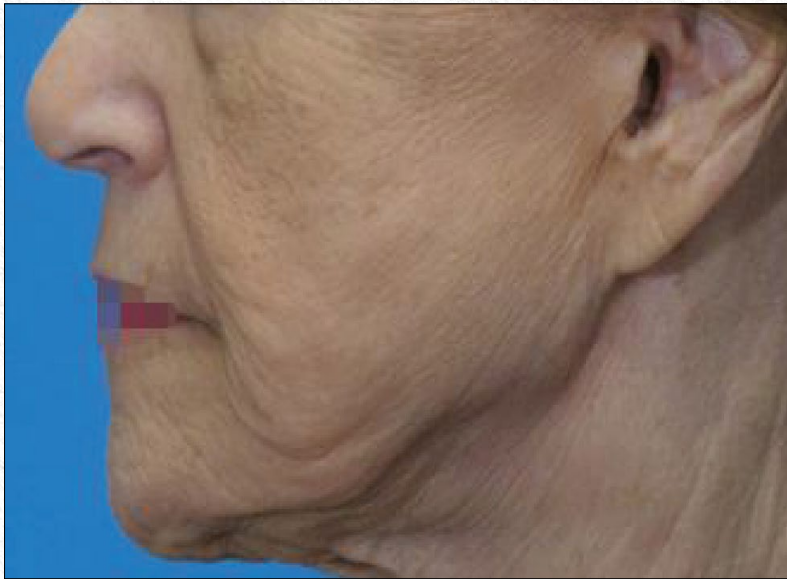
*Courtesy of JD Holcomb, MD, USA*

*\* Results may vary by individuals.*

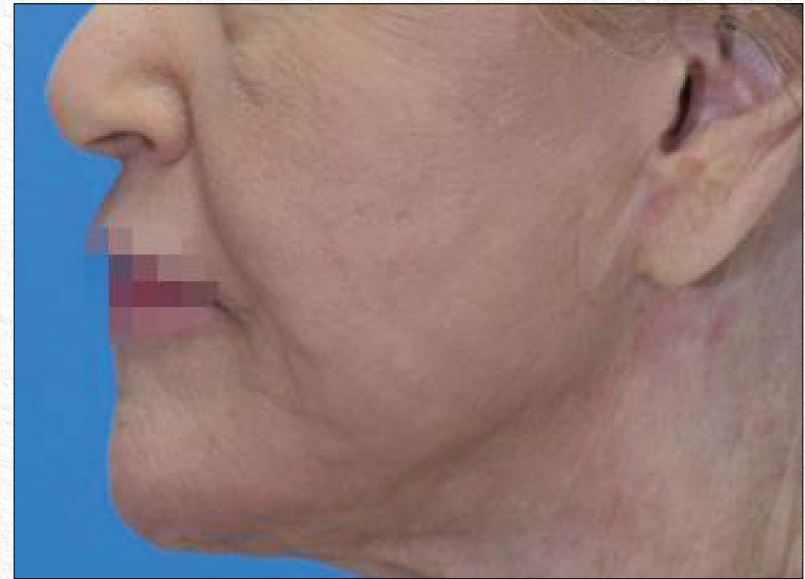

CLINICAL PHOTOS

# Skin Laxity



**Before**



**After**

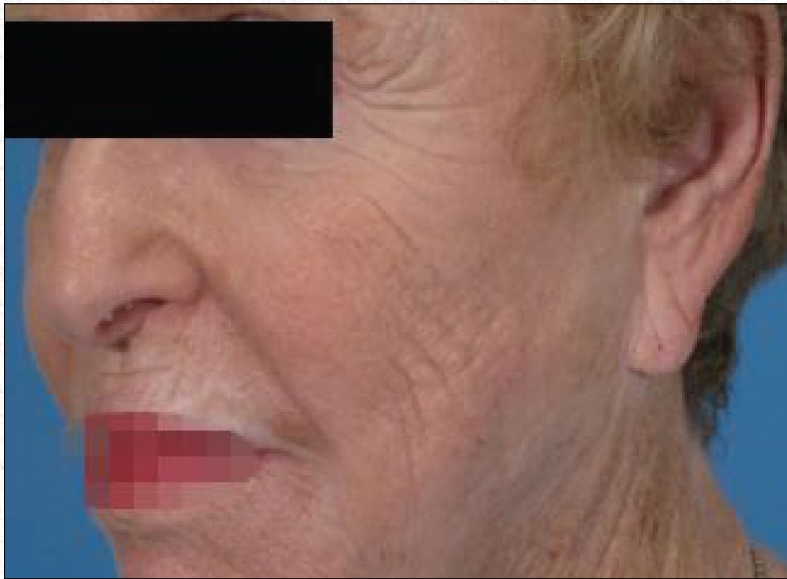*Courtesy of D Man, MD, USA*

*\* Results may vary by individuals.*

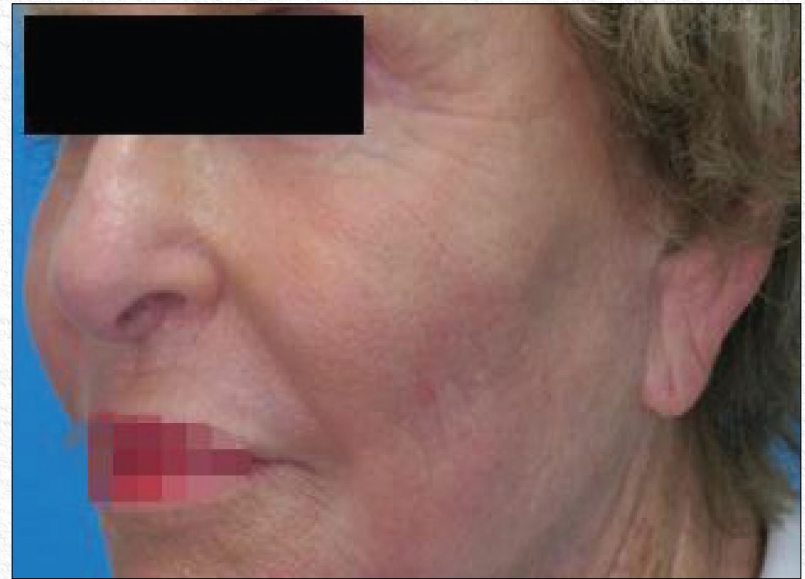

CLINICAL PHOTOS

# Skin Laxity



**Before**



**After**

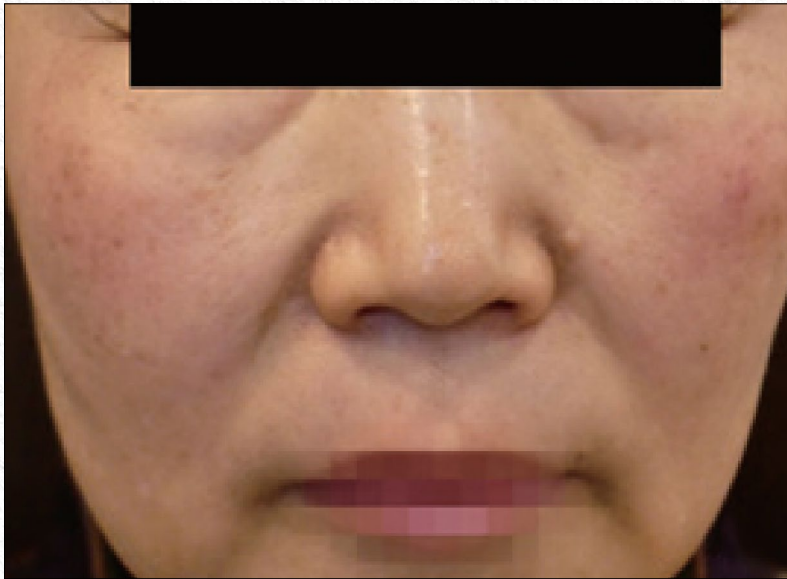
*Courtesy of D Man, MD, USA*

*\* Results may vary by individuals.*

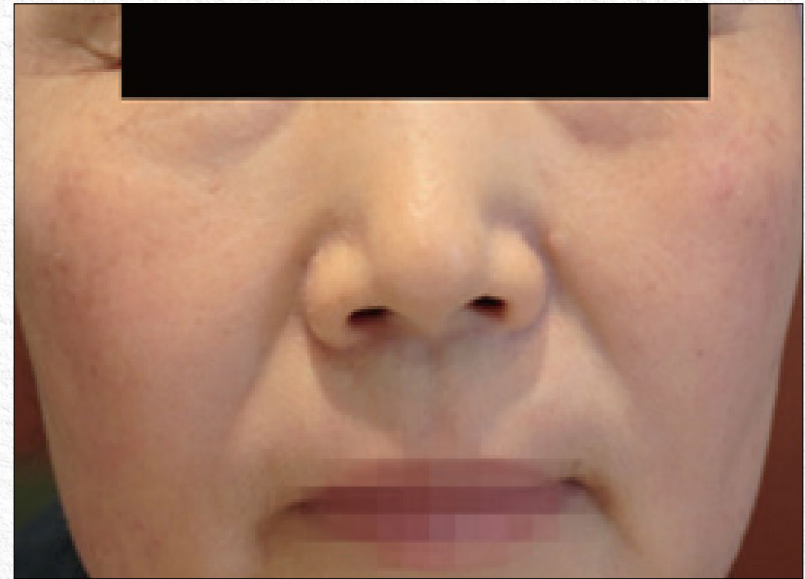

CLINICAL PHOTOS

# Skin Rejuvenation



**Before**



**After**

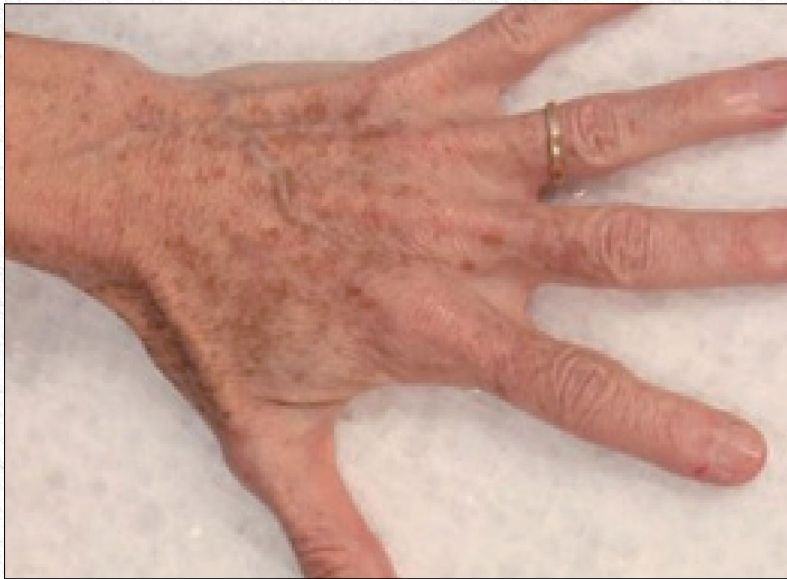*Courtesy of KT Hong, MD, South Korea*

*\* Results may vary by individuals.*

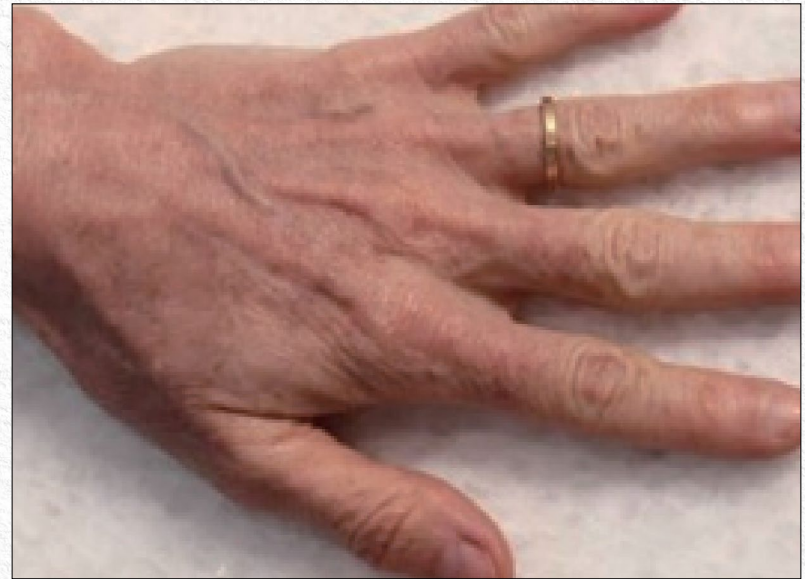

CLINICAL PHOTOS

# Photoaging



**Before**



**After**

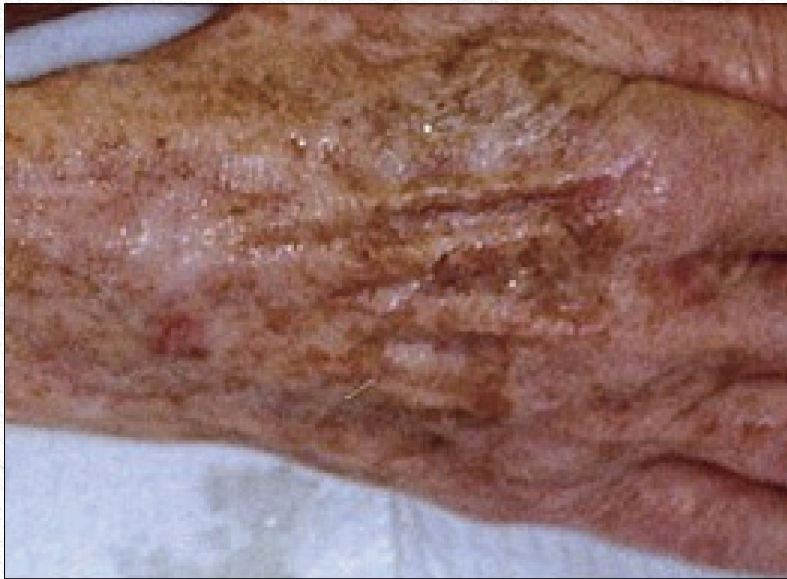*Courtesy of Melanie Palm, MD, USA*

*\* Results may vary by individuals.*

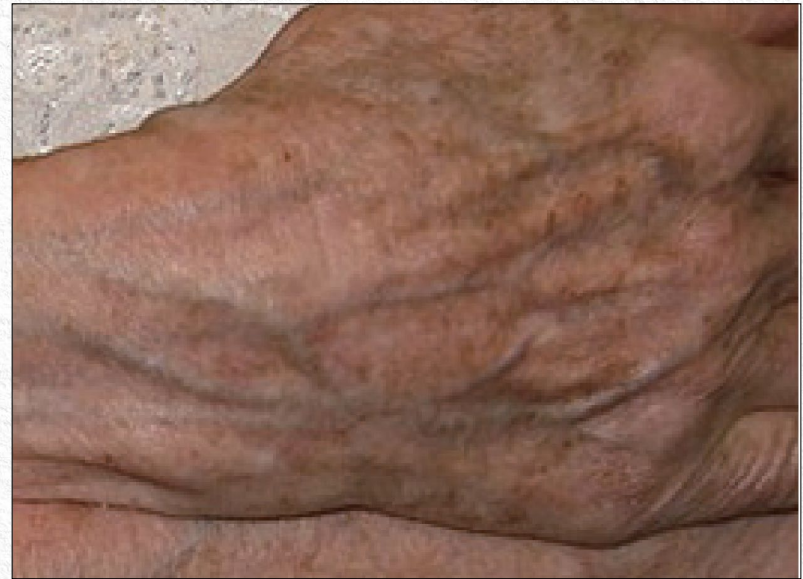

CLINICAL PHOTOS

# Photoaging



**Before**



**After**

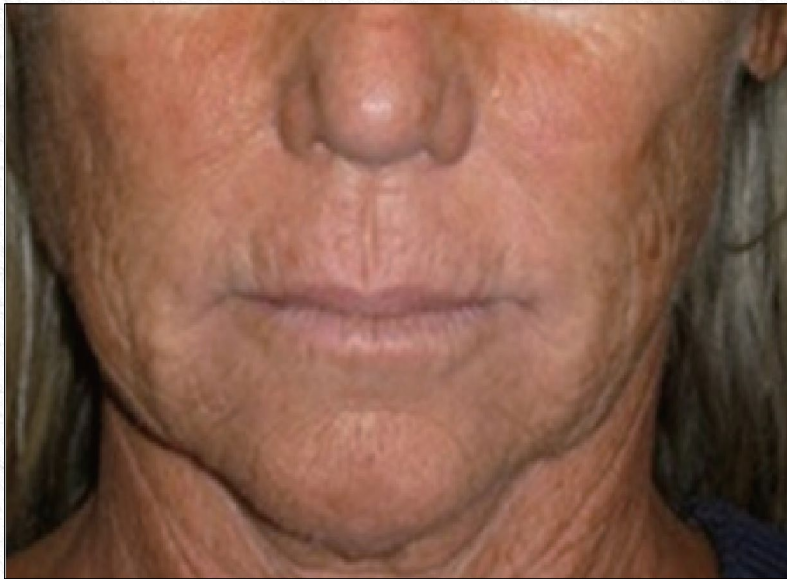*Courtesy of Mark Rubin, MD, USA*

*\* Results may vary by individuals.*

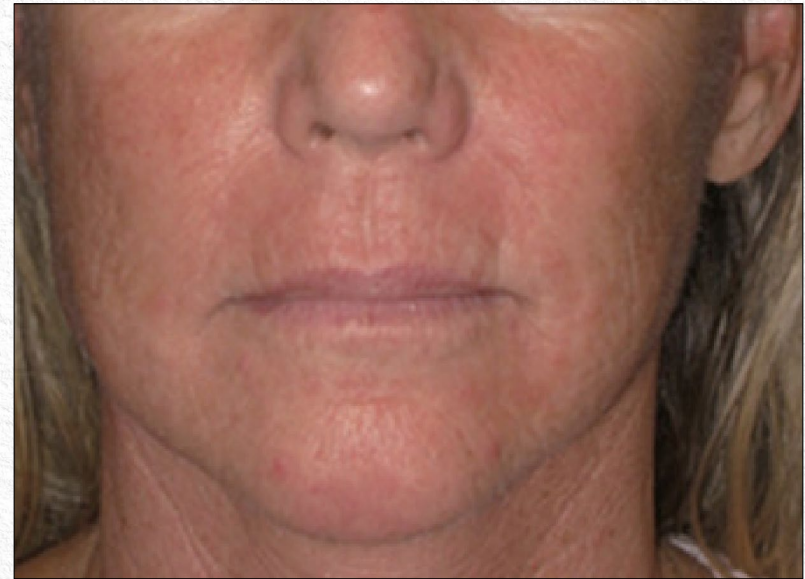

CLINICAL PHOTOS

# Pigmentation



**Before**



**After**

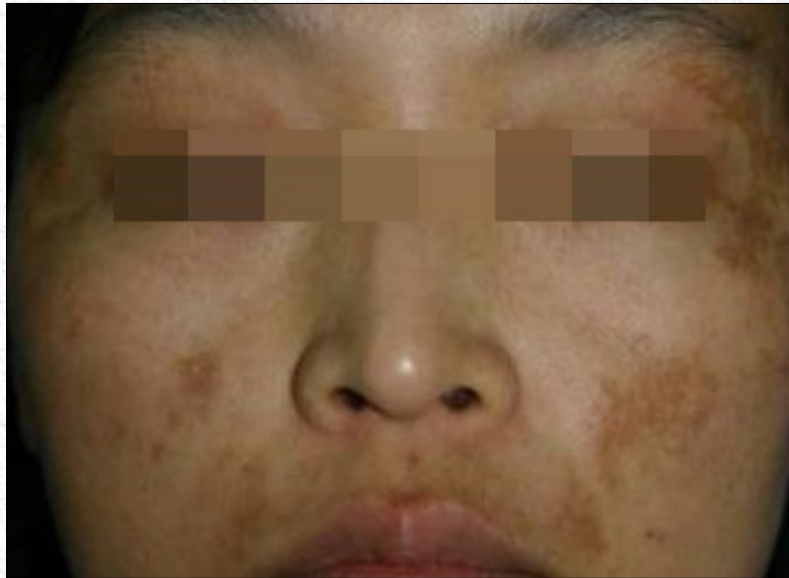*Courtesy of Farhan Taghizadeh, MD, USA*

*\* Results may vary by individuals.*

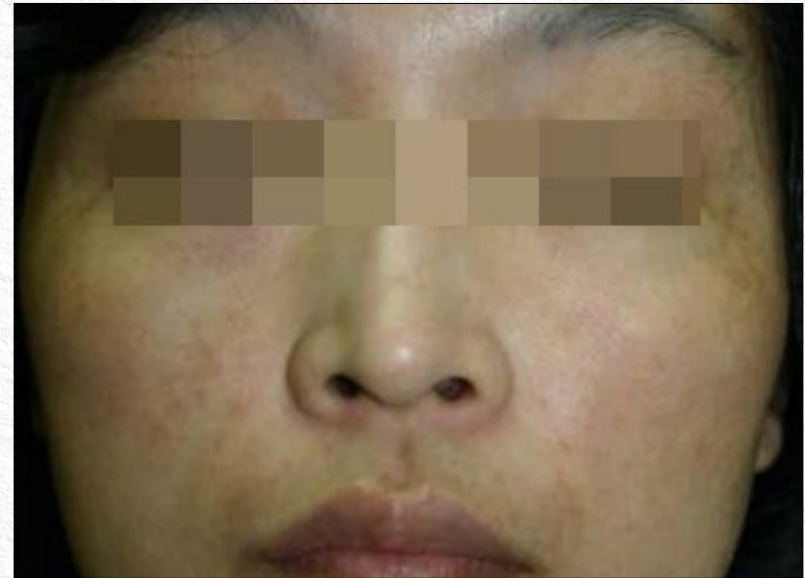

CLINICAL PHOTOS

# Transdermal Drug Delivery with Biocell Cytokines for Whitening



Before



After

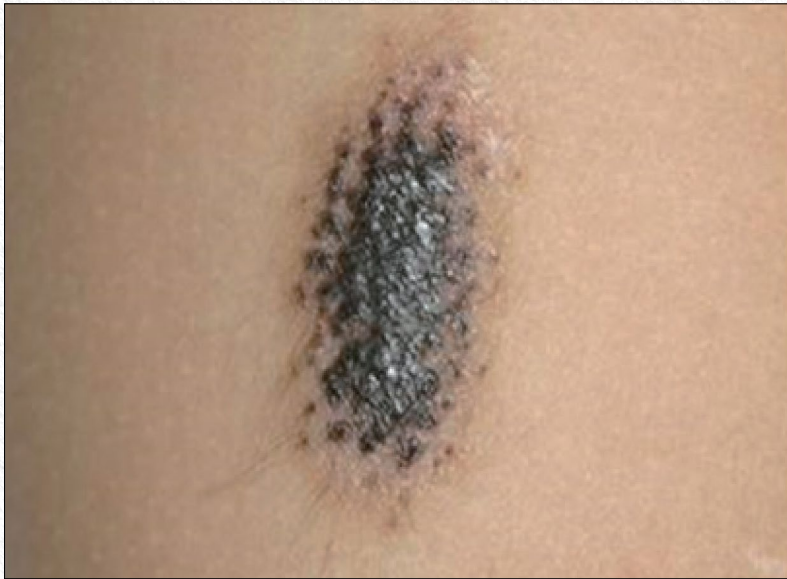*Courtesy of SI Chun, MD, Korea*

*\* Results may vary by individuals.*

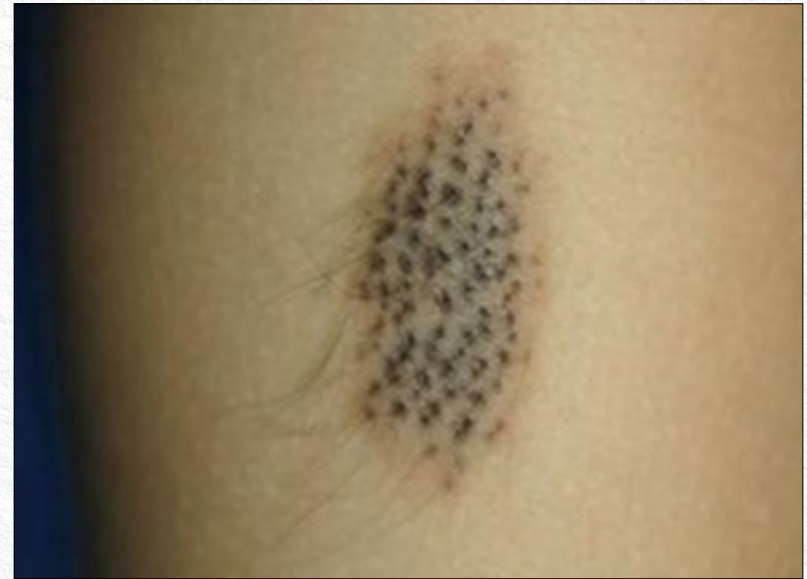

CLINICAL PHOTOS

## Congenital Melanocytic Nevus (eCO2 + TCA)



**Before**



**After**

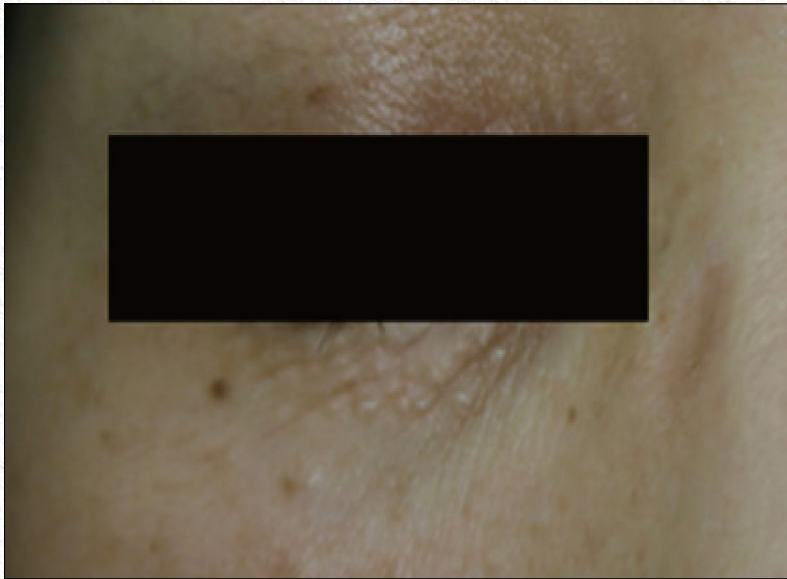
*Courtesy of WS Kim, MD, South Korea*

*\* Results may vary by individuals.*

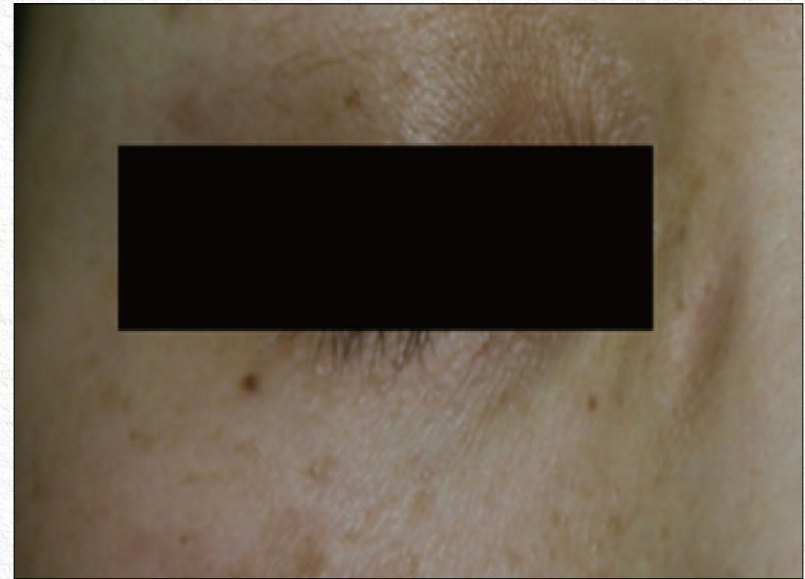


CLINICAL PHOTOS

# Syringoma



**Before**



**After**

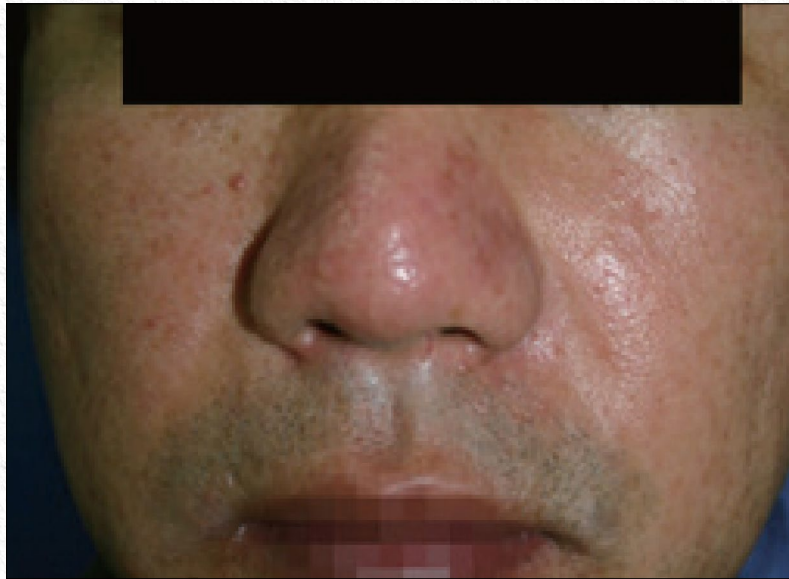*Courtesy of WS Kim, MD, South Korea*

*\* Results may vary by individuals.*

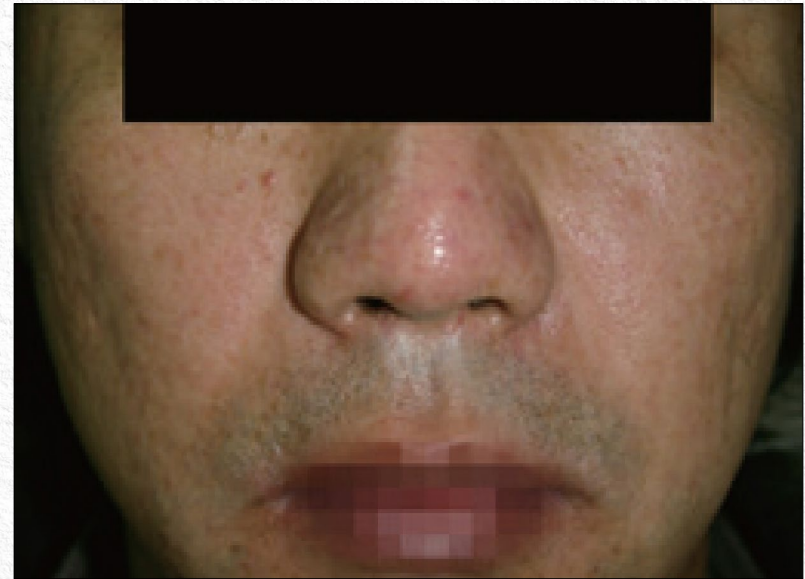

CLINICAL PHOTOS

# Telangiectasia



**Before**



**After**

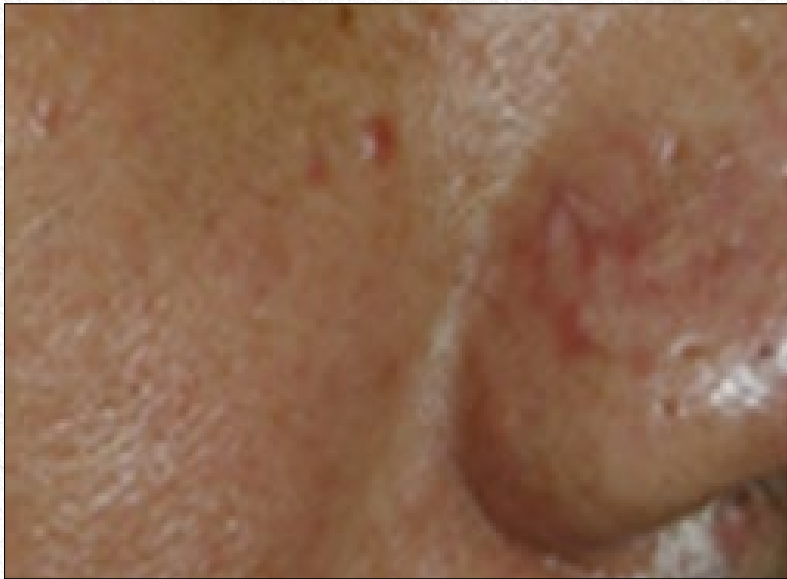*Courtesy of WS Kim, MD, South Korea*

*\* Results may vary by individuals.*

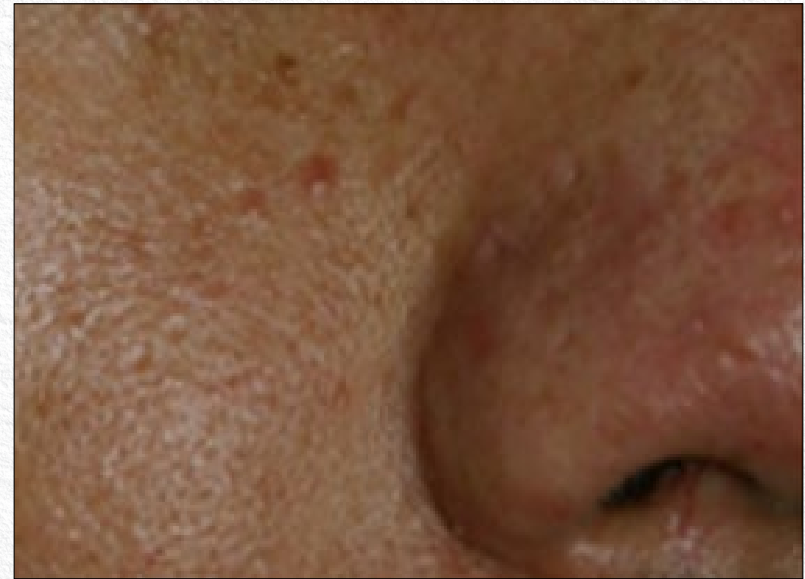

CLINICAL PHOTOS

# Telangiectasia



**Before**



**After**

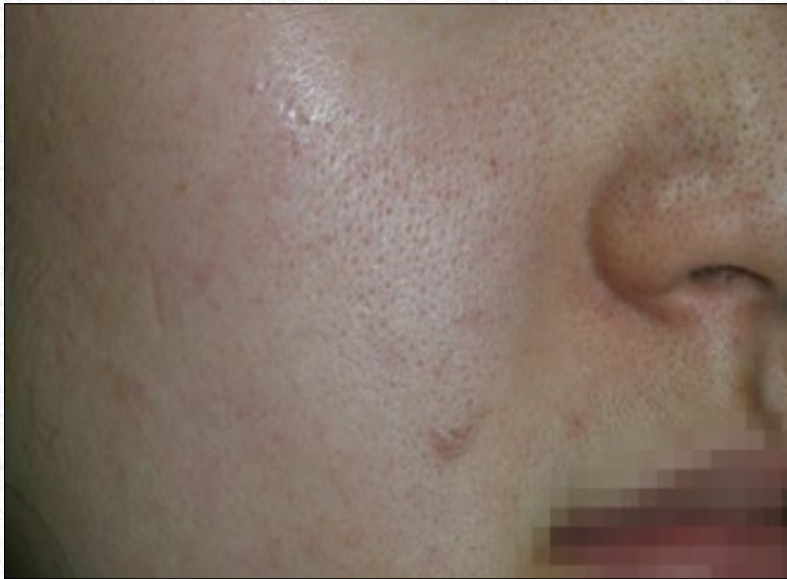*Courtesy of M Lee, MD, South Korea*

*\* Results may vary by individuals.*

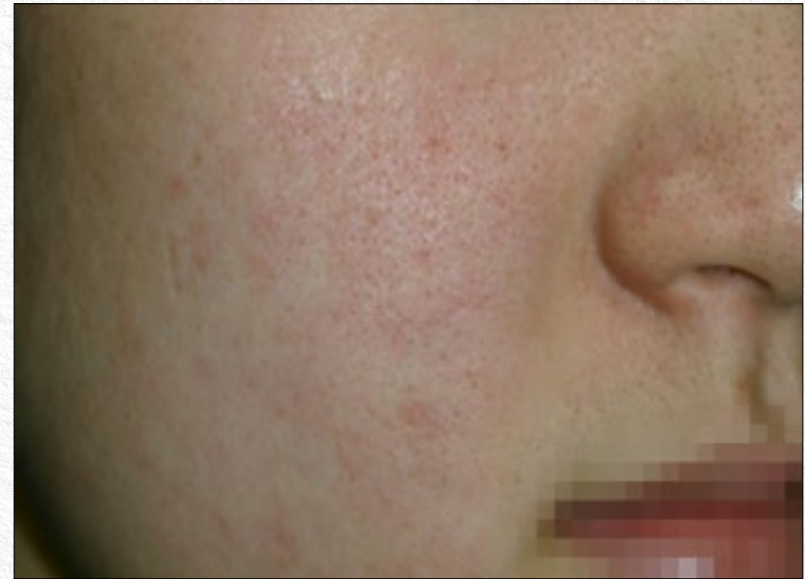

CLINICAL PHOTOS

# Enlarged Pores



**Before**



**After**

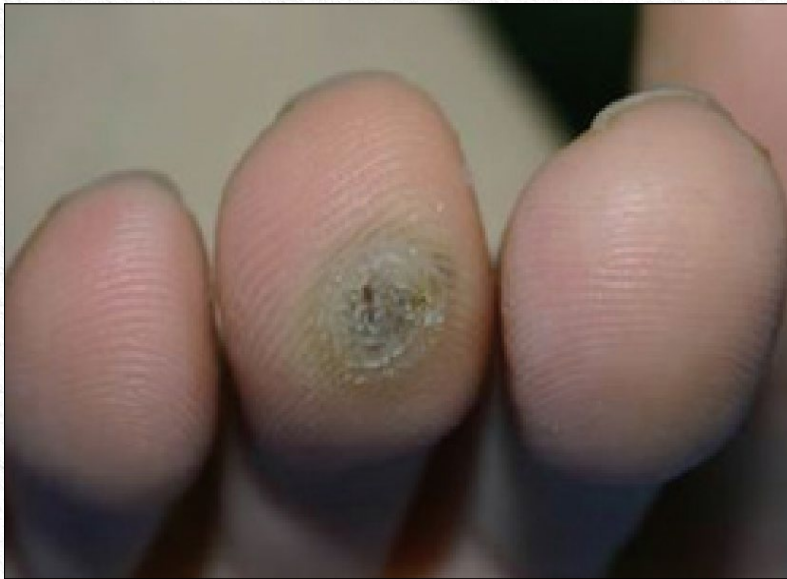*Courtesy of WS Kim, MD, South Korea*

*\* Results may vary by individuals.*

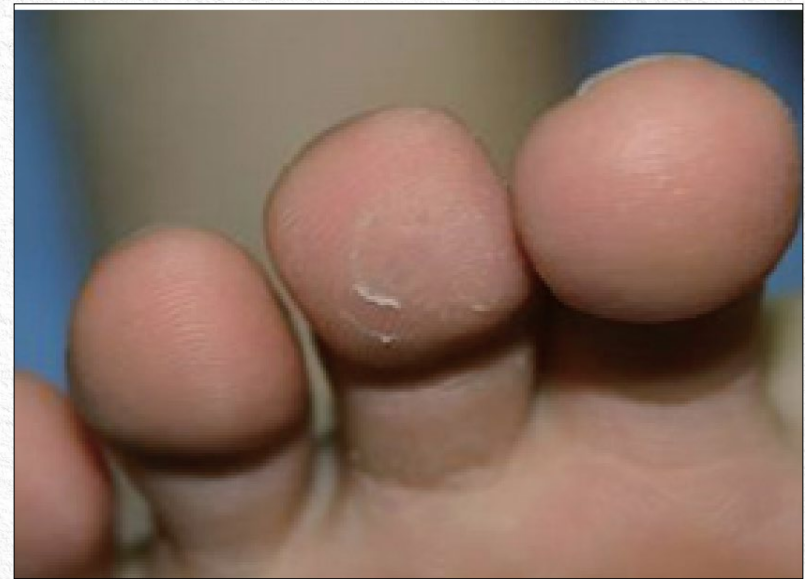

CLINICAL PHOTOS

## Viral Wart (eCO2 + Bleomycin)



**Before**



**After**

*Courtesy of WS Kim, MD, South Korea*

*\* Results may vary by individuals.*