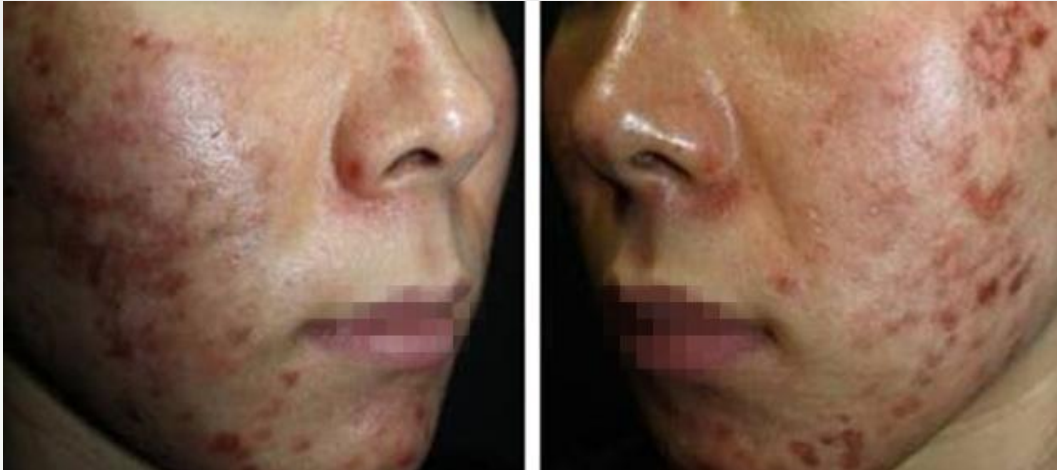


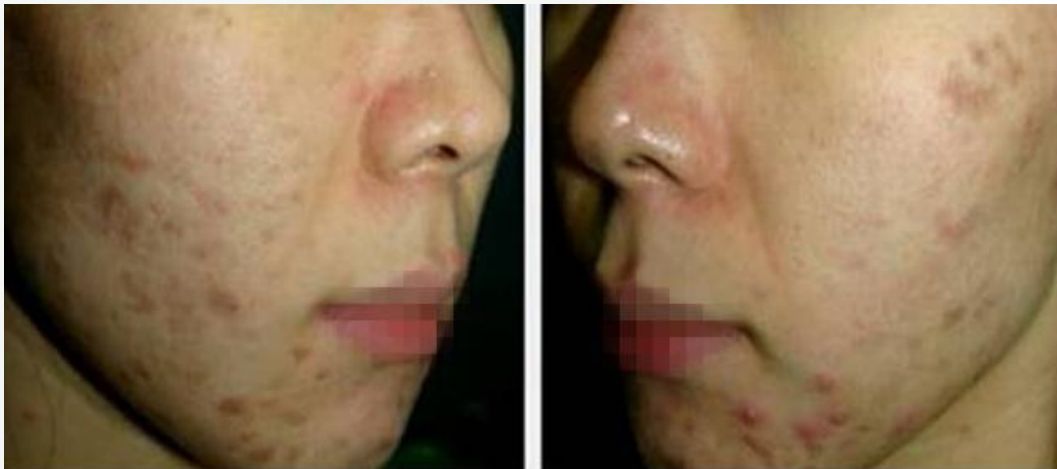
# CLINICAL PHOTOS

## HEALITE 830 nm : Post Chemical Peel(AHA) irritant contact dermatitis

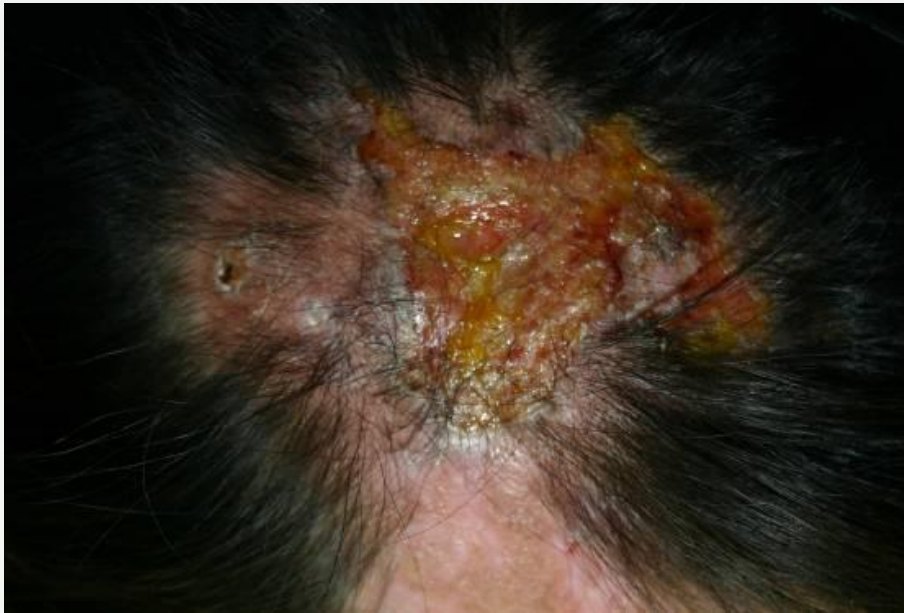

Before Treatment

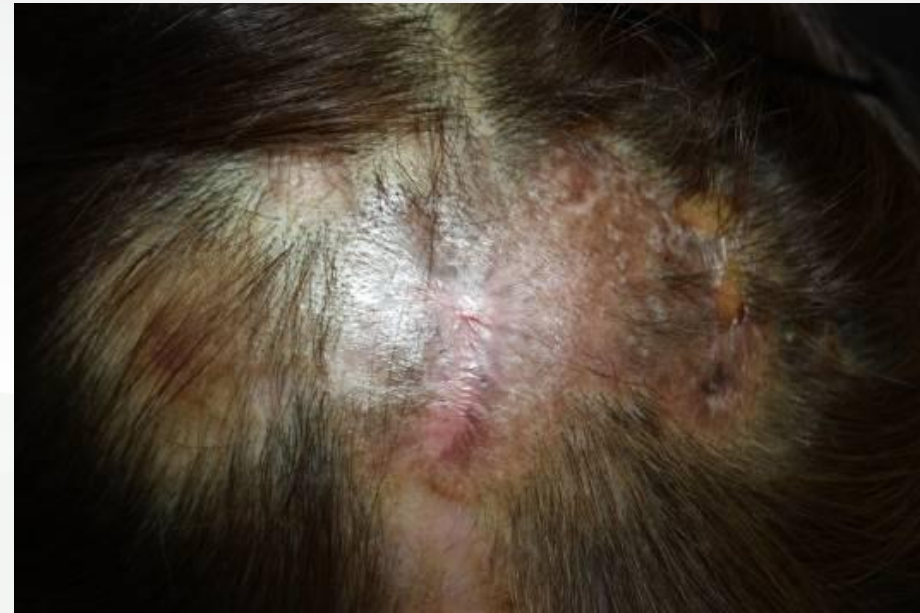

10 Days after 3 Sessions

## HEALITE 830 nm : Dissecting Cellulitis of the Scalp

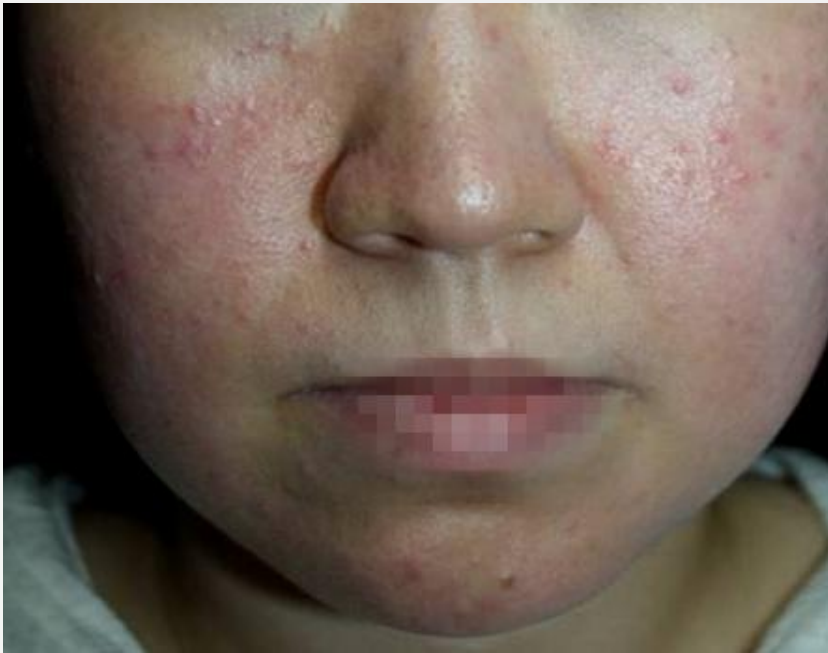

Before Treatment

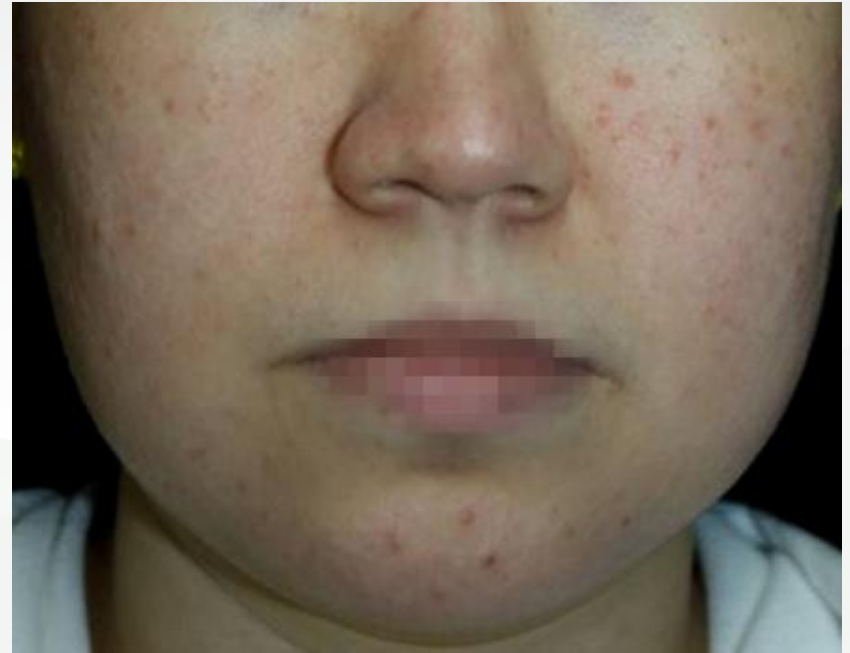

2 Weeks after 4 Sessions

## HEALITE 830 nm : Acne Rosacea

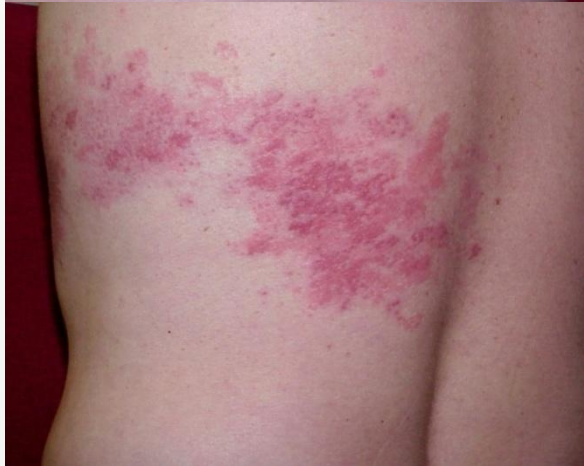
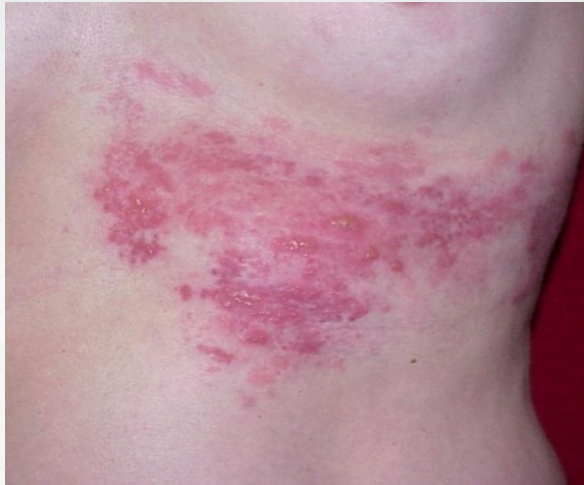
Before Treatment

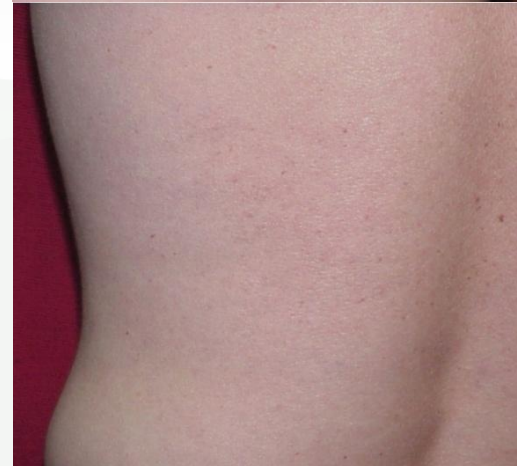
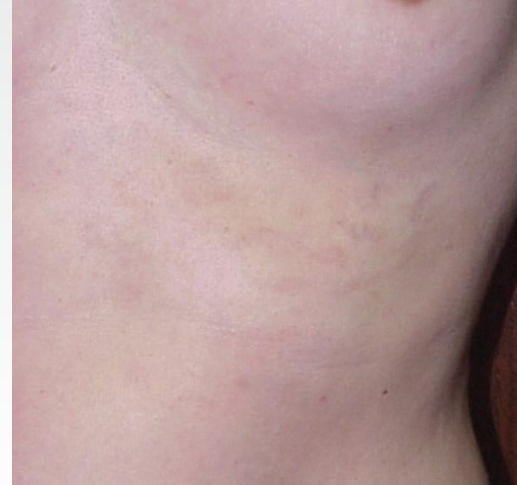
6 Weeks after 6 Sessions

## HEALITE 830 nm : Psoriasis



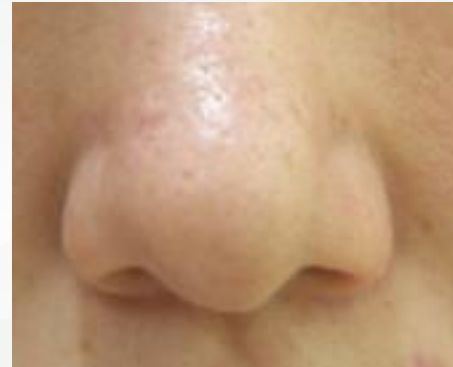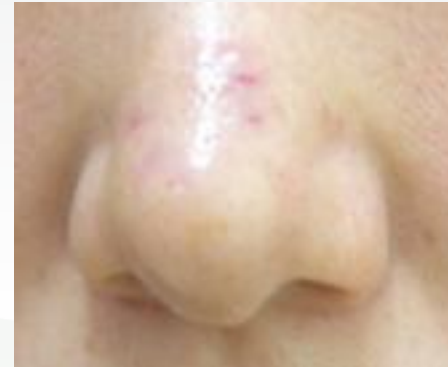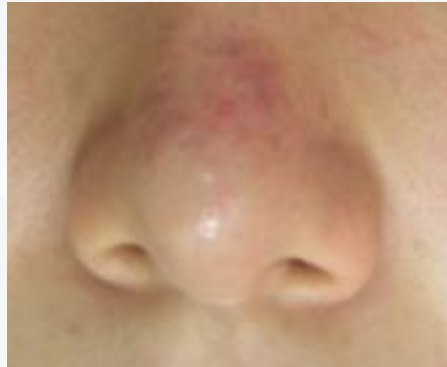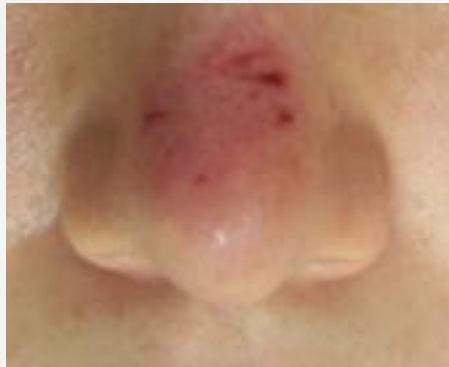Before Treatment



12 Weeks after Treatment



## HEALITE 830 nm : Acute Wound and Secondary Infection Post Dog Bite

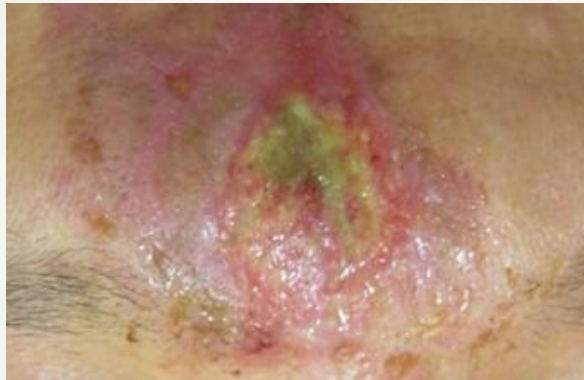


Before Treatment

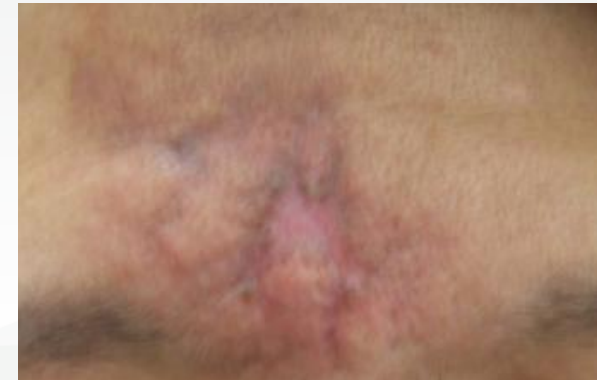
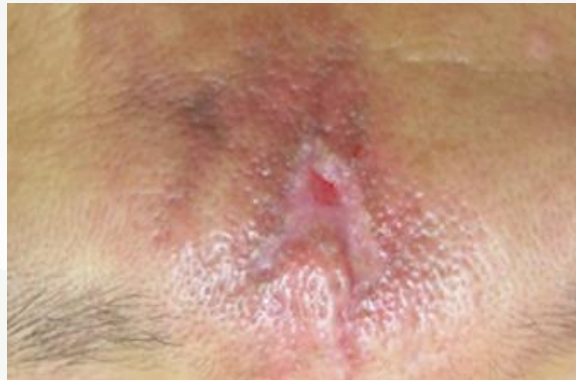
After Treatment

## HEALITE 830 nm : Infection Post Filler Injection



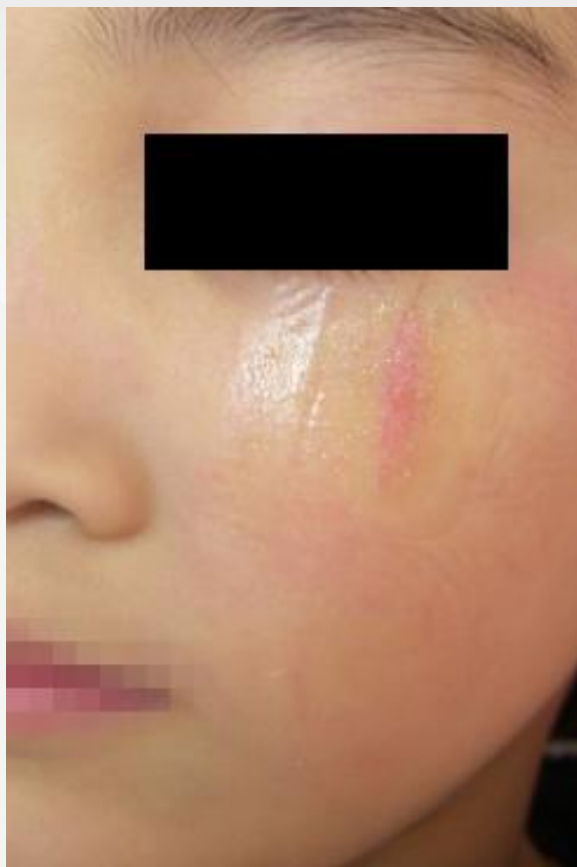Before Treatment



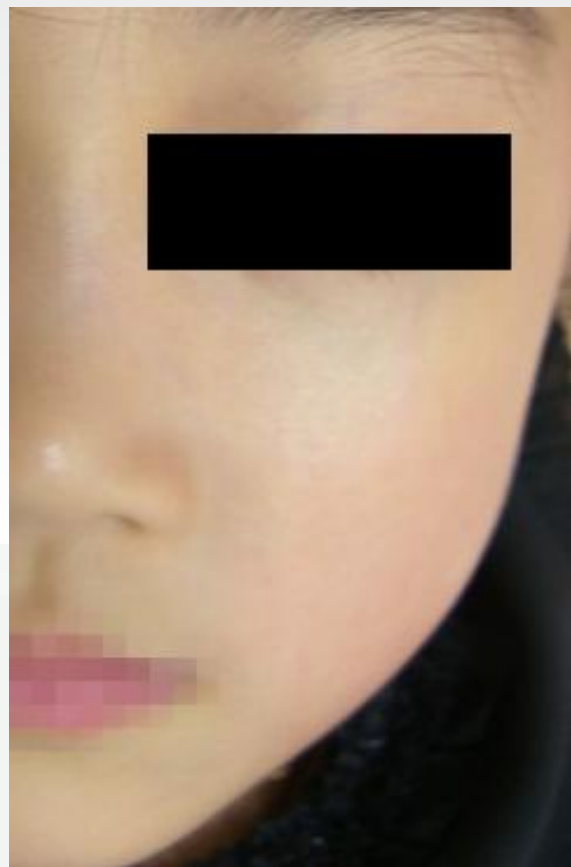4 Weeks after Treatment



## HEALITE 830 nm : Acute Wound



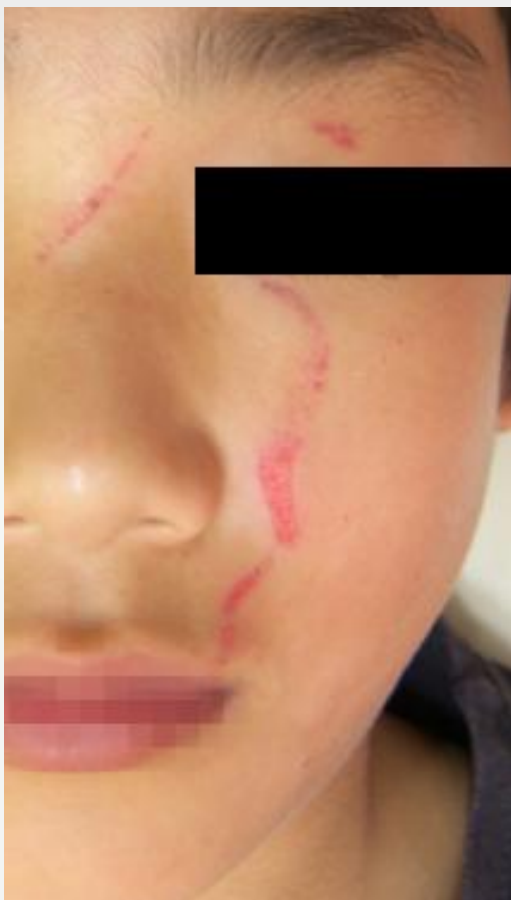Before Treatment



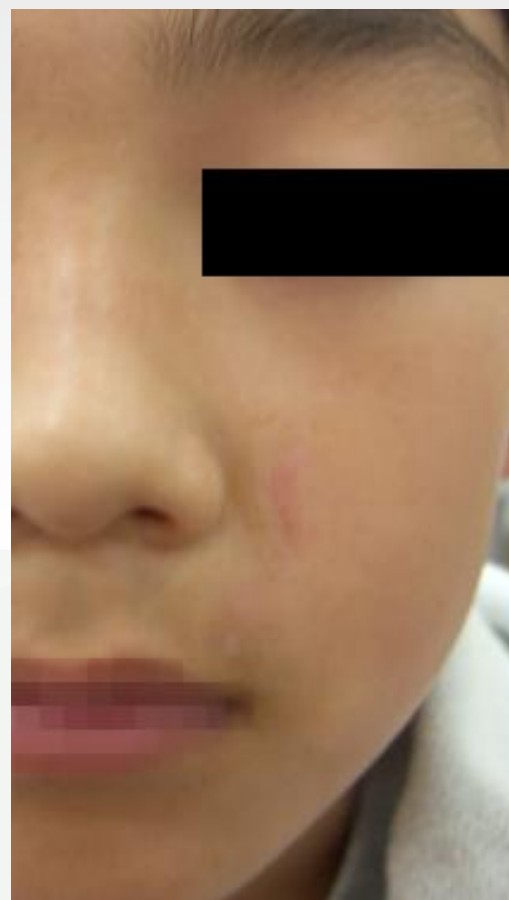After Treatment



## HEALITE 830 nm : Nail Scratching

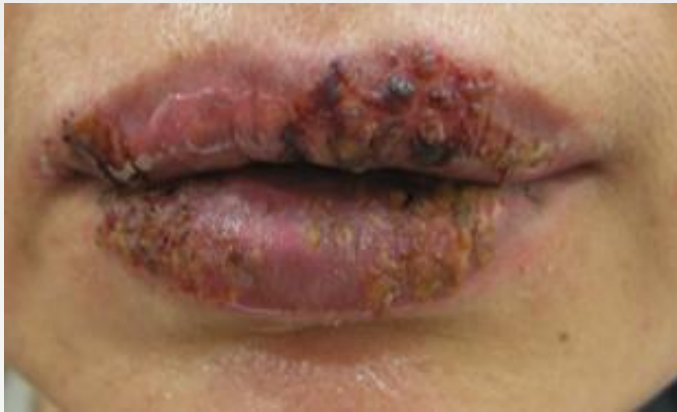

Before Treatment

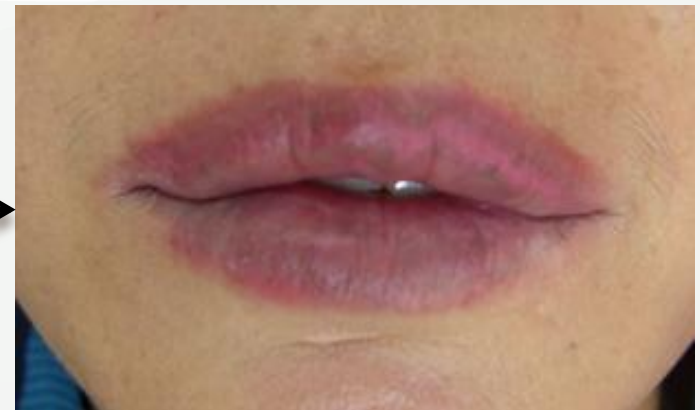
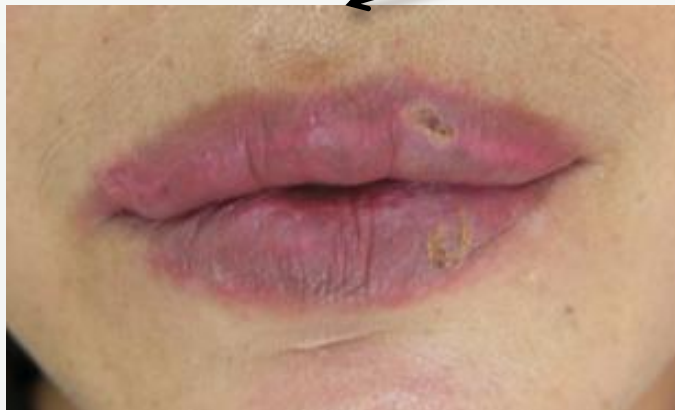
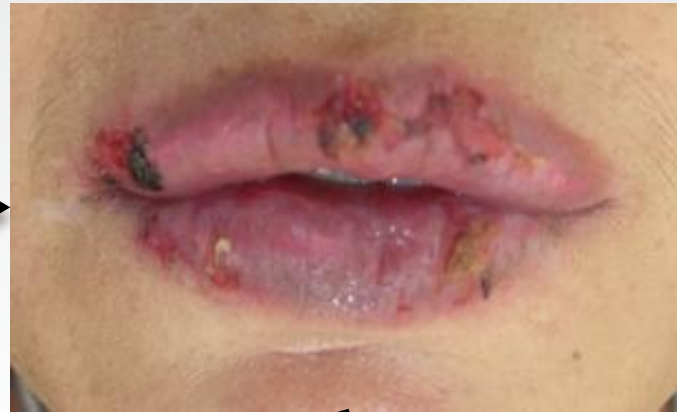After Treatment

## HEALITE 830 nm : Herpes Simplex and Secondary Infection Post Lip Cosmetic Tattoo

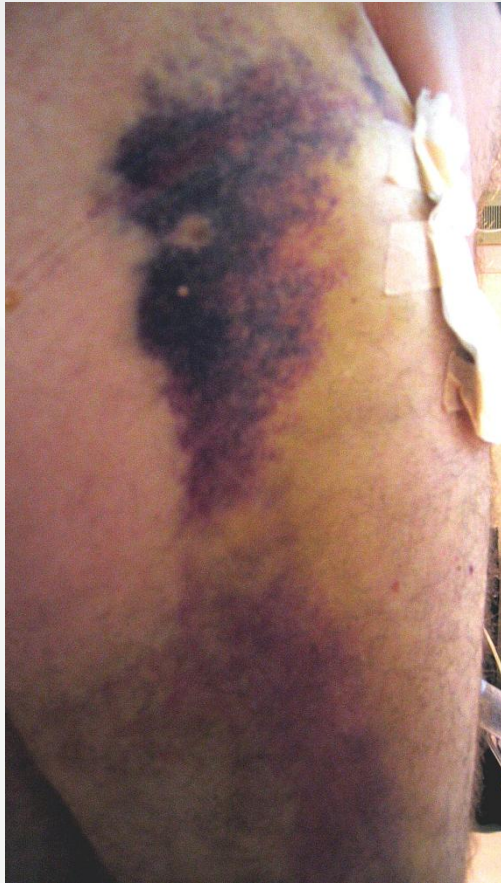

Before Treatment

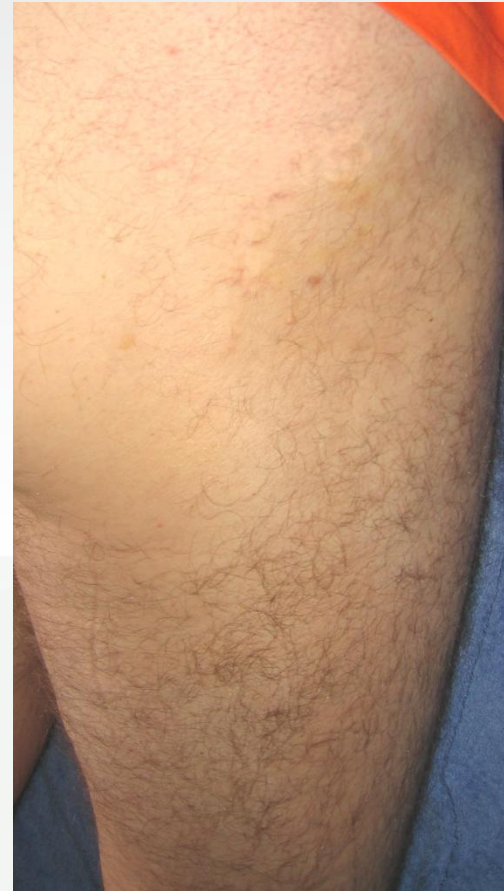

After Treatment

## HEALITE 830 nm : Post-operative Haematoma

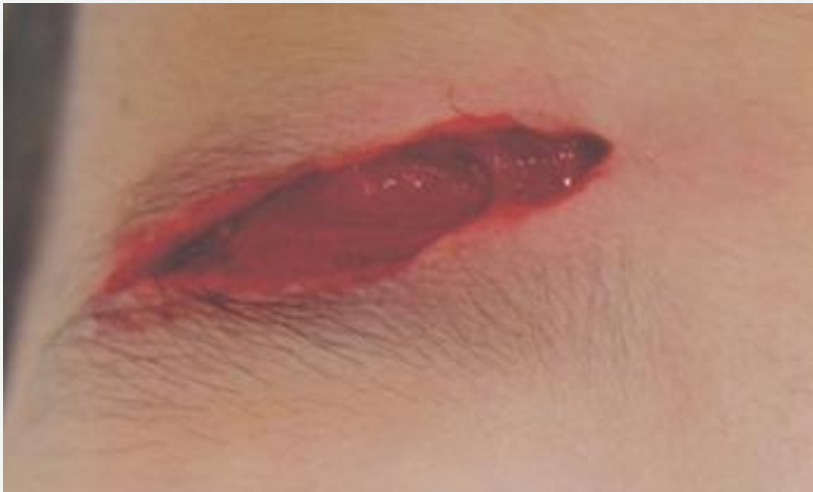

Before Treatment  
(7 days post full hip replacement surgery)

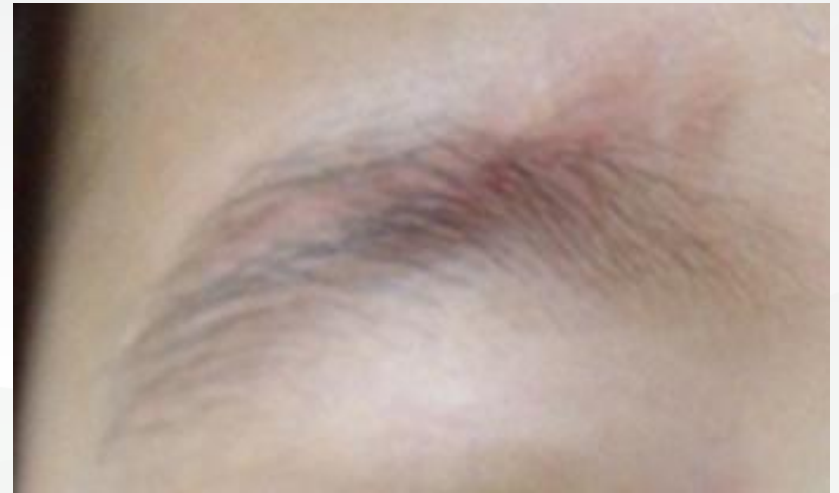

1 Week after 3 Sessions

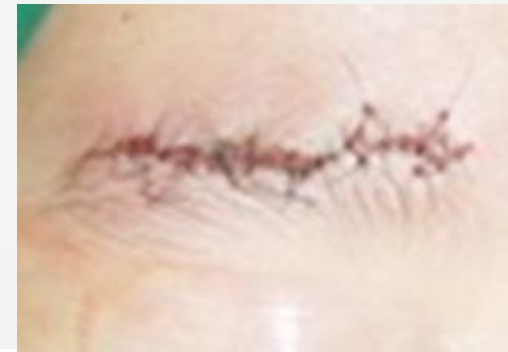## HEALITE 830 nm : Incision Injury



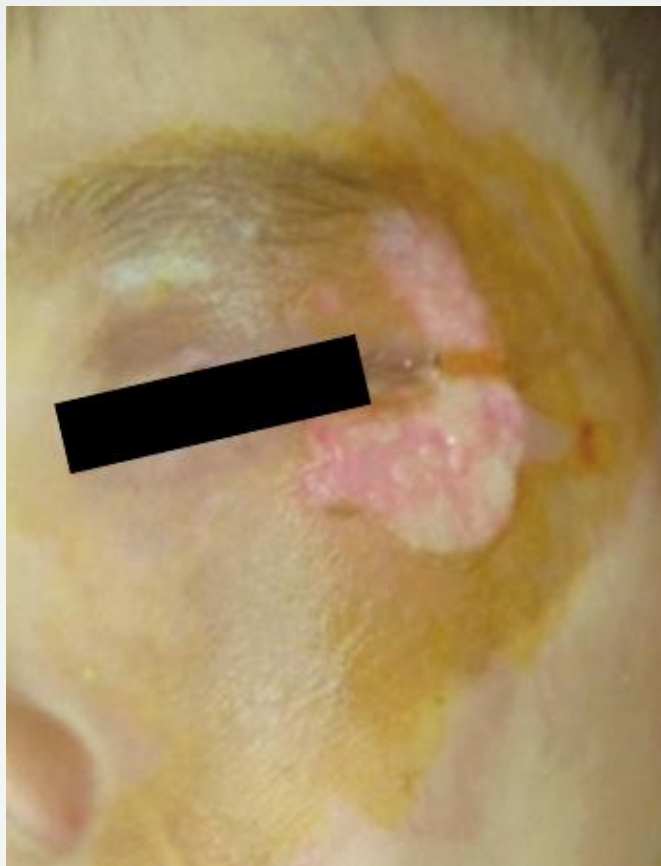
Before Treatment



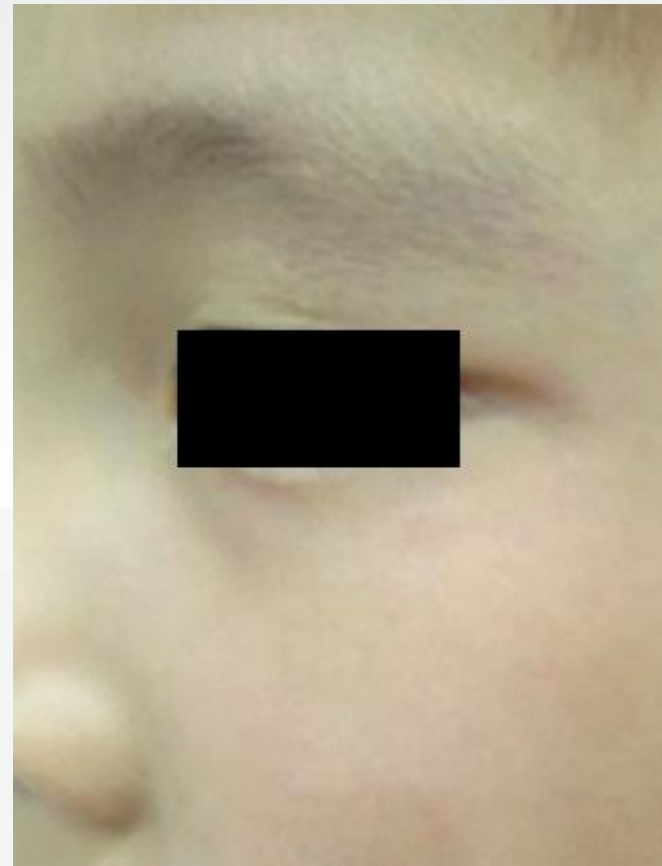6 Weeks after Treatment



## HEALITE 830 nm : Scaled Injury



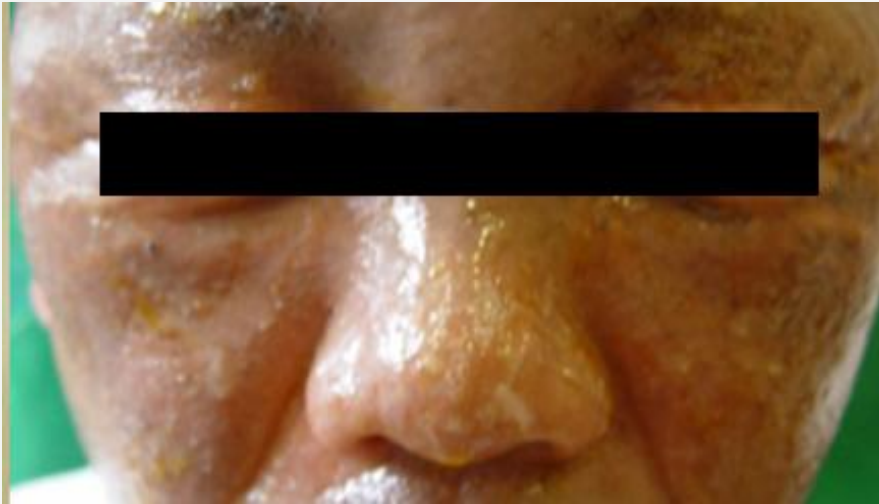Before Treatment



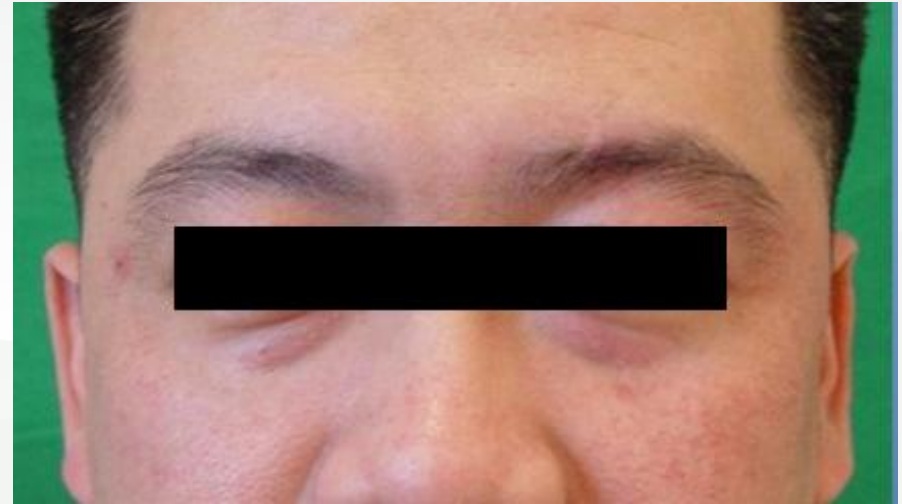5 Weeks after Treatment



## HEALITE 830 nm : Electrical Spark Burn Injury

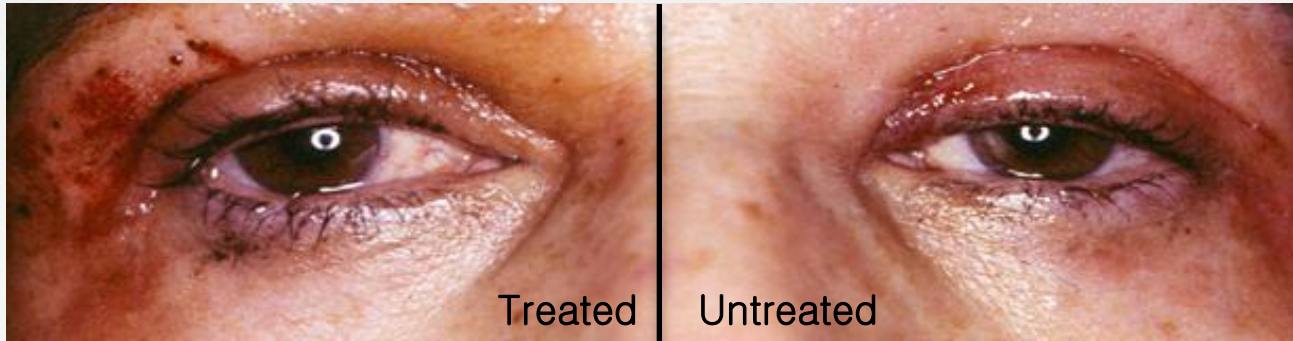


Before Treatment

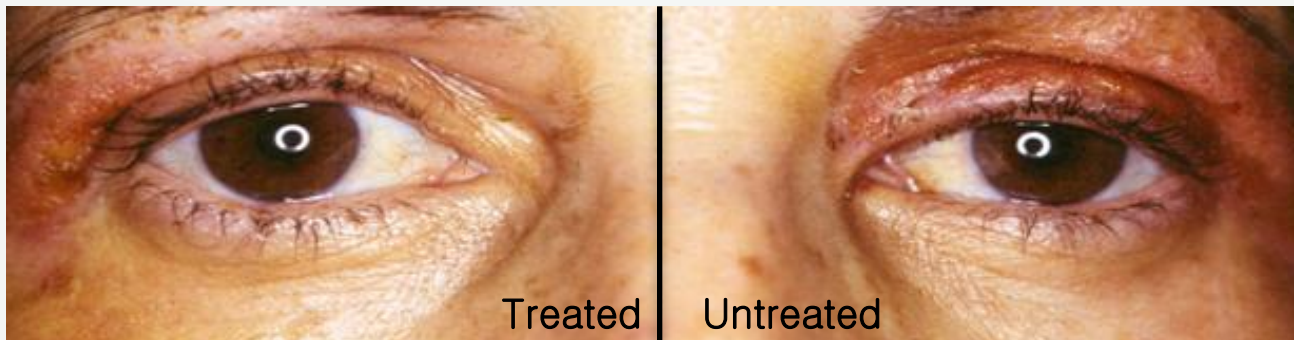


8 Weeks after Treatment

## HEALITE 830 nm : Wound Healing after Surgery

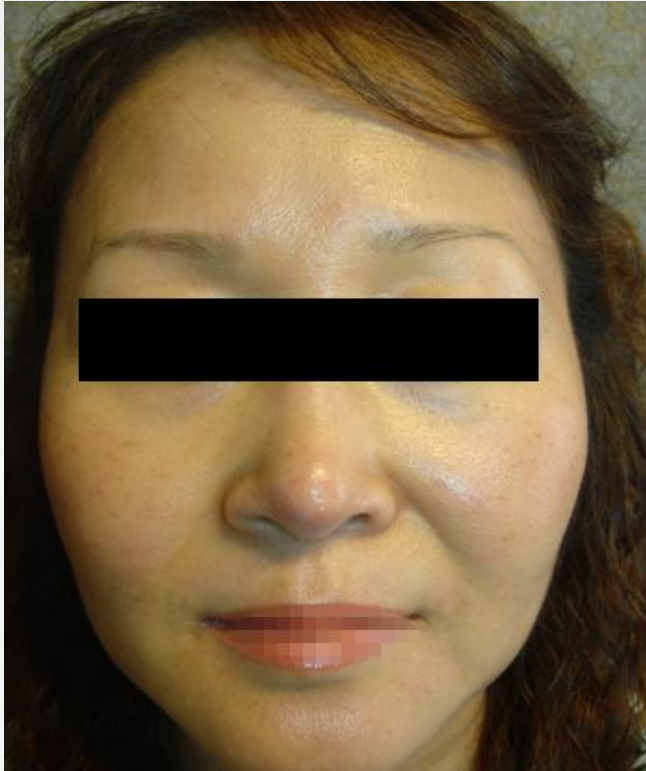

Before Treatment

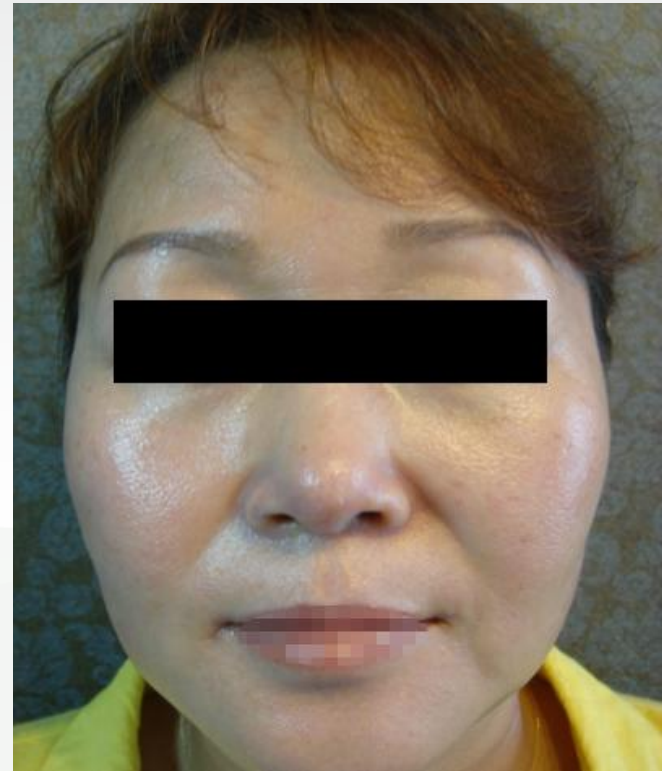


12 Days after Treatment

## HEALITE 830 nm : Skin Rejuvenation

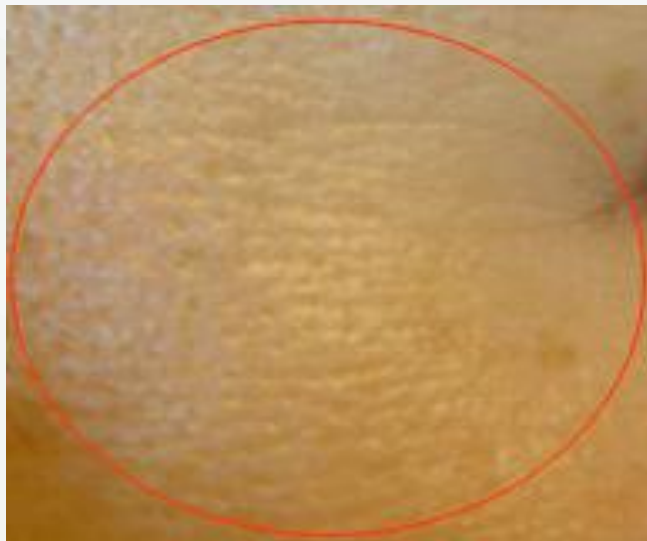

Before Treatment

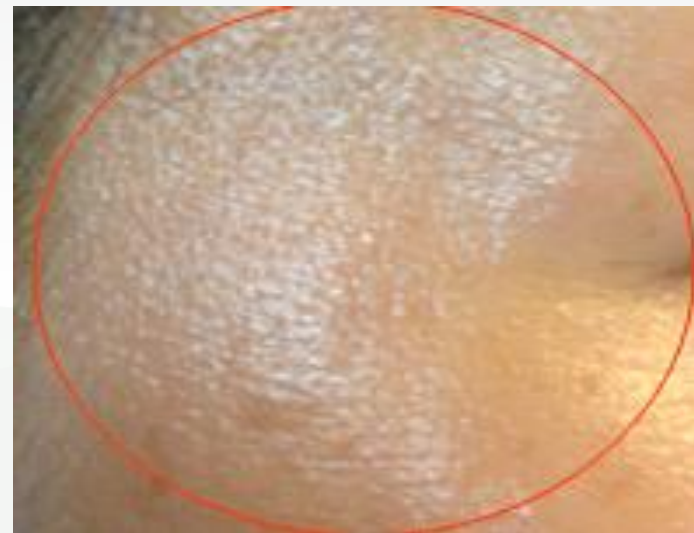

After Treatment

## HEALITE 830 nm : Fine Wrinkles



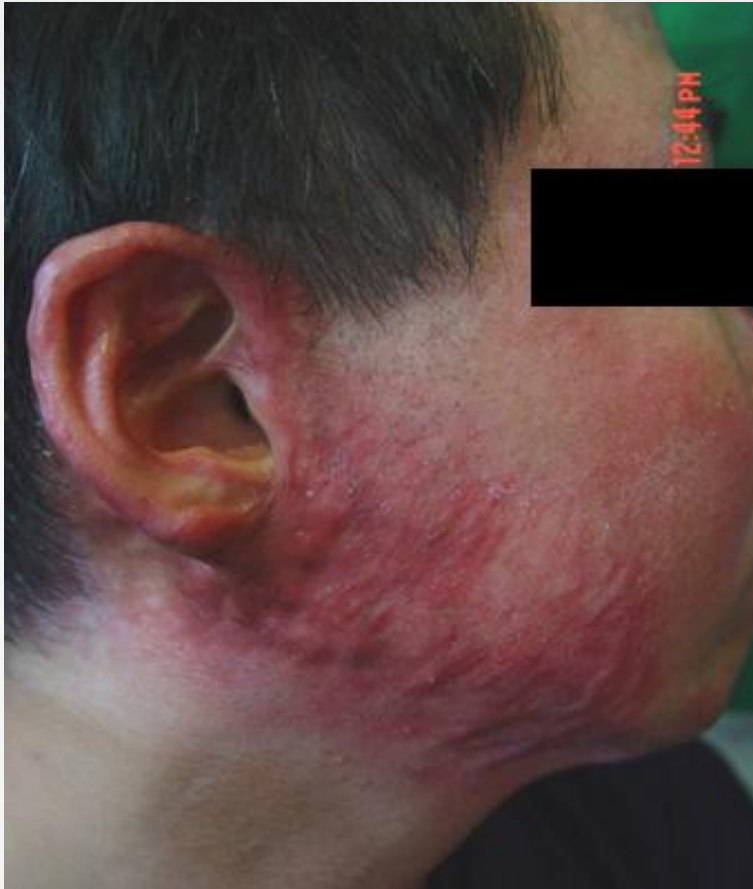Before Treatment



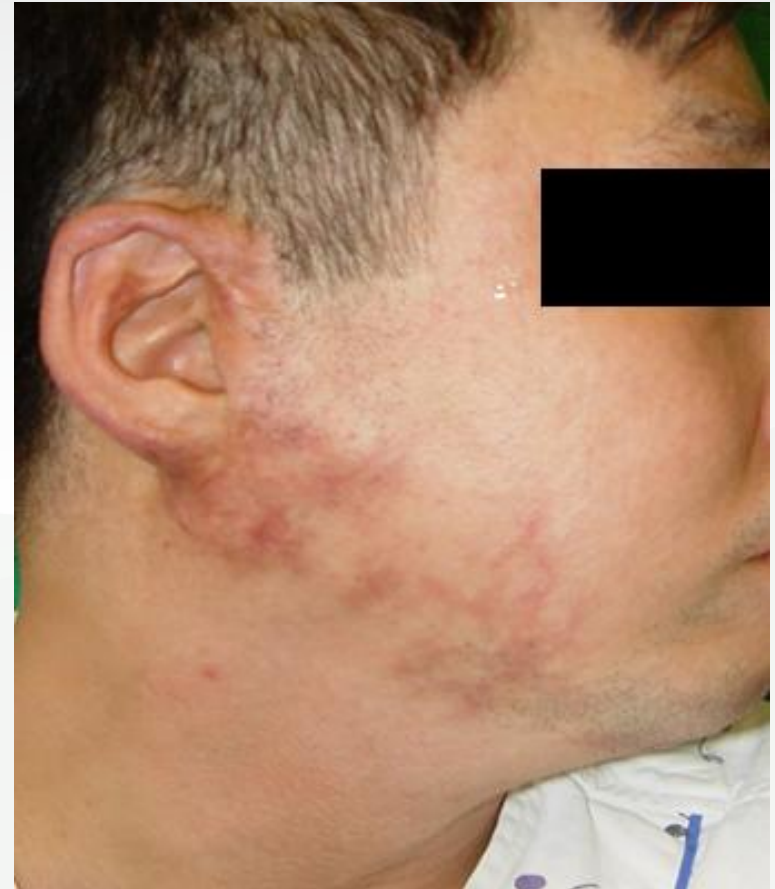After Treatment



## HEALITE 830 nm with CO<sub>2</sub> Laser Pinhole surgery : Keloid Scar



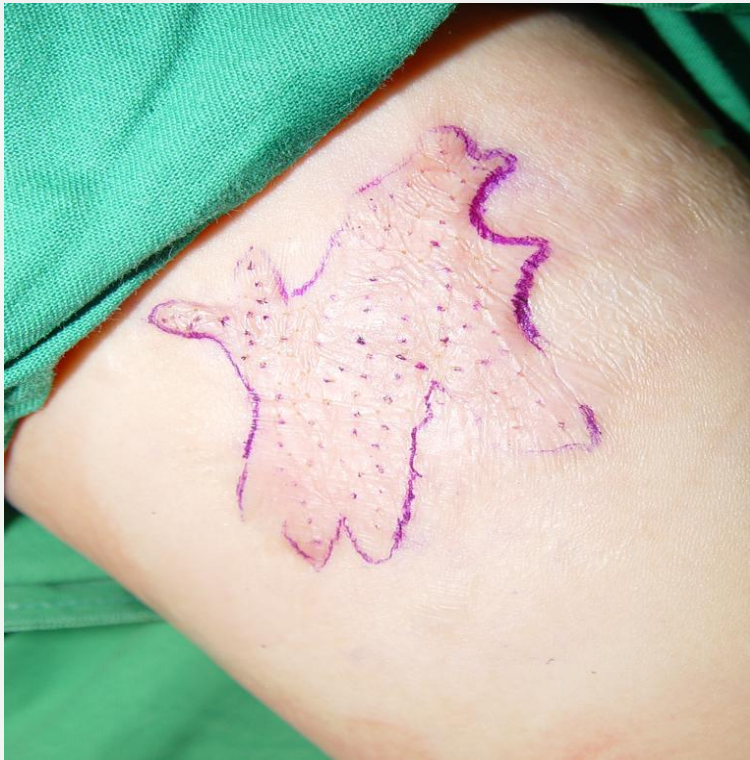Before Treatment



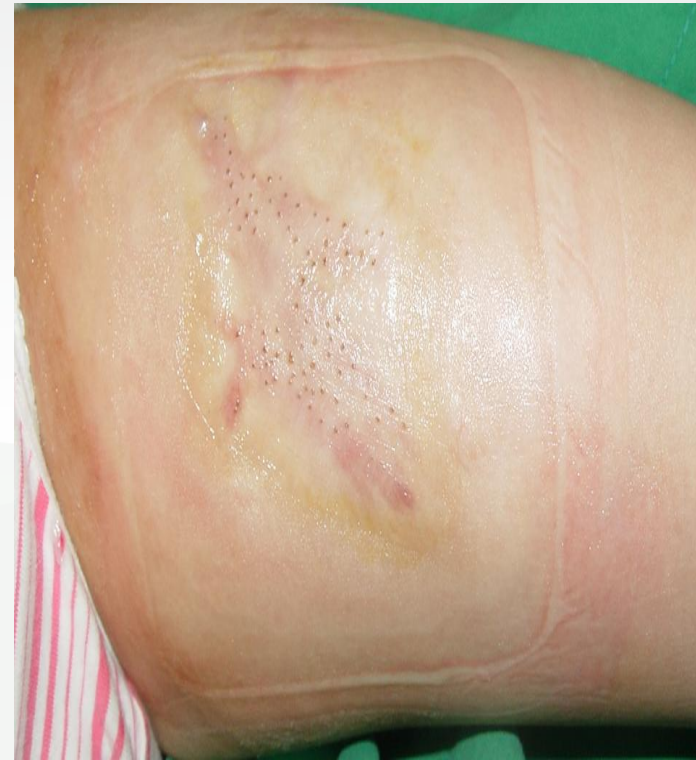After 2 Sessions



## HEALITE 830 nm with CO<sub>2</sub> Laser Pinhole surgery : Hypertrophic Scar



Before Treatment



After 3 Sessions