

PROVEN EFFICACY BY CLINICAL RESULTS

Compilation of clinical evidence provided by aestheticians around the world.

ULTRAFORMER III

Compilation of Clinical Studies

ULTRAFORMER III



Contents

p2

The efficacy of macro-focused ultrasound in the treatment of upper facial laxity: A pilot study

Rungsima Wanitphakdeedecha, MD | Thailand

p12

A New Treatment Protocol of Micro-Focused Ultrasound for Lower Eyelid Fat Bulging

Hye Chan Jeon et al. | South Korea

p20

High-Intensity Focused Ultrasound: A Satisfactory, Non-invasive Procedure for Crow's Feet Wrinkles

Gyu Sik Jung et al. | South Korea

p26

A study of efficacy and safety of high-intensity focused ultrasound for the treatment of melasma in Asians: A single-blinded, randomized, split-face, pilot study

Vasanop Vachiramom, MD | Thailand

p36

Effect of High-Intensity Focused Ultrasound on Eyebrow Lifting in Asians

Won Jong Oh et al. | South Korea

p40

Non-Invasive Arm Fat Reduction

Logan William Thomas et al. | USA

p42

Efficacy of High Intensity Focused Ultrasound (HIFU) for Lifting and Tightening Lax Facial & Neck Skin

Sharmila Nayak | India

p48

Efficacy and Safety of Non-invasive Body Tightening with High Intensity Focused Ultrasound (HIFU)

E.J. Ko et al. | South Korea

p56

High Speed Low-pain Micro Focused Ultrasound Tightening of the Lower Face and Neck

Adrian Lim, MD | Australia

p64

Face Lifting and Body Modeling without a Scalpel

Radoslaw Rzepnikowski, MD | Poland

p68

SMAS Face Lift with HIFU Technology (High Intensity Focused Ultrasound) for the ULTRAFORMER Unit

Klaus Fritz, MD | Germany

p72

The Most Exciting International Evolution in the Non-surgical Facelift

Serena Lim, MD | Australia

p74

ULTRAFORMER Achieves Effective Non-surgical Face Lifting, Tightening, and Whitening

Klaus Fritz et al. | Germany, Italy & South Korea

p80


Evaluation of Micro Focused Ultrasound for Lifting and Tightening the Face

In Ho Lee et al. | South Korea

p86

Tightening Effects of High Intensity Focused Ultrasound on Body Skin and Subdermal Tissue: A Pilot Study

S.Y. Choi et al. | South Korea



The efficacy of macro-focused ultrasound in the
treatment of upper facial laxity: A pilot study



Rungsima Wanitphakdeedecha, M.D. | M.A., M.Sc. | Chadakan Yan, M.D.
Janice Natasha C. Ng, M.D. | D.P.D.S., Ya-Nin Nokdhes, M.D.
Ploypailin Tantrapornpong, M.D. | M.Sc., Thanya Techapichetvanich, M.D.
Sasima Eimpunth, M.D. | Woraphong Manuskiatti, M.D.

The efficacy of macro-focused ultrasound in the treatment of upper facial laxity: A pilot study

Rungsima Wanitphakdeedecha, et al.

ABSTRACT

Background: Recently, macro-focused ultrasound (MFU) has become a popular non-invasive aesthetic treatment for facial laxity. However, there are no studies done that evaluated the use of MFU with a 2.0 mm transducer for upper facial lifting.

Objectives: To evaluate the efficacy and safety of MFU with a 2.0 mm transducer in the treatment of upper facial laxity in Thai patients

Methods: This was a prospective, evaluator-blinded pilot study with 34 Thai patients diagnosed with mild to moderate facial laxity. Patients were treated with a single session of MFU with 2.0 mm transducer at the forehead, lateral and just below the eye area. Primary outcome was the clinical improvement of upper facial laxity graded by 2 blinded dermatologists at baseline, 1-week, 1-, 3- and 6-month follow-up. Objective measurements including eyebrow height, upper facial volume and textural irregularities were evaluated. Patients' self-assessment scores and adverse effects were also recorded.

Results: Out of 34 patients, 27 (79.4%) attended all follow-ups. Clinical improvement of upper facial laxity was observed as early as 1-week follow-up. Eyebrow height elevation was significantly increased at every follow-up ($p=0.000$) with an average of 1.22 mm at 6-month follow-up. Wrinkles improved significantly at 1-week and 6-month follow-up ($p=0.002$ and $p=0.010$, respectively). Skin roughness showed significant improvement at 6-month follow-up ($p=0.004$). Majority of the patients (53.6%) reported marked improvement at 3-month follow-up. No serious adverse event was noted.

Conclusion: MFU is a safe and effective treatment for upper facial laxity and skin textural irregularities in patients with mild to moderate degree of laxity.

INTRODUCTION

Aging is an inevitable process that manifests differently depending on a patient's skin type, exposures, and genetics.¹ Most common dermatological signs of aging includes skin thinning, xerosis, wrinkles, hyperpigmentation and skin laxity.^{1,2} It was found that Asians have denser dermal tissue compared to Caucasians, which likely contributes to a lower incidence of wrinkling and skin laxity.²

Facial laxity and wrinkles in the aging skin are common cosmetic concerns.³ Rhytidectomy or facelift surgery remains to be the gold standard procedure but most would prefer less invasive modalities to avoid surgical complications, prolonged downtime and to achieve a subtler and natural appearance.⁴ Minimally invasive procedures for facial laxity includes lasers, soft dermal fillers, neurotoxins, energy based devices (radiofrequency, ultrasound), fat grafting and thread lifts.⁵⁻⁸ High intensity focused ultrasound (HIFU) technology has been used as a noninvasive surgical tool to treat a variety of solid malignant tumors since it offers less complications compared to conventional

treatment modalities such as surgery.⁹ In contrast, HIFU uses a much lower ultrasound energy to treat the superficial layers of the skin.¹⁰ In 2009, micro-focused ultrasound with visualization (MFU-V) was approved by the US Food and Drug Administration (US FDA) for non-invasive brow elevation.¹¹ This ultrasound device is capable of heating the tissues at approximately 65°C, by producing discrete thermal injury zones (<1mm³) at consistent depths depending on the transducer used.¹² The ultrasound energy delivered causes contraction of the denatured collagen fibers, neocollagenesis and collagen remodeling, which leads to lifting and tightening of the skin.¹³ Available MFU-V are launched with various attached transducers that emit frequencies of 10.0 MHz, 7.0 MHz and 3.0 MHz with variable depths of 1.5 mm (dermis), 3.0 mm (deep dermis) and 4.5 mm (subdermal and superficial muscular aponeurotic system).¹⁰ Currently, the new macro-focused ultrasound (MFU) with 2.0 mm transducer has been promoted to use for upper facial skin.

In a previous study, MFU-V with a 3.0 mm transducer was reported to lift the eyebrow height by 1.7 mm at 90

days after treatment when compared to baseline.¹⁴ At present, there are no studies done using MFU with a 2.0 mm transducer for the treatment of upper facial laxity. The result might be different among different ethnicities because of variations in the aging characteristics and dermal thickness. The objective of this study was to evaluate the efficacy and safety of HIFU with a 2.0 mm transducer in the treatment of upper facial laxity in Thai patients.

MATERIALS AND METHODS

This was a prospective, single-center, evaluator-blinded pilot study. A total of 34 Thai patients, male or female, age range between 30-50 years old, Fitzpatrick skin types III-V and diagnosed with mild to moderate facial laxity were included in the study. Exclusion criteria included patients who are pregnant or lactating, have pacemaker or metal implantation, facial surgical scar, history of keloid or hypertrophic scar formation, history of botulinum toxin or filler injection in the last 2 weeks before the study, history of thread lift, have ptotic fat, history of herpes simplex infection, history of active or systemic infection, who received non-steroidal anti-inflammatory drug (NSAID), aspirin, steroid, heparin, vitamin K or E in the last 72 hours before the study.

All patients underwent a single treatment session using the MFU device (Ultraformer III, Classys Inc., Seoul, Korea) for upper facial laxity. Preoperatively, topical anesthetic cream (EMLA[®], AstraZeneca, Wilmington, DE, USA) was applied for 40 minutes prior to the treatment with occlusion. Ultrasound gel was applied to the target site and the device was gently pressed perpendicularly to the skin surface. The forehead, under and lateral eye area were treated with a 2.0 mm transducer (5.5 MHz). The application involved 90 horizontal lines in the forehead. In the lateral eye area, 5 horizontal and vertical lines are applied on each side. In the under eye area, 15 horizontal lines are applied on each side. Thus, a total of 140 lines were delivered in each patient. The energy for the ultrasound pulse was 0.2 - 0.4 J with a range of pitch at 1.5 mm.

Postoperatively, the patients were instructed to apply cold compress to the treated area to reduce pain and inflammation. They were also advised to use broad spectrum sunscreen and to avoid extremely hot or

cold exposure, or any laser or radiofrequency therapy throughout the study.

The primary outcome of the study was the clinical improvement of upper facial laxity using the quartile grading scale: 0= no improvement, 1= minimal improvement (1–25%), 2= moderate improvement (26–50%), 3= marked improvement (51–75%) and 4= excellent improvement (76–100%). Subjective evaluation of the photographs was graded by 2 blinded dermatologists at baseline, 1 week, 1-, 3-, and 6-month follow-up. All clinical photographs were taken with identical camera settings, lighting, and positioning using a Canon PowerShot G9 stand-off camera (OMNIA imaging System, Canfield Scientific Inc., Fairfield, NJ).

In addition, eyebrow height, upper facial volume, wrinkles and skin texture were objectively evaluated at baseline, 1 week, 1-, 3- and 6-month follow-up. The average eyebrow height was measured using ImageJ software, by calculating the average vertical distance from the highest point of the eyebrow to the level of both mid pupils in 5 positions per side (a; medial canthus, b; medial limbus, c; mid pupil, d; lateral limbus, and e; lateral canthus to the highest point of the eyebrow) as shown in Figure 1. The upper facial volume was analyzed using 3 dimensional photographs captured by Vectra H1 Imaging System[®] (Canfield Scientific, NJ, USA). Skin textural irregularities (wrinkles, skin roughness, melanin concentration) were analyzed using Antera3D[®] (Miravex Limited, Dublin, Ireland). Patients' self-assessment score was evaluated using the same quartile scale on every follow-up. Pain score during the treatment was rated using a 10-point visual analogue scale (VAS). Adverse events were also evaluated.

Repeated measure ANOVA and paired T-test were used for parametric distribution data. Friedman test and Wilcoxon signed ranked test were used for non-parametric distribution data. A p-value < 0.05 was considered statistically significant. The statistical analysis was performed using a statistical software (SPSS version 18.0; SPSS Inc., Chicago, USA).

This study was approved by the ethics committee of the Siriraj Institutional Review Board. Written informed consents were obtained from all patients prior to their enrollment in the study.

RESULTS

Of all 34 patients recruited, 27 (79.4%) completed the follow-ups. Seven patients were not able to attend the 6-month follow-up. The demographic data of the patients enrolled were described in Table 1.

Subjective evaluation of the upper facial laxity by photographic evaluation by 2 blinded dermatologists using the quartile grading scale was presented in Figure 2. As early as 1-week follow-up, 64.7% had minimal improvement (0-25%) when compared to the baseline. At 1-month follow up, majority (82.4%) still had minimal improvement, which was consistent until the 3-month follow-up (67.6%). However, at 6-month follow-up, most (51.9%) showed no improvement (0%) when compared to baseline. The clinical improvement of the upper facial laxity after MFU treatment is presented in Figure 3.

The eyebrow height measurements taken using ImageJ Software were described in Table 2. The average mean difference in eyebrow height was significantly increased on all follow-ups when compared to the baseline ($p=0.000$). The average eyebrow height elevation was 1.51 mm at 1-month, 1.25 at 3-month and 1.22 mm at 6-month follow-up. There was an increasing in the upper facial volume from baseline compared to all follow-ups as presented in Table 3, although it was not statistically significant.

The evaluation of textural irregularities (wrinkles, skin roughness and melanin concentration) using Antera3D[®] were described in Table 4. There was a decreasing in the wrinkle index on all follow-ups when compared to the baseline, however it was significant only on 1-week and 6-month follow-up ($p=0.002$ and $p=0.010$ respectively). Skin roughness also showed significant improvement at 6-month follow-up ($p=0.004$). Melanin concentration showed no significant difference from baseline compared to all follow-up visits.

Patients' self-assessment was also recorded on all follow-ups. As early as 1-week follow-up, majority (46.4%) reported minimal improvement, which continued to increase at 1-month (46.4% moderate improvement) and 3-month follow-up (53.6% marked improvement). However, on the 6-month follow-up, there was a decline in the improvement score wherein majority (38.1%) had moderate improvement (Figure 4).

All patients developed mild erythema immediately

after the treatment with spontaneously resolved at 1-week follow-up. No post-inflammatory hypo- or hyperpigmentation, bullous formation, scar, crusting, oozing and any serious adverse events were recorded in this study.

Characteristics	Value (n=34)
Age, mean \pm SD*	35.41 \pm 6.31* (range 20-49)
Sex, n (%)	
Male	5 (14.7)
Female	29 (85.3)
Skin type, n (%)	
III	1 (2.9)
IV	29 (85.3)
V	4 (11.8)
Number of Lines 2.0 mm transducer	32.29 \pm 9.19
Mean pain score	3.03 \pm 1.57

*SD, standard deviation

TABLE 1 Demographic data of patients enrolled in the study.

Follow-Up	Eyebrow Height Measurements		
	Mean \pm SD(cm)	Mean Difference(cm)	p-value
Baseline	2.95 \pm 0.45		
1-week follow-up	3.05 \pm 0.50	0.095 \pm 0.015	0.000*
1-month follow-up	3.10 \pm 0.48	0.151 \pm 0.016	0.000*
3-month follow-up	3.08 \pm 0.45	0.125 \pm 0.016	0.000*
6-month follow-up	3.07 \pm 0.46	0.122 \pm 0.017	0.000*

*p-value compared to baseline with statically significant difference

TABLE 2 Assessment of eyebrow height measurement using ImageJ Software.

Follow-Up	Difference of volume compared to baseline (mm ³)		
	Mean \pm SD*	Median	p-value
1-week follow-up	0.15 \pm 0.77	0.131	
1-month follow-up	0.57 \pm 0.76	0.288	0.18
3-month follow-up	0.45 \pm 0.59	0.454	0.96
6-month follow-up	0.36 \pm 0.63	0.166	0.372

*SD, standard deviation

TABLE 3 Assessment of upper facial volume measurement using Vectra H1 Imaging System[®]

Evaluation	Baseline	1-week follow up	1-month follow up	3-month follow up	6-month follow up
Wrinkles	15.86 ± 3.72	14.83 ± 3.53 (p = 0.002)*	15.51 ± 3.85 (p= 1.000)	15.38 ± 4.15 (p= 0.702)	14.97 ± 3.79 (p= 0.010)*
Skin Roughness	16.07 ± 4.38	15.21 ± 4.35 (p=0.092)	15.77 ± 4.52 (p= 1.000)	15.57 ± 4.91 (p= 1.000)	15.63 ± 4.28 (p=0.004)*
Melanin concentration	0.673 ± 0.075	0.673 ± 0.073 (p= 1.000)	0.671 ± 0.073 (p= 1.000)	0.673 ± 0.079 (p= 1.000)	0.665 ± 0.081 (p=0.745)

*p-value compared to baseline with statistically significant difference

TABLE 4 Assessment of wrinkles, skin roughness and melanin concentration using Antera3D®

DISCUSSION

Upper facial aging involves progressive loss of volume, sagging of facial soft tissue, skeletal bone loss, decrease in skin elasticity, skin damage and wrinkles at the forehead and periocular area.¹⁵ Currently, HIFU technology has become a popular non-invasive aesthetic treatment for lifting and tightening because of its excellent safety profile when compared to the gold standard, rhytidectomy.^{16,17}

HIFU delivers highly focused energy that is deposited in the form of heat leaving the surrounding area unaffected. The lesion that it creates are targeted, predictable and reproducible in terms of depth, size, and shape based on hand-piece frequency and source conditions (power, exposure time, and energy).¹⁸ A previous study concluded that HIFU delivers energy in a transcutaneous manner without damaging the skin surface since the biophysical properties of the skin (transepidermal water loss, temperature, hydration and erythema) did not change significantly after treatment and at long term follow up of 24 weeks.¹⁹ Confirmation by histology shows that the skin tightening and lifting effect of HIFU is attributed to an increase in dermal collagen with thickening of the dermis and straightening of elastic fibers in the reticular dermis after treatment.²⁰

In this study, we reported that there was an increase in upper facial volume, but no significant difference between each follow-up visits when compared to the baseline. The increase in upper facial volume indicated the eyebrow lifting effect of MFU (average of 1.51 mm and 1.25 mm at 1-month and 3-month follow-up, respectively). At

6-month follow-up, the average eyebrow height was 1.22 mm which highlights that the lifting effect of MFU was maintained until 6 months.

A study was conducted among 25 patients with facial laxity treated with MFU-V (3.0 mm transducer, 7 MHz) and the average eyebrow lift was 0.47 mm at 3-months follow-up and a 0.12 mm decrease from the baseline at 6-month follow-up.²¹ The decline in brow lift after 3-months follow-up was also reported in our study, and according to the authors this could be due to possible volume loss caused by the thermal injury in MFU-V. Another study with 30 patients (86%) demonstrated an average of 1.7 mm eyebrow height elevation at 3-month follow-up after MFU-V (4.5 mm transducer, 7 MHz) treatment on the forehead.¹⁴ The variability among the results could be due to the different transducers used in each study and the number of lines delivered to the area. It was demonstrated that higher frequency waves produce more shallow focal injury zones while lower frequency produces a greater depth of penetration with deeper thermal coagulation points.¹³

The difference between MFU-V and MFU used in this study was the transducers. MFU-V utilized 3.0 mm and 4.5 mm transducer at 7 MHz to deliver micro-focused beam in dermis resulting in coagulation at targeted areas. Each beam will create thermal coagulation point with 0.5 mm in diameter.^{14,21} In contrast, 2.0 mm transducer with 5.5 MHz was used to deliver macro-focus beam to create coagulation in larger area to stimulate collagen remodeling effectively. Even though the depth of the transducer used in this study delivering the energy to

more superficial dermis (2.0 mm vs. 3.0 mm or 4.5 mm), the side of thermal coagulation point created by the macro-focused beam of energy was larger when comparing to micro-focused beam (1.0 mm vs. 0.5 mm in diameter, respectively).

We also evaluated the quantitative findings of wrinkles, which improved significantly at 1-week and 6-month follow-up. The immediate effect is theoretically related to the tissue-swelling effect that occurs after ultrasound treatment. This was consistent with a previous study done wherein the mean wrinkles score reduction at 3-months follow-up was statistically significant ($p = 0.0222$).²¹

The mean pain score was 3.03 ± 1.57 , which shows that the treatment procedure was well tolerated by the patients. To further optimize patient comfort during treatment, it was recommended to recline the patient at 30 degrees instead of lying flat to prevent the increase in vascular stasis to the head and neck, which may cause heat sinking and increased perception of pain.²² Different pharmacologic modalities such as inhalation of 50% oxygen/50% nitrous oxide, oral diazepam (5-10 mg) 30 minutes before procedure, ibuprofen (800 mg), intramuscular injection of meperidine (50-100 mg), promethazine (50 mg) or ketorolac (60 mg) and regional lidocaine block were also recommended.²²

Unlike other energy devices, focused ultrasound is a “color-blind” technology as the energy is not selectively absorbed by chromophores.¹⁶ In our study, we found no significant increase in the quantitative melanin concentration of the patients, which could translate there was no occurrence of post-inflammatory hyperpigmentation. In terms of safety, all our patients developed mild erythema immediately after the treatment, which resolved spontaneously. This is a commonly reported transient adverse event of HIFU.²³ Other than that no serious adverse event was noted. These supports the finding that MFU with 2.0 mm transducer is safe in Asian skin types.

Limitation of this study were the small number of patients and having no control group since this was a pilot study. There were also drop-outs because of lost to follow-up after 6 months of treatment. Moreover, we used the quartile scale in grading the clinical improvement and patients’ self-assessment scores. The grading system commonly used to evaluate cosmetic results are the

Subject Global Aesthetic Improvement Scale (SGAIS) and the Physician Global Aesthetic Improvement Scale (PGAIS) since it clearly defines the degree of improvement.^{17,24}

We would recommend further studies to be conducted and to extend the duration of follow up, to assess if the results can be maintained for at least a year. Another study can be done to focus on histological data following 2.0 mm transducer ultrasound pulses.

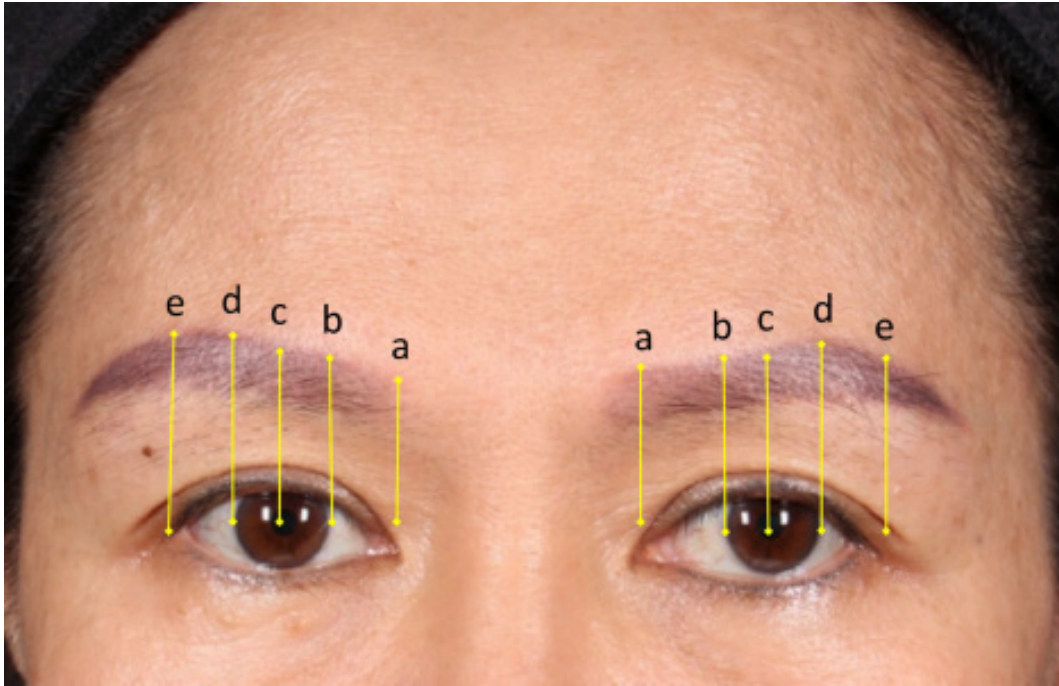


Figure 1 Eyebrow height measurement using ImageJ software.

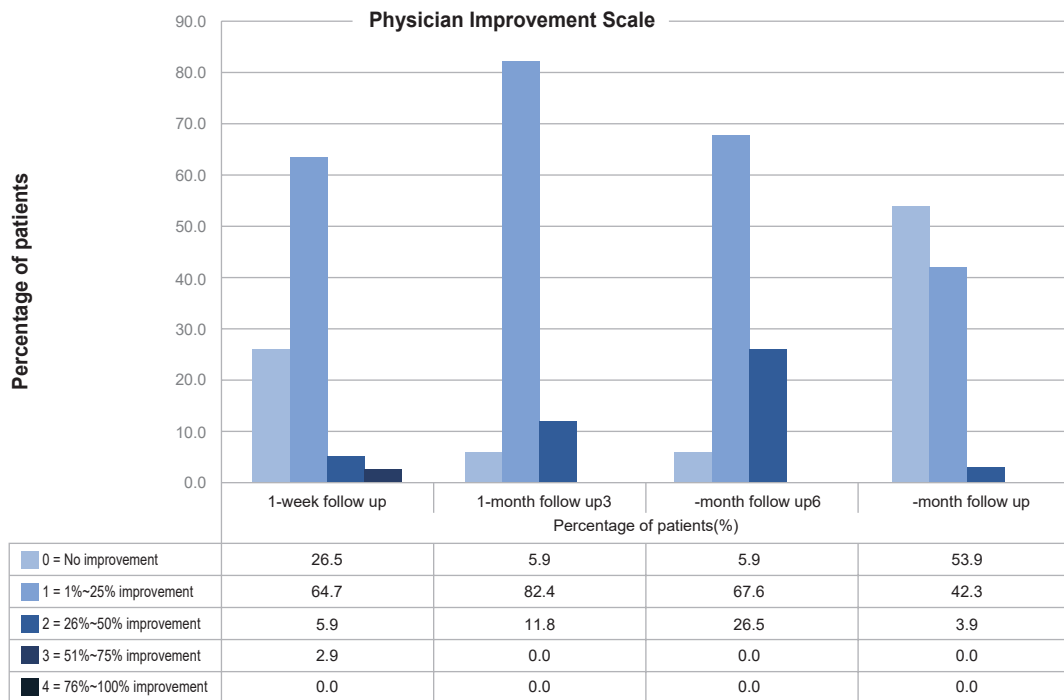


Figure 2 Physicians' evaluation of upper facial laxity by comparative evaluation of photographs from baseline to follow-ups.

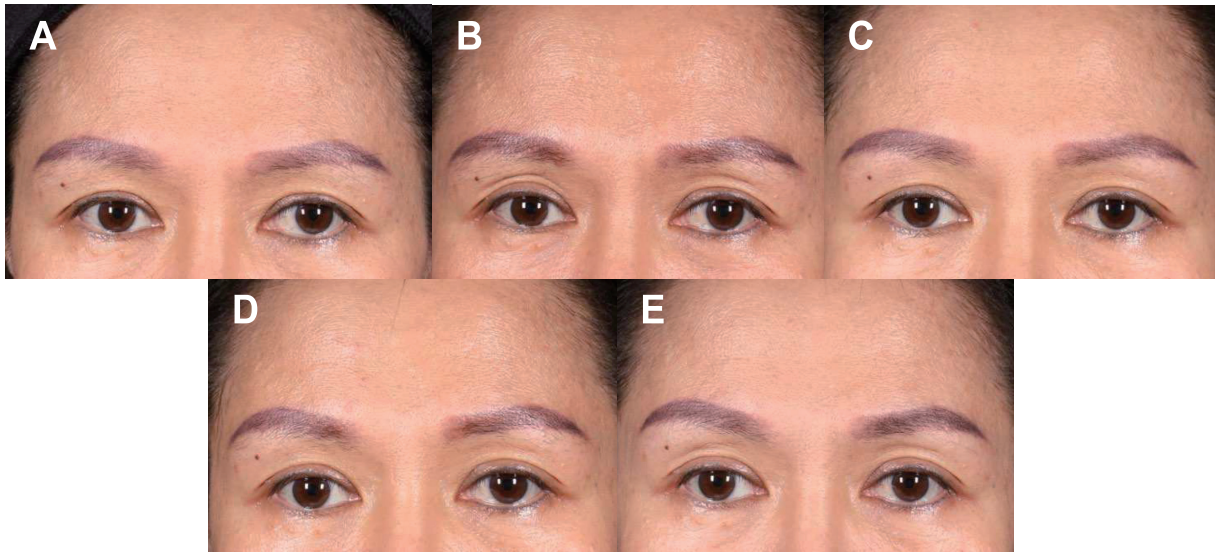

Figure 3 Clinical improvement of upper facial laxity after 1 HIFU treatment from (A) baseline, (B) 1-week follow-up, (C) 1-month follow-up, (D) 3-month follow-up and (E) 6-month follow-up.

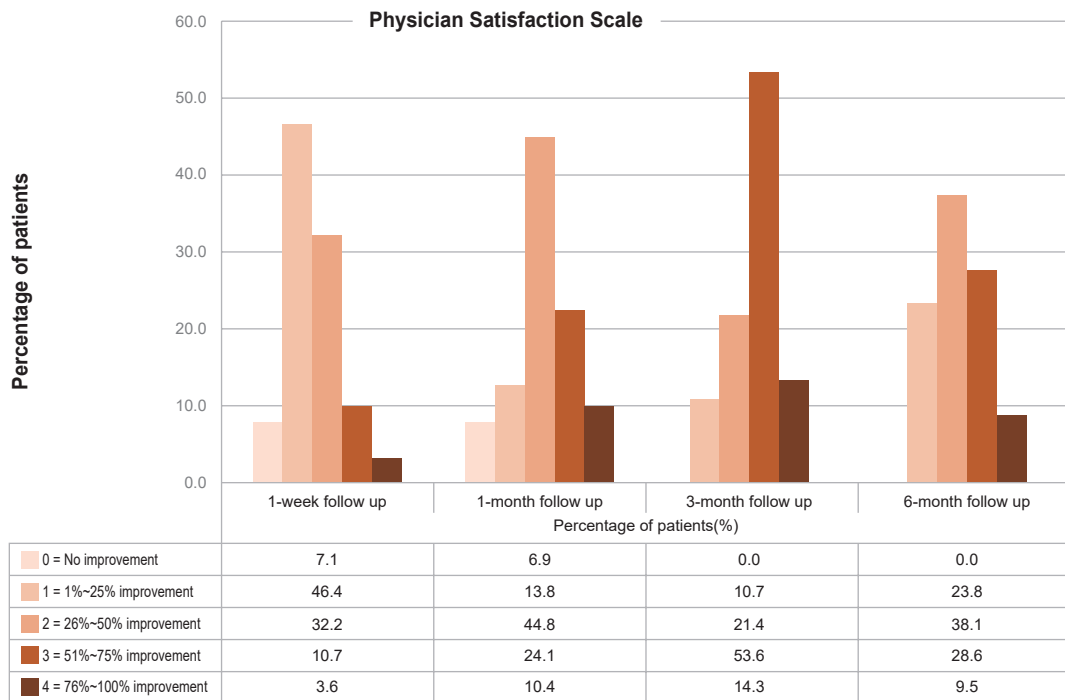


Figure 4 Patients' self-assessment on the improvement of upper facial laxity at baseline and follow-ups.

CONCLUSIONS

The MFU device is a safe and effective treatment for upper facial laxity and skin textural irregularities in Thai patients.

REFERENCES

1. Venkatesh S, Maymone MBC, Vashi NA. Aging in skin of color. *Clin Dermatol*. 2019;37(4):351–357.
2. Vashi NA, de Castro Maymone MB, Kundu RV. Aging Differences in Ethnic Skin. *J Clin Aesthet Dermatol*. 2016;9(1):31–38.
3. Suh DH, Shin MK, Lee SJ, et al. Intense focused ultrasound tightening in Asian skin: clinical and pathologic results. *Dermatol Surg*. 2011;37(11):1595–1602.
4. Wulkan AJ, Fabi SG, Green JB. Microfocused Ultrasound for Facial Photorejuvenation: A Review. *Facial Plast Surg*. 2016;32(3):269–275.
5. Jacono AA, Malone MH, Lavin TJ. Nonsurgical Facial Rejuvenation Procedures in Patients Under 50 Prior to Undergoing Facelift: Habits, Costs, and Results. *Aesthet Surg J*. 2017;37(4):448–453.
6. Bowler PJ. Impact on facial rejuvenation with dermatological preparations. *Clin Interv Aging*. 2009;4:81–89.
7. Lee H, Yoon K, Lee M. Outcome of facial rejuvenation with polydioxanone thread for Asians. *J Cosmet Laser Ther*. 2018;20(3):189–192.
8. Bohluli B, Bagheri SC, Consky EK. Fat Grafting as an Adjunct to Facial Rejuvenation Procedures. *Atlas Oral Maxillofac Surg Clin North Am*. 2018;26(1):51–57.
9. Zhou YF. High intensity focused ultrasound in clinical tumor ablation. *World J Clin Oncol*. 2011;2(1):8–27.
10. Fabi SG. Noninvasive skin tightening: focus on new ultrasound techniques. *Clin Cosmet Investig Dermatol*. 2015;8:47–52.
11. Gutowski KA. Microfocused Ultrasound for Skin Tightening. *Clin Plast Surg*. 2016;43(3):577–582.
12. Sabet-Peyman EJ, Woodward JA. Complications using intense ultrasound therapy to treat deep dermal facial skin and subcutaneous tissues. *Dermatol Surg*. 2014;40(10):1108–1112.
13. Minkis K, Alam M. Ultrasound skin tightening. *Dermatol Clin*. 2014;32(1):71–77.
14. Alam M, White LE, Martin N, Witherspoon J, Yoo S, West DP. Ultrasound tightening of facial and neck skin: a rater-blinded prospective cohort study. *J Am Acad Dermatol*. 2010;62(2):262–9.
15. Lighthall JG. Rejuvenation of the Upper Face and Brow: Neuromodulators and Fillers. *Facial Plast Surg*. 2018;34(2):119–127.
16. Harris MO, Sundaram HA. Safety of Microfocused Ultrasound With Visualization in Patients With Fitzpatrick Skin Phototypes III to VI. *JAMA Facial Plast Surg*. 2015;17(5):355–357.
17. Fabi SG, Goldman MP. Retrospective evaluation of micro-focused ultrasound for lifting and tightening the face and neck. *Dermatol Surg*. 2014;40(5):569–575.
18. Suh DH, Oh YJ, Lee SJ, et al. A intense-focused ultrasound tightening for the treatment of infraorbital laxity. *J Cosmet Laser Ther*. 2012;14(6):290–295.
19. Kerscher M, Nurrisyanti AT, Eiben-Nielson C, Hartmann S, Lambert-Baumann J. Skin physiology and safety of microfocused ultrasound with visualization for improving skin laxity. *Clin Cosmet Investig Dermatol*. 2019;12:71–79.
20. Suh DH, Shin MK, Lee SJ, et al. Intense focused ultrasound tightening in Asian skin: clinical and pathologic results. *Dermatol Surg*. 2011;37(11):1595–1602.
21. Lu PH, Yang CH, Chang YC. Quantitative Analysis of Face and Neck Skin Tightening by Microfocused Ultrasound With Visualization in Asians. *Dermatol Surg*. 2017;43(11):1332–1338.
22. Fabi SG, Few JW, Moinuddin S. Practical Guidance for Optimizing Patient Comfort During Microfocused Ultrasound with Visualization and Improving Patient Satisfaction. *Aesthet Surg J*. 2020;40(2):208–216.
23. Fabi SG. Microfocused ultrasound with visualization for skin tightening and lifting: my experience and a review of the literature. *Dermatol Surg*. 2014;40 Suppl 12:S164–S167.
24. Werschler WP, Werschler PS. Long-term Efficacy of Micro-focused Ultrasound with Visualization for Lifting and Tightening Lax Facial and Neck Skin Using a Customized Vectoring Treatment Method. *J Clin Aesthet Dermatol*. 2016;9(2):27–33



A New Treatment Protocol of Micro-Focused Ultrasound for Lower Eyelid Fat Bulging



Hye Chan Jeon | Do-Yeop Kim | Seon-Pil Jin | Dong Hun Lee

A New Treatment Protocol of Micro-Focused Ultrasound for Lower Eyelid Fat Bulging

Hye Chan Jeon | Do-Yeop Kim | Do-Yeop Kim | Dong Hun Lee

ABSTRACT

Background: Micro-focused ultrasound (MFU) causes tissue tightening by producing thermal injury zones and is used to treat various age-related changes including lower eyelid fat bulging.

Objectives: To investigate the efficacy of a new treatment protocol of MFU for lower eyelid fat bulging.

Materials and Methods: We reviewed the medical records of all patients who began MFU for lower eyelid fat bulging from March 2017 to September 2018. MFU was performed in two steps to tighten the lower eyelid dermis and orbital septum. Data on age, sex, bulging severity, and the number of treatment sessions were obtained. Associations of these variables with treatment response were determined through an ordinal logistic regression analysis.

Results: Among 191 enrolled patients, 119 (62.3%) and 47 (24.6%) achieved fair and good responses, respectively. In the multivariable analysis, multiple treatment sessions (odds ratio [OR] 6.618; 95% confidence interval [CI] 3.242-13.513; $P < 0.001$), moderate bulging (OR 4.328; 95% CI 1.755-10.671; $P = 0.001$), and severe bulging (OR 7.570; 95% CI 2.537-22.585; $P < 0.001$) were associated with greater treatment response. There were no serious adverse events.

Conclusion: The new treatment protocol of MFU is an effective and safe strategy for lower eyelid fat bulging.

KEY WORDS: Eyelids, rejuvenation, skin aging, ultrasonic therapy/methods

INTRODUCTION

As aging progresses, lower eyelid fat bulging becomes prominent because of age-related changes in the soft tissue and bony orbit.[1] One of its major causes is the loosening of the orbital septum that supports orbital fat. Lower blepharoplasty can be performed for correction, but problems such as scarring, long recovery time, and overcorrection might occur. Thus, effective but non-to-minimal invasive methods for managing lower eyelid fat bulging have been required. Recently, non-surgical treatments such as ablative and non-ablative fractional laser, radiofrequency, and micro-focused ultrasound (MFU) have been used.[2, 3, 4, 5]

MFU produces discrete thermal injury zones to targeted areas, which results in shrinkage and tissue tightening.[6] Moreover, it can raise the temperature of the targeted adipose tissue while sparing the surrounding tissue, and no damage to intervening nerves or arterioles was observed within the path of the ultrasound pulse.[7] Given that the power density of the converging ultrasound beam is much lower as it passes through the path above the target point,[8] MFU is believed to be safe when used off-label for orbital fat treatment, and no serious adverse events have been reported in human eyelid studies.[5, 9]

However, when the orbital septum is deeply located,

energy delivery to the orbital septum is limited in the conventional protocol.[5, 9] Also, the shape and location of orbital fat of most patients are not consistent in the supine position compared to the sitting position. In this study, we reported the efficacy of a new two-step protocol of MFU that tightens both lower eyelid dermis and orbital septum for correcting lower eyelid fat bulging.

METHODS

Study Population and Variables

We reviewed the medical records of patients with lower eyelid fat bulging who started MFU at the The Seoul Dermatology Clinic from March 2017 to September 2018. All patients were followed up until we confirmed that no further treatment is needed, until they were lost to follow-up, or until October 15, 2018 (date of scheduled data extraction), whichever arrived earlier. Patients who were lost to follow-up after the first treatment were excluded. Age, sex, and the number of treatment sessions were obtained from the medical records.

Evaluating Bulging Severity and Treatment Results

High-resolution digital photographs taken with a Canon EOS D30 camera (en face; Canon, Lake Success, NY, USA) were used to assess bulging severity and treatment response. Baseline bulging severity was scored from 1 to 5 using photographs taken before initial treatment, with 1 indicating mild bulging and 5 indicating most severe bulging. The severity scores were converted into a single ordinal variable by summing the number of individual scores by 3 independent dermatologists in the mild (3-6), moderate (7-10), and severe (11-15) categories. Treatment response was graded as follows by comparing photographs taken before the initial treatment and at the last visit: grade 0, no improvement; grade 1, <20%; grade 2, 20%-39%; grade 3, 40%-59%; grade 4, 60%-79%; and grade 5, 80%-100%. We also collapsed treatment response grades into a single ordinal variable by summing the number of individual grades by 3 dermatologists in the minimal (0-2), fair (3-5), and good (6 or more) responses. There were no missing data in this study because we had started to take photographs of patients with lower eyelid fat bulging at every visit as of January 2017.

The study protocol was approved by the Institutional Review Board of Korean National Institute for Bioethics Policy (P01-201903-21-001), and the requirement for obtaining informed consent was waived.

Intervention

We used the ULTRAFORMER III, SHURINK MFU device (CLASSYS INC., Seoul, Korea) with three different transducers. The EMLA cream (lidocaine 2.5% and prilocaine 2.5%; Astra Pharmaceutical Products Inc., Westborough, MA, USA) was applied to the treatment site 60 minutes before treatment. After the EMLA cream was wiped off, an ultrasound gel was applied to the skin.

In the first step, MFU was performed on the patients in the supine position using the L7-1.5 transducer (7 MHz, 1.5-mm focal depth) and either the L7-3.0 (7 MHz, 3.0-mm focal depth) or the L4-4.5 transducer (4 MHz, 4.5-mm focal depth) to tighten the lower eyelid dermis and orbital septum. Either the L7-3.0 or the L4-4.5 transducer was used depending on the depth

of the orbital septum, which was measured before treatment using a handheld ultrasound device (UProbe-L5NC, Sonostar Technology Co., Guangzhou, China). To ensure that the orbital septum could be targeted by each shot, we applied proper pressure toward the infraorbital margin with the transducer during the procedure.

Moreover, in the second step, L7-3.0 and L4-4.5 transducers were used in patients in the sitting position to tighten the orbital septum. While the transducer was being used, patients were instructed to open their eyes and look upwards.

The energy per ultrasound pulse used at the first and second steps ranged from 0.10 to 0.20 J and from 0.3 to 0.5 J, respectively. The 25-mm-long exposure lines of ultrasound pulses were delivered parallel to one another with 3-5-mm spacing. Treatment lines were delivered to the skin located 2 mm below the lower eyelid margin to the inferior orbital rim, parallel to the lower eyelid margin. Patients receiving multiple sessions were treated at 3-week intervals.

F-RAY

To attempt a more precise evaluation of bulging severity and treatment response, additional photographs were taken using the F-RAY (BEYOUNG Co., Seoul, Korea). This device creates contour lines using the moiré phenomenon; thus, it is expected to enable more sensitive volume assessment (Fig. 1). Three dermatologists evaluated baseline bulging severity and treatment response with photographs taken with F-RAY in the same way as when evaluating with conventional digital camera photographs.

Statistical Analysis

Ordinal logistic regression analyses were used to evaluate associations between predictive factors and treatment response. Predictive factors showing univariable associations with treatment response ($P < 0.20$) were included in a multivariable ordinal logistic regression model.

Interrater reliability for bulging severity and treatment response scores was assessed using Spearman correlation. Differences in the treatment response evaluation (conventional digital camera vs. F-RAY)

were analyzed with the exact McNemar-Bowker test. All analyses were performed using SPSS statistics software, version 20.0 (SPSS Inc., Chicago, IL, USA). All statistical tests were two-sided and a P-value<0.05 was considered statistically significant.

RESULTS

Patients' Characteristics and Overall Treatment Response

Detailed demographic and clinical characteristics of the patients are presented in Table 1. A total of 191 patients with lower eyelid fat bulging were identified and treated with MFU; of these, 162 (84.8%) were female. Patients' mean age at the time of presentation was 45 (range 20-73) years. The median treatment number per patient was 1 (interquartile range (IQR) 1-2).

The median bulging severity score was 9.0 (IQR 7.0-10.0), and median treatment response score was 4.0 (IQR 3.0-5.0). Overall, when evaluated by photographs taken with the conventional digital camera, 25 (13.1%) have had a minimal response, 119 (62.3%) a fair response, and 47 (24.6%) a good response (Fig. 2). The proportion of patients with good response tended to increase with the number of treatments (Fig. 3).

Variable	All patients (n=191)
Age, mean (range), y	45.3(20.0-73.0)
Sex, n (%)	
Male	29 (15.2)
Female	162 (84.8)
Number of treatment, median (IQR)	1.0 (1.0-2.0)
Bulging severity score*, median (IQR)	9.0 (7.0-10.0)
Treatment response score†, median (IQR)	4.0 (3.0-5.0)
Mild (3-6), moderate (7-10), severe (≥ 11)	
†Minimal (0-2), fair (3-5), good (≥ 6)	
IQR, interquartile range	

TABLE 1 Demographic and clinical characteristics of patients

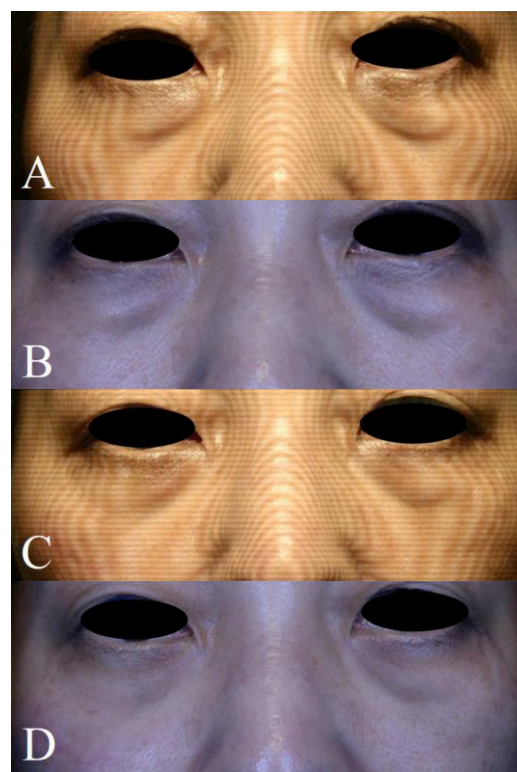


FIGURE 1 Preoperative (A, B) and postoperative (C, D) photographs. (A, C) Photographs taken with F-RAY. Contour lines on skin surface assist volume assessment.

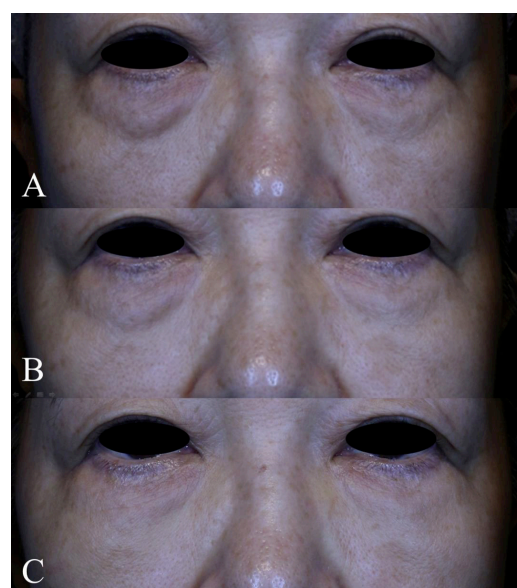


FIGURE 2 Preoperative and postoperative photographs using a conventional digital camera in a patient with a good response. Compared with pretreatment (A), photographs after the third treatment (B) and the seventh treatment (C) show gradual improvement.

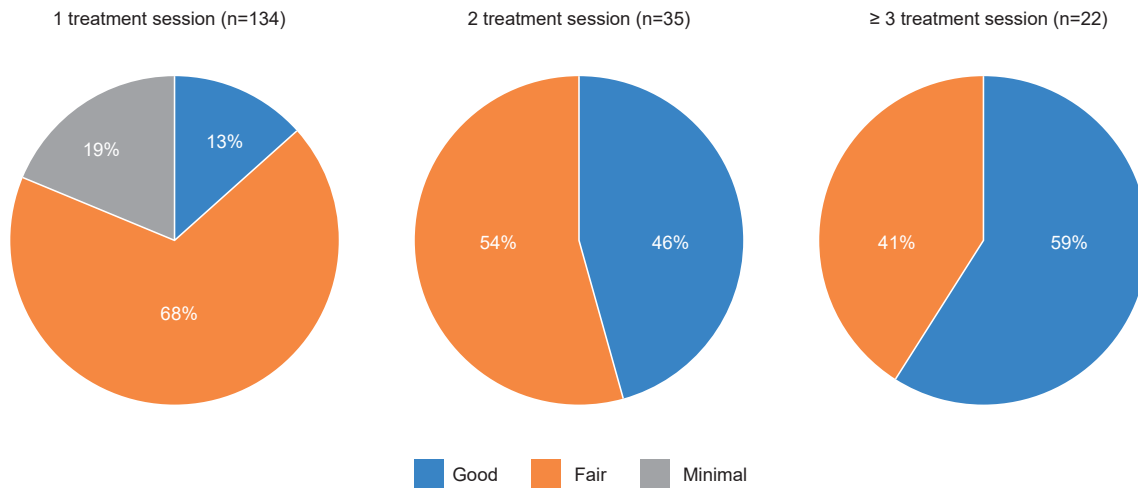


FIGURE 3 Frequency of treatment response depending on the number of treatment sessions.

Association Between Predictive Factors and Treatment Response

As shown in Table 2, the univariable ordinal logistic regression analysis revealed multiple treatment sessions, and more severe lesions were associated with greater treatment response (Table 2). There were no significant differences in the treatment response according to age and sex.

In the multivariable ordinal logistic regression analysis, two variables (treatment number and bulging severity) remained significantly associated with treatment response (Table 2). Multiple treatment sessions were significantly associated with greater treatment response (odds ratio [OR], 6.618; 95% confidence interval [CI] 3.242-13.513; $P < 0.001$). Additionally, patients with moderate or severe lesions showed greater treatment response than patients with mild lesions (OR 4.328; 95% CI 1.755-10.671; $P = 0.001$, and OR 7.570; 95% CI 2.537-22.585; $P < 0.001$, respectively) (Table 2).

The study protocol was approved by the Institutional Review Board of Korean National Institute for Bioethics Policy (P01-201903-21-001), and the requirement for obtaining informed consent was waived.

Comparison of Evaluation by Digital Camera and F-RAY

Average interrater reliability (Spearman) of bulging

severity score and treatment response score evaluated by the conventional digital camera was 0.40 and 0.33, respectively. When evaluating using F-RAY, the average interrater reliability increased to 0.52 ($P = 0.139$) and 0.39 ($P = 0.504$), respectively, which was not significantly different. Figure 4 compares the treatment responses evaluated by a conventional digital camera and F-RAY. There were significantly more fair and good responses evaluated by the F-RAY than by the conventional digital camera ($P = 0.003$). This suggests that a more sensitive and reproducible evaluation has been done when evaluating with F-RAY.

Safety Assessment

The most common adverse events were pain and swelling (reported by approximately half of the patients), which were mild in severity. Other adverse events observed were bruising (reported by 5 patients), nodules (reported by 2 patients), ectropion (reported by 1 patient), and unilateral dacryorrhea (reported by 1 patient). All adverse effects were mild and resolved within 2 weeks. No serious adverse events were reported.

Variable	Univariable analysis			Multivariable analysis			
	Minimal response (n=25)	Fair response (n=119)	Good response (n=47)	OR (95% CI)	P- (Value)	OR (95% CI)	P- (Value)
Age,y, median(IQR)	44.0 (39.0-48.0)	47.0 (36.0-53.0)	49.0 (39.0-54.0)	1.011 (0.984-1.039)	0.418	-	
Sex, n(%)							
Female	22(88.0)	100(84.0)	40(85.1)	Reference 1.081 (0.489-2.390)	0.8	-	
Male	3(12.0)	19(16.0)	7(14.9)		.48		
Treatment number, n(%)							
1	25(100.0)	91(76.5)	18(38.3)	Reference 7.720 (3.627-15.571)	<0.001	Reference 6.618 (3.242-13.513)	<0.001
≥2	0(0)	28(23.5)	29(61.7)				
Bulging severity, n(%)							
Mild	9(36.0)	18(15.1)	0(0)	Reference 5.266 (2.160-12.840)	<0.001	Reference 4.328 (1.755-10.671)	0.001
Moderate	15(60.0)	77(64.7)	32(68.1)	10.711 (3.736-30.734)	<0.001	7.570 (2.537-22.585)	<0.001
Severe	1(4.0)	24(20.2)	15(31.9)				

CI, confidence interval; IQR, interquartile range; OR, odds ratio.

TABLE 2 Univariable and multivariable analysis of treatment response to MFU in lower eyelid laxity (n=191)

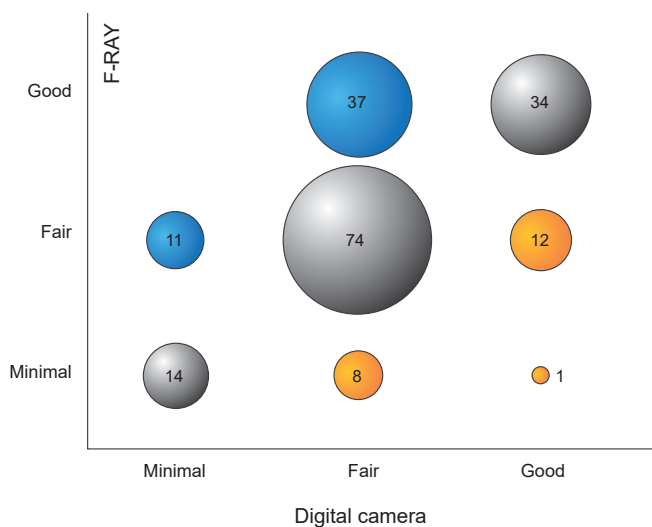


FIGURE 4 Comparison of treatment responses evaluated by conventional digital camera and F-RAY (n=191). Significant asymmetry (P=0.003, Bowker test), i.e. significantly more fair and good responses evaluated by the F-RAY than by the conventional digital camera.

DISCUSSION

This study investigated the efficacy and prognostic factors of a new two-step MFU protocol to tighten the lower eyelid dermis and orbital septum in patients with lower eyelid fat bulging. More than 80% of patients showed a fair or good response after undergoing the treatment with the new MFU protocol. Moreover, we showed that the clinical factors associated with the greater treatment response were multiple treatment sessions and moderate or severe bulging. Age and sex were not associated with the treatment response. In the

first step, we employed a relatively lower energy (0.1-0.2 J) than 0.2-0.45 J from conventional protocols to reduce the risk of untoward side effects, and added the second step using a higher energy (0.3-0.5 J) with a 3.0 mm- or 4.5 mm-focal depth probe for effectively targeting the orbital septum as well as tightening the lower eyelid dermis. Also, looking upwards in the sitting position allows the orbital fat to bulge out so that physicians can treat it more precisely. In studies using conventional protocols of MFU for lower eyelid fat bulging, Suh et al.⁹

reported that 86.7% of patients were considered to have much improved or improved lower eyelid, and Pak et al.⁵ reported an average improvement score of 3.45 and 3.25 on a scale of 0 (no involvement) to 4 (severe). It is difficult to compare the efficacy of the conventional and new treatment protocols directly because the evaluation was carried out 6 months after the single treatment session in previous studies, and the grading scale was different.

When treating the lower eyelid fat bulging with MFU, careful treatment is needed because the therapeutic response varies greatly depending on how precise the orbital septum is targeted.[5] Firstly, the target depth assessment through diagnostic ultrasound should be preceded to select probes for the appropriate treatment depth. During the procedure, the orbital septum becomes shallower as pressure increases; thus, proper pressure should be applied to adjust the target depth. Moreover, the probe should be placed parallel to the lower eyelid margin. If the probe is placed perpendicular to the lower eyelid margin, as Pak et al.⁵ reported, the orbital septum would become deeper. To keep the depth change constant during the procedure on the orbital septum, it would be better to target the part that originates from the orbital rim.

It is also important to stay on the bone when treating the periorbital area, because the ultrasound waves will bypass any protective eye shield and can cause corneal damage.[10, 11] If the MFU is performed toward the inferior orbital rim, eye damage can be avoided without the need for an eye shield. In the second step, corneal damage was prevented by instructing patients to look upwards. Although one additional treatment step has been added, it was well tolerated with an adverse event profile similar to those in previous studies. Meanwhile, high-intensity focused ultrasound in bone metastasis is known to increase skeletal remodeling,[12] and a similar mechanism may contribute to improving lower eyelid fat bulging through the 'hammock effect'.[1]

Diagnostic ultrasound can also be used to distinguish other conditions that can be confused with fat bulging.[13] In dark circles with which the causes other than fat bulging are predominant, the effect of MFU is reduced and it may be better to perform other treatments. For example, treatment with a polynucleotide or hyaluronic

acid can yield satisfactory results in dark circles due to the thin, translucent skin.[14]

We found that the number of treatment sessions was associated with treatment response. Improvement can be more pronounced with a longer observation period because the lipolysis and tightening process can last more than three months after a single session of MFU.[15] However, since the proliferative phase lasts for approximately 21 days in the wound healing process,[16] frequent treatments at 3-week intervals may lead to a rapid improvement.

In this study, more severe bulging led to better clinical outcomes. Although the severe group tended to receive more treatment sessions, the significance was still maintained in the multivariable analysis. In general, mild-to-moderate laxity is considered to be an ideal indication for MFU,[10, 17] but the satisfactory outcome can also be expected in severe cases.

We found that age was not associated with treatment response to MFU. This is consistent with two retrospective chart reviews showing that age was not associated with patient satisfaction after MFU.[18, 19] Although previous studies have reported that younger patients are more likely to have a good outcome, no statistical analysis was performed in these studies.[17, 20]

The evaluation using F-RAY was more sensitive, because the fluctuations of the skin surface can be evaluated more delicately with the aid of contour lines.[21] In addition, this device minimizes ambient light interference by using a blackout curtain and takes standardized photographs at a consistent angle by using cephalostats for the forehead and chin. It is also non-invasive; thus, it will be useful for the precise evaluation without any inconvenience. Our study had several limitations. Similar to other retrospective chart review studies, it is possible that there were unmeasured confounding factors, such as patient compliance. In addition, extent of fat bulging was not quantitatively measured. However, for more reliable results, we combined the scores of three independent dermatologists and also evaluated using F-RAY.

In conclusion, our results suggest that the new treatment protocol of MFU is effective and safe for lower eyelid fat bulging regardless of age and sex. Clinicians could consider additional MFU is effective and safe for

lower eyelid fat bulging regardless of age and sex. Clinicians could consider additional MFU sessions if the improvement is not apparent after the first treatment.

ACKNOWLEDGMENT

We thank the patients who kindly allowed their photographs to be used.

ACKNOWLEDGMENT

The authors report no conflict of interest.

REFERENCES

1. Kim J, Park SW, Choi J, Jeong W, Lee S. Ageing of the bony orbit is a major cause of age-related intraorbital fat herniation. *Journal of Plastic, Reconstructive & Aesthetic Surgery*. 2018;71(5):658-664.
2. Tierney EP, Hanke CW, Watkins L. Treatment of lower eyelid rhytids and laxity with ablative fractionated carbon-dioxide laser resurfacing: Case series and review of the literature. *Journal of the American Academy of Dermatology*. 2011;64(4):730-740.
3. Sukal SA, Chapas AM, Bernstein LJ, Hale EK, Kim KH, Geronemus RG. Eyelid tightening and improved eyelid aperture through nonablative fractional resurfacing. *Dermatologic Surgery*. 2008;34(11):1454-1458.
4. Shin JW, Park JT, Chae JB, Choi JY, Na JI, Park KC, et al. The efficacy of microinsulated needle radiofrequency system for the treatment of lower eyelid fat bulging. *JDDG: Journal der Deutschen Dermatologischen Gesellschaft*. 2019;17(2):149-156.
5. Pak CS, Lee YK, Jeong JH, Kim JH, Seo JD, Heo CY. Safety and efficacy of ulthera in the rejuvenation of aging lower eyelids: a pivotal clinical trial. *Aesthetic plastic surgery*. 2014;38(5):861-868.
6. White WM, Makin IRS, Barthe PG, Slayton MH, Gliklich RE. Selective creation of thermal injury zones in the superficial musculoaponeurotic system using intense ultrasound therapy: a new target for noninvasive facial rejuvenation. *Archives of facial plastic surgery*. 2007;9(1):22-29.
7. Jewell ML, Desilets C, Smoller BR. Evaluation of a novel high-intensity focused ultrasound device: preclinical studies in a porcine model. *Aesthetic surgery journal*. 2011;31(4):429-434.
8. Laubach HJ, Makin IR, Barthe PG, Slayton MH, Manstein D. Intense focused ultrasound: evaluation of a new treatment modality for precise microcoagulation within the skin. *Dermatologic surgery*. 2008;34(5):727-734.
9. Suh D-H, Oh Y-J, Lee S-J, Rho J-H, Song K-Y, Kim N-I, et al. A intense-focused ultrasound tightening for the treatment of infraorbital laxity. *Journal of Cosmetic and Laser Therapy*. 2012 2012/12/01;14(6):290-295.
10. Fabi SG. Noninvasive skin tightening: focus on new ultrasound techniques. *Clinical, cosmetic and investigational dermatology*. 2015;8:47.
11. Jung SK, Yang S-W, Kim MS, Kim EC. Corneal stromal damage through the eyelid after tightening using intense focused ultrasound. *Canadian Journal of Ophthalmology*. 2015;50(4):e54-e57.
12. Bucknor MD, Rieke V, Seo Y, Horvai AE, Hawkins RA, Majumdar S, et al. Bone remodeling after MR imaging-guided high-intensity focused ultrasound ablation: evaluation with MR imaging, CT, Na(18)F-PET, and histopathologic examination in a swine model. *Radiology*. 2015 Feb;274(2):387-94.
13. Friedmann DP, Goldman MP. Dark circles: etiology and management options. *Clinics in plastic surgery*. 2015;42(1):33-50.
14. Park KY, Kwon HJ, Youn CS, Seo SJ, Kim MN. Treatments of Infra-Orbital Dark Circles by Various Etiologies. *Annals of Dermatology*. 2018;30(5):522-528.
15. Alster TS, Tanzi EL. Noninvasive lifting of arm, thigh, and knee skin with transcutaneous intense focused ultrasound. *Dermatologic Surgery*. 2012;38(5):754-759.
16. Reinke J, Sorg H. Wound repair and regeneration. *European surgical research*. 2012;49(1):35-43.
17. Brobst RW, Ferguson M, Perkins SW. Ulthera: initial and six month results. *Facial Plast Surg Clin North Am*. 2012 May;20(2):163-76, vi.
18. Fabi SG, Goldman MP. Retrospective evaluation of micro-focused ultrasound for lifting and tightening the face and neck. *Dermatol Surg*. 2014 May;40(5):569-75.
19. Chang YC, Croix J, Javvaji S, Hernandez S, Chapas AM, MacGregor J. Patient satisfaction and our clinical experience with 459 microfocused ultrasound treatments. *Lasers Surg Med*. 2019 Jan 21.
20. MacGregor JL, Tanzi EL. Microfocused ultrasound for skin tightening. *Semin Cutan Med Surg*. 2013 Mar;32(1):18-25.
21. Saito N, Nishijima T, Fujimura T, Moriwaki S, Takema Y. Development of a new evaluation method for cheek sagging using a Moire 3D analysis system. *Skin Research and Technology*. 2008;14(3):287-292.



High-Intensity Focused Ultrasound: A Satisfactory,
Non-invasive Procedure for Crow's Feet Wrinkles



Gyu Sik Jung¹ | In Kook Cho² | Hyung Min Sung³

High-Intensity Focused Ultrasound: A Satisfactory, Non-invasive Procedure for Crow's Feet Wrinkles

Gyu Sik Jung¹ | In Kook Cho² | Hyung Min Sung³

¹GLAD Plastic Surgery Clinic, Daegu, Korea

²Lavian Plastic Surgery Clinic, Seoul, Korea

³V Plastic Surgery Clinic, Daegu, Korea

Correspondence

Gyu Sik Jung

GLAD Plastic Surgery Clinic, 31 Dongsung-ro 5-gil, Jung-gu, Daegu 41941, Korea

Tel.: +82-53-710-0103

Fax: +82-53-710-0133

E-mail: jksheart@naver.com

© Korean Society for Laser Medicine and Surgery

© This is an open access article distributed under the terms of the Creative Commons Attribution Non-Commercial License (<http://creativecommons.org/licenses/by-nc/4.0>) which permits unrestricted non-commercial use, distribution, and reproduction in any medium, provided the original work is properly cited.

Background and Objectives: High-intensity focused ultrasound (HIFU) has been developed as an effective, non-invasive, skin-tightening method in response to the increasing demand for improvements in skin laxity and tightening with minimal risk and recovery time. This study evaluated the efficacy and safety of HIFU for non-invasive skin tightening of crow's feet wrinkles, with the aim of determining how long the tightening can be maintained.

Materials and Methods: Between January and March 2019, 21 female patients with crow's feet wrinkles were treated with HIFU. The treatment involved 200 shots, three times every 2 weeks. Three blinded, experienced plastic surgeons and patients evaluated satisfaction at 2 weeks after the first procedure, 2 weeks after the second procedure, 2 weeks after the third procedure, and 6 weeks after the first procedure based on photographs according to the Global Aesthetic Improvement Scale (GAIS). The Friedman test was used to compare data.

Results: Of the 21 patients treated using HIFU, one was lost to follow-up for non-study-related reasons. Therefore, 20 patients were evaluated and ranged in age from 28 to 48 years. Plastic surgeons' GAIS scores were 2.6, 2.3, 1.7, and 1.3 and patients' GAIS scores were 2.6, 2.2, 1.8, and 1.4 at 2 weeks after the first procedure, 2 weeks after the second procedure, 2 weeks after the third procedure, and 6 weeks after the third procedure. No serious adverse effects were observed.

Conclusion: The aging face with crow's feet wrinkles can be improved by using HIFU, while minimizing epidermal and dermal injury.

KEY WORDS: Skin aging; High-intensity focused ultrasound therapy; Skin wrinkling

1. INTRODUCTION

Crow's feet wrinkles are characterized as laugh lines around the lateral aspect of the eyes. Static fine wrinkles around the eyes and dynamic wrinkles caused by movement of the orbicularis oculi muscle develop with aging. Non-invasive skin tightening is superior to invasive or surgical skin tightening in terms of rapid return to work, short recovery time, and low risk of adverse events. Because of these advantages, patients who desire a skin-tightening procedure prefer non-invasive skin tightening to invasive or surgical skin tightening.¹

To meet patients' demand for non-invasive skin tightening, numerous devices besides the popular botulinum toxin procedure have been developed. Specifically, laser and radiofrequency devices have been developed to resolve skin wrinkling. Botulinum toxin treatment has a disadvantage in that it causes an awkward expression by reducing movement of the eyes. Recently, high-

intensity focused ultrasound (HIFU) was developed as an effective non-invasive skin-tightening method. HIFU is able to heat tissue to greater than 60°C and produce a small thermal coagulation zone to reach the mid- to deep reticular layers of the dermis and subdermis while minimizing overlying papillary dermal and epidermal injury. The delivery of HIFU to a targeted zone in the superficial musculoaponeurotic system (SMAS) provokes the immediate contracture of denatured collagen, and initiation of neocollagenesis and collagen remodeling. This action of HIFU provokes non-invasive skin tightening and lifting of sagging facial skin.

However, certain factors including a lack of efficacy, persistence, and reliability have limited its replacement of invasive surgical procedures.^{2,3} The purposes of this study were to evaluate the efficacy and safety of HIFU for crow's feet wrinkles, and to determine how long the tightening of crow's feet wrinkles can be maintained.

2. MATERIALS AND METHODS

Between January and March 2019, 21 patients with crow's feet wrinkles were treated with HIFU (I-SHURINK[®]; Classys Inc., Seoul, Korea; Fig. 1) using 5.5-MHz, 2-mm depth transducers (I-SHURINK MF2). Treatment was performed by the same surgeon and involved 200 shots, three times every 2 weeks. Informed consent was obtained from all patients, and the study was performed according to the Helsinki Declaration.

The exclusion criteria were cervicofacial, neurologic, or vascular facial disease; pregnancy or breastfeeding; local skin diseases that might alter wound healing; history of psychiatric illness, soft tissue augmentation material, cardiopathy, diabetes, facial or neck skin conditions, facial surgery; receipt of an antiaging procedure in the preceding 6 months; and active systemic or local infections.

Procedure

Ten percent lidocaine, as a topical anesthetic ointment (EMLA, AstraZeneca, Sdertlje, Sweden), was applied to the periocular area for 30 minutes before the procedure. The ointment was washed off with mild soap and water immediately before the procedure. Then ultrasound gel was applied to the periocular area, and the transducer was placed firmly on the targeted skin surface and pressed uniformly to ensure complete contact with the skin. Treatment exposure was initiated (2-mm depth transducers; 0.4 J/mm²), with a line of individual ultrasound pulses being delivered within approximately 2 seconds. Then, the transducer was slid to the next location and repositioned 2-mm laterally such that it was adjacent and parallel to the previous treatment line. Complete treatment of the face required 10 to 15 minutes. The ultrasound gel was washed off. Patients experienced mild redness and swelling that could persist for several days.

Measurement

We compared the preoperative and postoperative measurements with the Global Aesthetic Improvement Scale (GAIS) at 2 weeks after the first procedure, 2 weeks after the second procedure, 2 weeks after the third procedure, and 6 weeks after the third procedure.

Each scoring sheet was independently assessed by 3 blinded, experienced evaluators (3 plastic surgeons), and the plastic surgeons and patients' scores were compared.

Statistical analysis

The Friedman test was used to compare the scores of patients at pre-treatment, and at 2 and 4 months after treatment. A p-value < 0.05 was considered statistically significant. Statistical analyses were performed using SPSS, version 20.0 (IBM Corp., Armonk, NY, USA).

3. RESULTS

All patients were treated using HIFU, and 1 patient was lost to follow-up for non-study-related reasons. Therefore, in our study, 20 female patients were evaluated and ranged in age from 28 to 48 years. There was no case of edema or erythema, linear striations, hypopigmentation, hyperpigmentation, ulceration, and erosion. There were also no adverse events, such as nerve or muscle dysfunction, severe pain, bruising, and bleeding.

Plastic surgeons' GAIS scores were 2.6, 2.3, 1.7, and 1.3 and patients' GAIS scores were 2.6, 2.2, 1.8, and 1.4



Figure 1 High-intensity focused ultrasound (I-SHURINK[®]).

at 2 weeks after the first procedure, 2 weeks after the second procedure, 2 weeks after the third procedure, and 6 weeks after the third procedure. No serious adverse effects were observed during the 6-month follow-up period (Table 1, Fig. 2, 3).

4. DISCUSSION

HIFU burns tissue using high heat (65-100°C) at the focus where high-intensity ultrasound emergency is collected in one place. If you focus ultrasound energy at about 100,000 times stronger than the intensity of the ultrasonic wave used for diagnosis, heat is generated at the focus area. This is similar to a convex lens, which collects sunlight and generates heat at the focus area. The ultrasonic energy itself is harmless to the human body and generates heat only at the focus where the ultrasound energy is concentrated, so plastic surgeons can treat the lesion without the need for general anesthesia or use of a knife or needle.^{4,5}

In order to minimize post-treatment adverse events, clinicians have developed various non-invasive skin-tightening procedures to induce collagen shrinkage and remodeling. Furthermore, ultrasonography is able to penetrate into the subdermal layer and SMAS, and induce thermal coagulation to avoid undesired post-treatment adverse events compared with carbon dioxide laser resurfacing.³

Ultrasound energy has characteristics that are suitable for skin lifting and tightening. First, it is believed that ultrasound energy can be transmitted into the deeper subcutaneous layer of the face or even the SMAS, and it is the most effective method for skin lifting and tightening. Second, both the epidermis and dermis can be protected from ultrasound energy during its transmission, reducing the risk of adverting cutaneous layers.⁵

TABLE 1 Global Aesthetic Improvement Scale (GAIS)

	2 weeks after first procedure	2 weeks after second procedure	2 weeks after third procedure	6 weeks after first procedure
Plastic surgeons' GAIS scores	2.6	2.3	1.7	1.3
Patients' GAIS scores	2.6	2.2	1.8	1.4

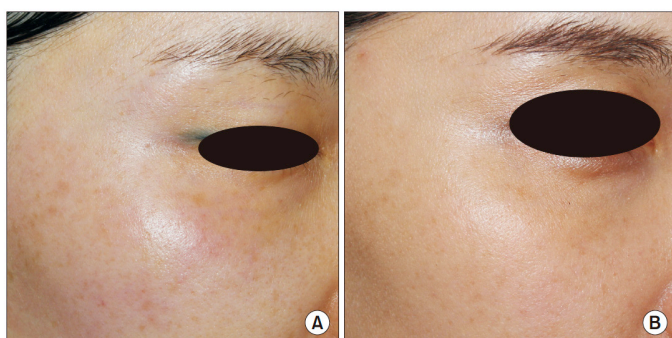


FIGURE 2 Photographs of a 33-year-old woman. (A) Preoperative image. (B) Photograph after all three treatment sessions.

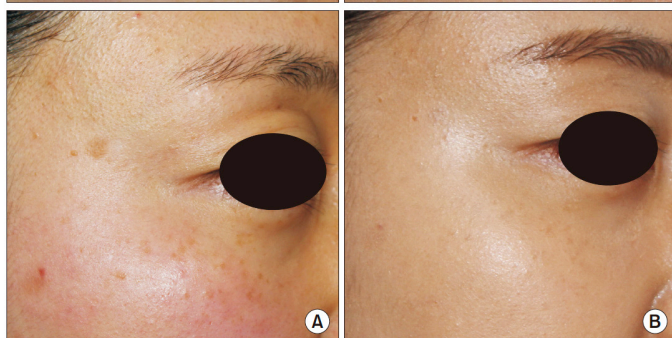


FIGURE 3 Photographs of a 37-year-old woman. (A) Preoperative photo-graph. (B) Photograph after three treatment sessions.

HIFU uses high energy and is mainly used for non-surgical ablation of tumors. HIFU can also be used to ablate adipose tissue for body contouring. Micro-focused ultra-sonography (MFU) uses much lower energy to treat the superficial layer of the skin and is able to elevate the local temperature higher than 60°C to cause collagen contracture. When energy is targeted to discrete areas within the dermal and subdermal tissues, MFU induces discrete thermal coagulation zones while sparing adjacent non-target tissues. Additionally, the heat induces denaturation and contraction of collagen fibers in the subcutaneous fat layer.^{6,7}

There is one more thing to watch out for when performing HIFU on the eye. Ask the patient to look at the opposite side of the procedure site. Have your eyes look down when you are working on your eyes, and when you are working under your eyes. The wrinkles on the surface of the skin of the site are also expanded, which

makes it easier to perform the procedure, and even if the skin is deeply mistaken, the probability of reaching the eyeball surface is reduced.⁸

When HIFU is irradiated to the curved area around the eyes, blistering may occur when the skin is not 100% contacted. Make sure that it is exactly 90° and that one side of the cartridge does not float with your skin. In this case, an elevated striation may occur.

5. CONCLUSIONS


This study suggests that the aging face, with wrinkling and sagging, can be improved by HIFU, while minimizing injury to the epidermis and dermis. In addition, re-treatment is recommended at 3 months later to maintain the efficacy of the results.

5. CONFLICT OF INTEREST


The authors declare no conflicts of interest.

REFERENCES

1. Jung NY, Rachmilevitch I, Sibiger O, Amar T, Zadicario E, Chang JW. Factors related to successful energy transmission of fo-cused ultrasound through a skull : a study in human cadavers and its comparison with clinical experiences. *J Korean Neurosurg Soc* 2019;62:712-22.
2. Aşiran Serdar Z, Aktaş Karabay E, Tatlıparmak A, Aksoy B. Efficacy of high-intensity focused ultrasound in facial and neck rejuvenation. *J Cosmet Dermatol*. In press 2019.
3. Azuelos A, SidAhmed-Mezi M, La Padula S, Aboud C, Menin-gaud JP, Hersant B. High-intensity focused ultrasound: a satisfactory noninvasive procedure for neck rejuvenation. *Aesthet Surg J* 2019;39:NP343-51.
4. Katz B, Bard R, Goldfarb R, Shiloh A, Kenolova D. Ultrasound assessment of subcutaneous abdominal fat thickness after treatments with a high-intensity focused electromagnetic field device: a multicenter study. *Dermatol Surg* 2019;45:1542-8.
5. Kim SH, Lee SJ, Kim HJ, Lee JH, Jeong HS, Suh IS. Aging-related changes in the mid-face skin elasticity in East Asian women. *Arch Craniofac Surg* 2019;20:158-63.
6. Erkiert-Polguj A, Algiert-Zielinska B, Zdunska K, Markiewicz A, Skubalski J, Rotsztejn H. The evaluation of elasticity after nonablative radiofrequency rejuvenation. *J Cosmet Dermatol* 2019;18:511-6.
7. Fischer TC, Gauglitz GG. Nonsurgical facial rejuvenation. *Facial Plast Surg* 2016;32:243-4.
8. Chilukuri S, Lupton J. "Deep heating" noninvasive skin tightening devices: review of effectiveness and patient satisfaction. *J Drugs Dermatol* 2017;16:1262-6.



A study of efficacy and safety of high-intensity focused
ultrasound for the treatment of melasma in Asians:
A single-blinded, randomized, split-face, pilot study



Vasanop Vachiramon MD¹ | Wimolsiri Iamsumang MD, MSc¹ | Nongsak Chanasumon
MD, MSc¹ | Kunlawat Thadanipon MD^{1,2} | Korn Triyankulsri MD¹ |

A study of efficacy and safety of high-intensity focused ultrasound for the treatment of melasma in Asians: A single-blinded, randomized, split-face, pilot study

Vasanop Vachiramon MD¹ | Wimolsiri Iamsumang MD, MSc¹ | Nongsak Chanasumon MD, MSc¹
| Kunlawat Thadanipon MD^{1,2} | Korn Triyangkulsri MD¹

¹Division of Dermatology, Faculty of Medicine Ramathibodi Hospital, Mahidol University, Bangkok, Thailand

²Section for Clinical Epidemiology and Biostatistics, Faculty of Medicine Ramathibodi Hospital, Mahidol University, Bangkok, Thailand

Correspondence

Vasanop Vachiramon, Division of Dermatology, Faculty of Medicine Ramathibodi Hospital, Mahidol University, 270 Rama VI road, Rajthevi, Bangkok 10400, Thailand.
Email: vasanop@gmail.com

ABSTRACT

Background: A recent report suggested potential of high-intensity focused ultrasound in improving UVB-induced hyperpigmentation in patients with Fitzpatrick skin type IV, but reports regarding its efficacy in other hyper-pigmented conditions including melasma are lacking.

Objectives: To investigate efficacy and safety of high-intensity focused ultrasound for the treatment of melasma in Asians.

Methods: Each side of the face of 25 melasma patients was randomized to receive 3-monthly sessions of high-intensity focused ultrasound treatment or serve as control. Lightness index, Melasma Area and Severity Index of malar area (MASI_m) by blinded dermatologists, self-evaluated improvement and satisfaction scales by patients, and side effects were assessed every 4 weeks for 20 weeks.

Results: Twenty-one patients with Fitzpatrick skin type III and IV completed the study. There was a greater reduction of relative lightness index and MASIm after treatment in high-intensity focused ultrasound-treated side. However, there were no statistically significant differences between both sides. More than 50% improvement on treatment side was rated in 11 patients (52.4%). Side effects were minimal. None had worsening of melasma.

Conclusion: High-intensity focused ultrasound may be an adjuvant for treatment of melasma. Further studies with larger sample size and proper parameter settings are recommended to determine its efficacy.

KEY WORDS: chloasma, hyperpigmentation, laser, melasma, pigmentary disorder

1. INTRODUCTION

Melasma is a common acquired pigmentary disorder seen worldwide especially in those living in ultraviolet-intense areas. It is characterized by light brown to dark, muddy brown macules, and patches on the face, typically on the forehead, malar prominences, and chin. In terms of pathogenesis, melasma is thought to be a result of the presence of functionally active melanocytes in the lesions rather than an increase in melanocyte number. To classify melasma by its locations, 3 clinical patterns have been described, namely a centro-facial pattern, which is the most common, a malar pattern, and a mandibular pattern. Although biologically benign, this condition has significant negative impact on patient's psychological health and quality of life.¹ Melasma is relatively difficult to deal with; however, it has been traditionally managed with a combination of

photo-protection, avoidance of triggers, and topical medications with variable success rate. Laser therapy showed varying improvement and some reported a potential of worsening.² Therefore, newer topical agents, lasers, and energy-based devices have been introduced as promising options for treatment, particularly in difficult-to-treat patients.

High-intensity focused ultrasound (HIFU) has been utilized as a therapeutic device for the treatment of solid benign and malignant tumors.³ In dermatological practice, it has been introduced as a non-invasive option for skin tightening and rejuvenation. The mechanism of HIFU involves delivery of high-frequency ultrasound underneath the skin and induction of precise thermal damage to specific depth under the skin. These then result in dermal collagen regeneration, and contraction of the superficial muscular aponeurotic

system without epidermal or adjacent tissue injury. Recently, Choi et al⁴ demonstrated positive effects of HIFU in ultraviolet B-induced hyper-pigmentation in guinea pig skin by applying HIFU via a 1.5-mm transducer. They also proposed that HIFU has a mechanical destructive activity in eliminating melanin from the epidermis and upper dermis. According to a recent study, the efficacy and safety of HIFU for UVB-induced hyperpigmentation in human subjects with Fitzpatrick (FPT) skin type III or IV were demonstrated. The results revealed greater improvement in lightness index as well as in improvement score in participants with skin type IV compared to controls while HIFU showed inferior efficacy for both parameters in skin type III to controls.⁵ To our knowledge, a clinical study regarding the efficacy and safety of HIFU in treating melasma has not been published in the literature. Therefore, we aim to determine the efficacy and safety of HIFU in the treatment of melasma, particularly in Asians.

2. MATERIALS AND METHODS

2.1 Study design

This is a split-face, evaluator-blinded, randomized controlled trial. The objective was to investigate the efficacy and safety of HIFU in the treatment of melasma. The study was approved by the Faculty of Medicine Ramathibodi Hospital Institutional Review

Board of Human Rights Related to Research Involving Human Subjects, Mahidol University (protocol number 026026). The study protocol complied with the guidelines of the Declaration of Helsinki. Information on the study procedures, benefit, and potential risk was given to the patients before enrolling in the study. All patients provided informed consent before participating in the study.

2.2 Patients

Twenty-five participants aged over 18 years old with mixed-type melasma in both malar areas were recruited from the dermatology out-patient clinic at a university-based hospital (Ramathibodi Hospital, Mahidol University, Bangkok, Thailand). Participants were excluded if they had pregnancy or lactation, medical or dermatologic conditions including autoimmune disorders, scars, or severe cystic acne on the face, a history of photosensitive disorders, allergy to topical hydroquinone, or a previous history of the following treatments or procedures: oral contraceptive pills or hormone replacement therapy within 1 year, topical whitening agents within 3 months, laser treatment including HIFU treatment within 6 months, or filler injection on the experimental sites within 1 year.

2.3 Treatment and follow-up

All eligible participants were randomly allocated to

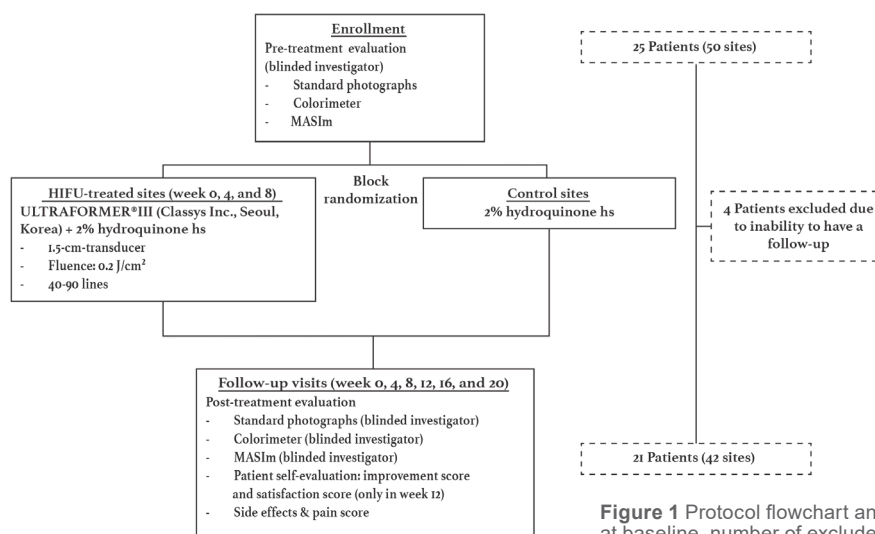


Figure 1 Protocol flowchart and number of the participants at baseline, number of excluded participants, and number of participants included in the statistical analyses

receive the treatment of HIFU on one side of the face based on a computer-generated random sequence, while the contralateral side served as control. The face was cleaned with a gentle cleanser before the treatment. Standard digital photographs (Visia CR, Canfield Imaging System) were taken from the front as well as both sides of the face. The HIFU treatment (ULTRAFORMER® III, Classys Inc) was performed with a fluence of 0.2 J/cm² via a 7-MHz, 1.5 mm transducer, fluence 0.2 J/cm² in 3 consecutive sessions at baseline, 4th, and 8th week. Lubricating gel (K-Y Jelly™, Johnson & Johnson) was applied to the treated areas prior to HIFU therapy. Forty to ninety lines of HIFU were delivered without overlap in 2 passes, each with either a horizontal or vertical orientation, until the endpoint of mild erythema was seen. All participants were requested to apply a 2% hydroquinone gel bilaterally before bedtime as well as a broad-spectrum sunscreen with a sun protection factor (SPF) of 50+ and protection grade of UVA (PA) of more than eight (PA+++). They were also instructed to avoid direct sun exposure, concomitant use of any other topical medications, and vigorous rubbing on the treated areas during the study period. After the last treatment, the participants were followed up every 4 weeks for 3 times, giving a total of 6 visits. The study protocol is shown in Figure 1.

2.4 Outcome evaluation

Objective assessment was performed at each visit

Characteristics	n = 21
Gender	
Male, n (%)	3 (14.3)
Female, n (%)	18 (85.7)
Age (y); mean (SD)	46.3 (7.7)
Fitzpatrick skin type	
Type III, n (%)	11 (52.4)
Type IV, n (%)	10 (47.6)
Disease duration (y); median (range)	6.5 (1-30)
Baseline R*LI	
HIFU-treated sites (mean ± SD)	7.19 ± 2.67
Control sites (mean ± SD)	7.66 ± 2.72
Baseline mMASI	
HIFU-treated sites (mean ± SD)	15.33 ± 5.91
Control sites (mean ± SD)	15.00 ± 6.19

TABLE 1 Demographic data and baseline R*LI and mMAS

using colorimeter (DSM II ColorMeter®, Cortex Technology). Lightness index (L*I) was obtained by the average of three measurements taken from the darkest areas of melasma and from normal skin on both sides of the face. Reproducibility was achieved by using a transparent plastic map indicating the same measured target. The difference in L*I between normal skin and lesion was calculated and represented as a relative lightness index RL*I.

Relative lightness index

$$(RL * I) = L * I \text{ of normal skin} - L * I \text{ of melasma}$$

The severity of melasma was also subjectively evaluated in terms of Melasma Area and Severity Index on the malar area (MASI_m) by 2-blinded dermatologists at baseline and every visit. MASI_m was scored and calculated based on the following parameters: percentage of involvement or "A" ranging from 0 to 6 (0 = 0%, 1 = <10%, 2 = 10%-29%, 3 = 30%-49%, 4 = 50%-69%, 5 = 70%-89%, 6 = 90%-100%), darkness of pigment or "D" ranging from 0 to 4 (0 = absent or normal skin color without evidence of hyperpigmentation, 1 = slight visible hyperpigmentation, 2 = mild visible hyperpigmentation, 3 = marked hyperpigmentation, 4 = severe), and homogeneity or density of hyperpigmentation (number of pigmented lesions per unit facial area) or "H" ranging from 0 to 4 (0 = minimal, 1 = slight, 2 = mild, 3 = marked, 4 = severe).

$$MASI_m = (D+H) \times A$$

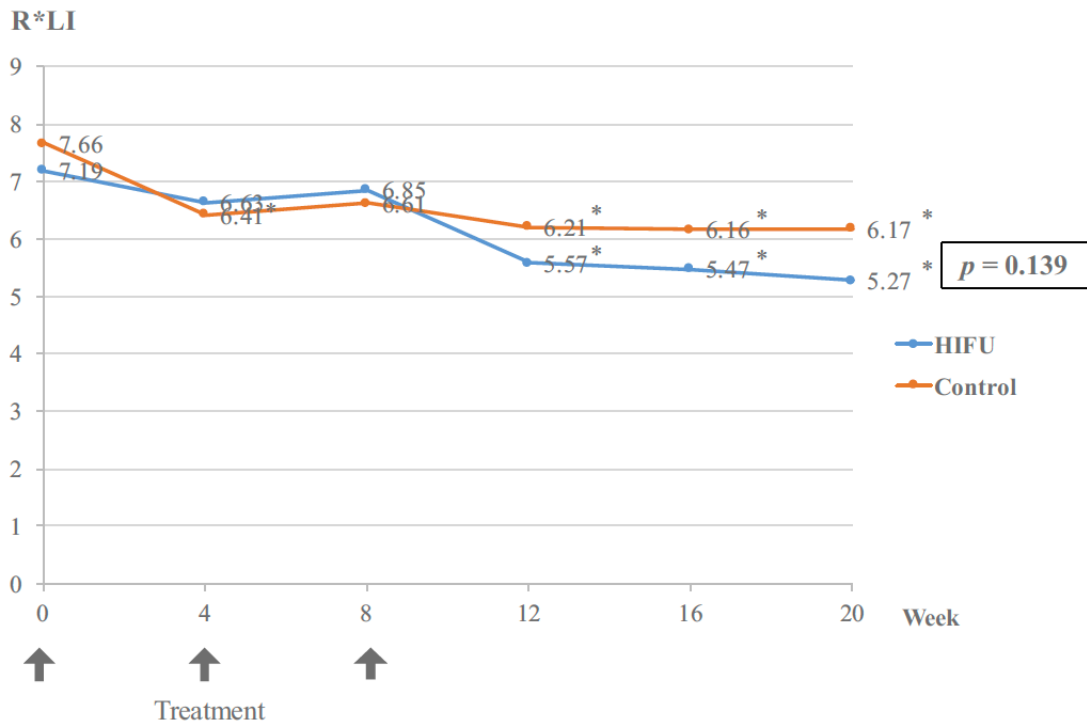


FIGURE 2 Mean relative lightness index (RL*) of HIFU-treated side in comparison with control side (*significant reduction compared with baseline $P < 0.05$)

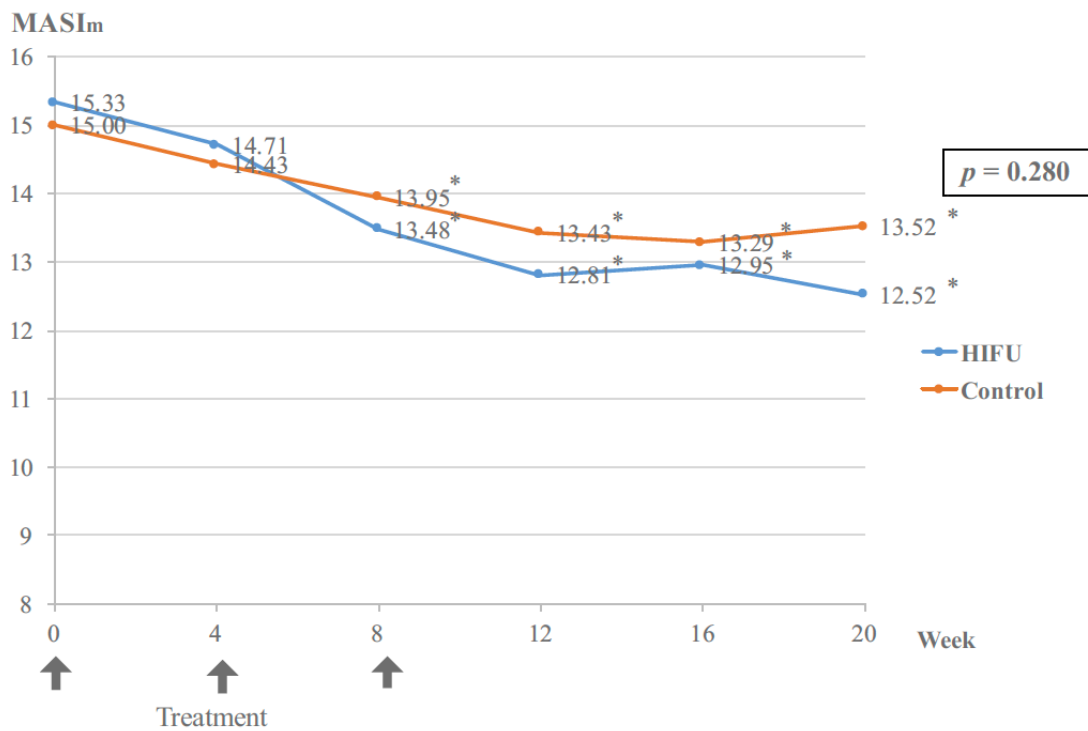


FIGURE 3 Mean Melasma Area and Severity Index of the malar area (MASI_m) of HIFU-treated side compared with control side (*significant reduction compared with baseline $P < 0.05$)

At the 4th visit, improvement score was rated by participants according to the following scale: excellent = 90%-100% improvement, good = 60%-89% improvement, fair = 30%-59% improvement, poor = 0%-29% improvement, or worsening. Satisfaction score was also assessed in all participants by using a numerical scale, ranging from 0 point (very dissatisfied) to 10 points (very satisfied).

Regarding safety, pain score was also noted by using a numerical scale ranging from 0 to 10 with 0 as no pain and 10 as the most severe pain. Adverse effects were assessed by dermatologists at every visit.

2.5 Recurrence

At the final visit, recurrence which is defined as increment in RL*I or MASI_m more than 50% from the 4th visit was assessed and reported in percentage.

2.6 Statistical analyses

Statistical analyses were performed using Stata/SE version 14.2 (StataCorp, College Station, TX). Categorical variables were presented as percentages while continuous variables (e.g. RL*I, MASI_m, pain score, satisfaction score) were presented in terms of mean \pm standard deviation. Patient grading of improvement was calculated in percentage. The effects of treatment in terms of mean RL*I and mean MASI_m, together with the effects of Fitzpatrick skin type, were determined using multilevel mixed-effects linear regression analysis. A P-value of 0.05 or less was considered statistically significant.

3. RESULTS

Demographic data are summarized in Table 1. Twenty-five patients were enrolled in the study. Four participants dropped out from the study after the 4th-week (1 patient), 8th-week (1 patient), 12th-week (1 patient), and 16th-week visit (1 patient) due to inability to follow-up. Twenty-one participants completed the protocol and were included in the statistical analyses. Eighteen participants were female (85.7%), while 3 participants were male (14.3%). Their age ranged from 30 to 56 years, with a mean of 46.3 years. Eleven participants had Fitzpatrick skin type III (52.4%), whereas 10 had skin type IV (47.6%). There were no statistically

significant differences in terms of mean RL*I or mean MASI_m between the HIFU-treated and control sides at baseline.

3.1 Color measurement

Mean RL*I at each visit is demonstrated in Figure 2. On the HIFU-treated side, the mean RL*I decreased from 7.19 ± 2.67 at baseline to 5.57 ± 2.91 at 4 weeks after the last HIFU treatment (12th week), accounting for 22.5% reduction. This decrease reached statistical significance ($P = 0.006$). Mean RL*I of the treated side was further slightly reduced to 5.47 ± 2.52 and 5.27 ± 2.7 at the 16th and 20th week, respectively ($P = 0.004$ and $P = 0.001$). Likewise, the mean RL*I of the control side significantly declined from 7.66 ± 0.47 to 6.21 ± 2.83 at the 4th visit, representing 18.9% reduction ($P = 0.014$) (Figure 2). The mean RL*I also significantly decreased from baseline to 6.16 ± 2.75 and 6.17 ± 3.74 at the 16th and 20th week ($P = 0.011$ and 0.012), respectively. There were no statistically significant differences in terms of overall mean RL*I between HIFU-treated and control sides ($P = 0.139$). There was no significant impact of different skin types on RL*I ($P = 0.189$).

3.2 MASI_m

The mean MASI_m before treatment was 15.33 ± 5.91 and 13.43 ± 6.1 for the HIFU treated and control sides, respectively. After the HIFU treatment, there was a statistically significant decrease in MASI_m to 12.81 ± 6.79 on the treated side ($P < 0.001$), accounting for 16.4% reduction. At the 16th and 20th week, there was also a significant reduction of mean MASI_m to 12.95 ± 6.67 and 12.52 ± 6.91 , respectively ($P < 0.001$). On the control side, the mean MASI_m significantly reduced from 15.00 ± 6.19 to 13.43 ± 6.10 , representing 10.5% reduction ($P = 0.002$) (Figure 3). The control side also showed a significant decline in MASI_m to 13.29 ± 6.17 and to 13.52 ± 6.22 at the 15th and 20th week ($P = 0.001$ and 0.003 , respectively). However, the overall differences of mean MASI_m between the HIFU-treated and control sides did not reach the statistical significance level ($P = 0.280$) (Figure 3). Skin type did not appear to significantly affect MASI_m in the present study ($P = 0.408$).

3.3 Patient self-assessment and satisfaction score

Ten participants (47.6%) rated improvement of melasma on the HIFU-treated side as “good” or “51%-75% improvement” (Table 2). One participants (4.8%) scored excellent improvement, while “fair” and “poor” were rated by 7 (33.3%) and 3 (14.3%), respectively. On the control side, most patients (14 patients, 66.7%) rated as “fair” and 5 patients (23.8%) rated as “poor.” No patients on both groups reported worsening of melasma. The mean satisfaction score evaluated by the participants at the 4th visit was 6.62 ± 1.60 , ranging from 4 to 10. Photographs of patients before and after treatment are shown in Figures 4 and 5.

3.4 Recurrence

Adhering to the definition of recurrence with more than 50% increase in RL*1 or MAS_{1m}, no case of recurrence was found at 3 months after the last treatment (Figures 2 and 3).

3.5 Safety assessment

The median pain score was 2 (range: 0-7). Side effects are listed in Table 3. One patient experienced burning sensation that subsided within 1-2 days without treatment. Two patients had adverse events from topical hydroquinone on both sides of the face including scaling (1 patient) and erythema (1 patient) which both spontaneously resolved without treatment or cessation of hydroquinone application (Table 3). No participants experienced PIH or worsening of melasma in this study.

4. DISCUSSION

Melasma is a common dermatologic condition that predominantly occurs in Fitzpatrick skin types III and IV.¹ Given its significant impact on patient's quality of life and psychological well-being, various treatment modalities including topical treatment, chemical

peels, as well as laser and light treatment, have been described.² Nonetheless, dealing with melasma remains a problematic issue since topical treatment shows varying degrees of therapeutic success while laser therapy provides unpredictable improvement with potentials of worsening.³ Seeking alternative options for melasma especially in recalcitrant or darkly pigmented patients is challenging.

High-intensity focused ultrasound is an innovative technology recently used in the management of skin laxity and rejuvenation. It delivers high-frequency ultrasound to specific layers of the skin and creates thermally induced contraction of collagen and tissue coagulation at the temperature up to 70°C while preserving the epidermis. This subsequently causes tissue repair cascade including collagenesis and elastogenesis that helps improve laxity in aging skin.^{6,7} In 2015, Harris et al investigated HIFU application in 52 patients with skin types III to VI and proved that HIFU was safe and effective in darker-skinned patients without pigmentary adverse events.⁸ Previous experimental study conducted by Choi et al reported potentials of HIFU in ultraviolet B (UVB)-induced hyperpigmentation using an animal model. HIFU irradiation with 1.5 cm depth transducer at 0.1 and 0.2 J/cm² was applied to UVB-induced hyper-pigmented areas of guinea pig skin.⁴ Macroscopic improvement of pigmentation was observed at 2 weeks and at 3 weeks after HIFU with 0.2 J/cm² and with 0.1 J/cm², respectively. Reduction in UVB-induced melanin deposition was also seen in histopathology at 3 weeks after HIFU application. The proposed mechanism was mechanical destructive effects which play an important role in elimination of hyper-pigmentation. More recently, a study in humans suggested that HIFU may be offered in some patients with UVB-induced hyper-pigmentation. A superior efficacy of HIFU in the treatment of UV-

Improvement (%)	HIFU-treated side, n = 21 (%)	Control side, n = 21 (%)
Excellent (75-100)	1 (4.80)	0
Good (51-75)	10 (47.62)	2 (9.52)
Fair (26-50)	7 (33.33)	14 (66.67)
Poor (0-25)	3 (14.29)	5 (23.81)
Worsening	0	0

TABLE 2 Patient self-assessment for melasma improvement on HIFU-treated side and control side

induced hyper-pigmentation in skin type IV was observed when compared to controls, but not in skin type III participants.⁵

The present study was conducted in order to evaluate the efficacy and safety of HIFU in the treatment of melasma in Asians. The results revealed that HIFU-treated side attained greater reduction of mean RL*I after 3 sessions of treatment when compared to controls. Similar findings were observed in changes of mean MASI_m. After treatment, mean RL*I and mean mMASI significantly decreased from baseline in both sides. However, no statistically significant differences between two groups were detected. No patients suffered from worsening of melasma condition. In terms of patients' assessment, approximately half of the participants rated the improvement as more than 50% on HIFU-treated side, whereas the majority gave a 26%-50% improvement rating on the control side. The findings highlighted some positive effects of HIFU for the treatment of melasma. This can be supported by the proposed mechanism that HIFU induced vibration and friction, with consequent mechanical destructive effects which further eliminate melanin and pigmented debris from the epidermis and upper dermis.⁴ Considering the previous report, HIFU seems to provide more favorable outcome in skin type IV than type III.⁵ Nevertheless, skin type did not significantly affect the outcome of melasma either evaluated by RL*I or MASI_m in this study. According to the study by Choi et al,⁴ clinically favorable improvement in hyperpigmentation was observed as soon as 2-3 weeks after HIFU treatment. We thus hypothesize that 4-week-interval treatment could be relatively too long, and shorter treatment interval and/or higher number of HIFU sessions may yield more apparent effects.

In terms of side effects, pain was generally tolerable without local anesthesia. Only 1 patient reported burning sensation after HIFU treatment which was transient and subsided without treatment. Other side effects including scaling and erythema were considered to be related to hydroquinone, because they were not only present on HIFU-treated side but also on the control side. Interestingly, no worsening of melasma or post-inflammatory hyper-pigmentation was reported in our study. Given the fact that radiofrequency devices

carry potential risk of PIH,^{9,10} we propose that HIFU can be a better option for patients with skin laxity who have concurrent melasma.

The main limitation of the present study is small sample size that might have prevented us from detecting a statistically significant difference between the HIFU treatment and control. We also lacked participants with skin types other than type III and type IV. Thus, our findings may not be applicable to all skin types. Additionally, we might have suffered from some bias regarding patient's self-evaluation because the participants were not blinded to the treatment. Larger numbers of participants, a greater variety of skin types, double-blinding, and appropriate treatment intervals are therefore recommended for future studies on the clinical efficacy of HIFU in melasma. In addition, more studies of HIFU regarding treatment of various hyper-pigmented conditions beyond melasma should also be undertaken to indicate other potential indications.

In conclusion, HIFU may be an adjuvant in the treatment of melasma. However, both cost and effectiveness of HIFU should be taken into account. Further studies are warranted to indicate its efficacy.

Side effects	n = 21 (%)
Device-related side effects	
Burning sensation	1 (4.76)
Medication-related side effects	
Scaling	1 (4.76)
Erythema	1 (4.76)

TABLE 2 Side effect

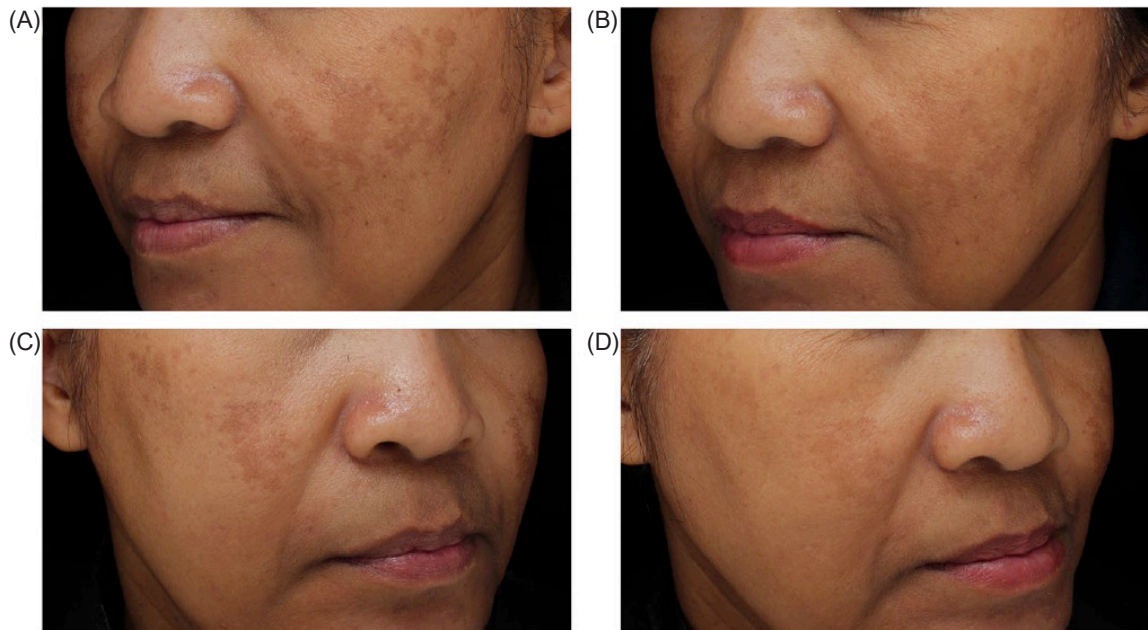


FIGURE 4 Photographs of patient with melasma. (A) Control side at baseline, (B) control side at 12th week, (C) HIFU-treated side at baseline, and (D) HIFU-treated side at 12th week

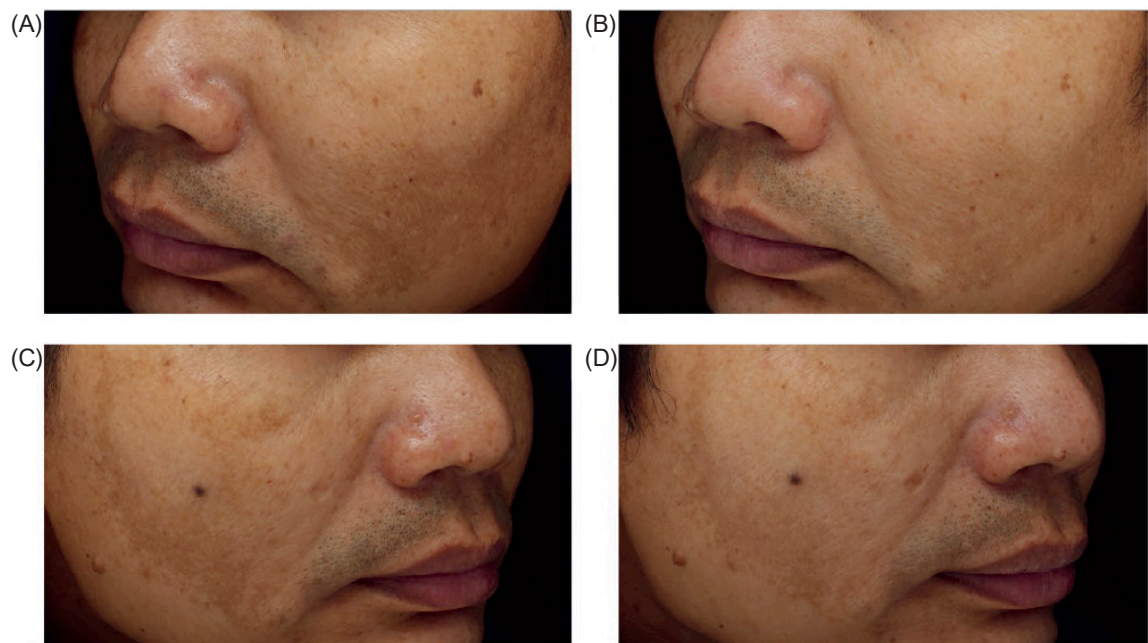


FIGURE 5 Photographs of patient with melasma. (A) HIFU-treated side at baseline, (B) HIFU-treated side at 12th week, (C) control side at baseline, and (D) control side at 12th week

ACKNOWLEDGMENT

We thank Dr. Poonkiat Suchonwanit for his help in preparation of the illustration.

CONFLICT OF INTEREST

The authors declare no conflict of interest.

ORCID

Vasanop Vachiramon <https://orcid.org/0000-0002-7328-939X>

REFERENCES

1. Sheth VM, Pandya AG. Melasma: a comprehensive update: part I. *J Am Acad Dermatol*. 2011;65(4):689-697.
2. Sheth VM, Pandya AG. Melasma: a comprehensive update: part II. *J Am Acad Dermatol*. 2011;65(4):699-714.
3. Laubach HJ, Makin IR, Barthe PG, Slayton MH, Manstein D. Intense focused ultrasound: evaluation of a new treatment modality for precise microcoagulation within the skin. *Dermatol Surg*. 2008;34(5):727-734.
4. Choi SY, Yoo KH, Oh CT, et al. High intensity focused ultrasound as a potential new modality for the treatment of pigmentary skin disorder. *Skin Res Technol*. 2016;22(2):131-136.
5. Vachiramon V, Jurairattanaporn N, Harnchoowong S, Chayavichitsilp P. Non-invasive high-intensity focused ultrasound for UV-induced hyperpigmentation in Fitzpatrick skin types III and IV: a prospective, randomized, controlled, evaluator-blinded trial. *Lasers Med Sci*. 2018;33(2):361-367.
6. Gutowski KA. Microfocused ultrasound for skin tightening. *Clin Plast Surg*. 2016;43(3):577-582.
7. Minkis K, Alam M. Ultrasound skin tightening. *Dermatol Clin*. 2014;32(1):71-77.
8. Harris MO, Sundaram H. Safety of microfocused ultrasound with visualization in patients with Fitzpatrick skin phototypes III to VI. *JAMA Facial Plast Surg*. 2015;17:355-357.
9. Phothong W, Wanitphakdeedecha R, Sathaworawong A, Manuskiatti W. High versus moderate energy use of bipolar fractional radiofrequency in the treatment of acne scars: a split-face double-blinded randomized control trial pilot study. *Lasers Med Sci*. 2016;31(2):229-234.
10. Lee SJ, Kim JI, Yang YJ, Nam JH, Kim WS. Treatment of periorbital wrinkles with a novel fractional radiofrequency microneedle system in dark-skinned patients. *Dermatol Surg*. 2015;41(5):615-622.

How to cite this article: Vachiramon V, Iamsung W, Chanasumon N, Thadanipon K, Triyangkulsri K. A study of efficacy and safety of high-intensity focused ultrasound for the treatment of melasma in Asians: A single-blinded, randomized, split-face, pilot study. *J Cosmet Dermatol*. 2019;00:1-7. <https://doi.org/10.1111/jocd.13044>



Effect of High-Intensity Focused Ultrasound on
Eyebrow Lifting in Asians



Won Jong Oh | Hyun Jung Kwon | Sun Young Choi¹
Kwang Ho Yoo² | Kui Young Park | Beom Joon Kim

Effect of High-Intensity Focused Ultrasound on Eyebrow Lifting in Asians

Won Jong Oh et al. | South Korea

Won Jong Oh | Hyun Jung Kwon | Sun Young Choi¹ | Kwang Ho Yoo² | Kui Young Park | Beom Joon Kim

Department of Dermatology, Chung-Ang University College of Medicine, ¹Department of Dermatology, Inje University Seoul Paik Hospital, Inje University College of Medicine, Seoul, ²Department of Dermatology, Catholic Kwandong University International St. Mary's Hospital, Incheon, Korea

Dear Editor :

As skin aging progresses, the elasticity of the skin decreases and facial wrinkles are commonly seen. Various treatment modalities have been applied to treat wrinkles, yet patients are seeking more effective non-invasive methods with lower risk and minimal downtime. High-intensity focused ultrasound (HIFU) technology, originally used in cancer treatment to destroy cancer cells has emerged as an effective, non-surgical, tissue-tightening procedure. There are several reported results for face, neck, and body tightening with the HIFU device. However, there are few clinical trials that objectively present the efficacy and safety of application of HIFU to the forehead in Asian people. A total of 30 Asian patients (25 females and 5 males) were enrolled in the study. Study approval was granted by the Chung-Ang University Hospital Institutional Review Boards (C2013149[1109]). We received the patient's consent form about publishing all photographic materials. All patients were treated with HIFU device (Ultraformer; Classys Inc., Seoul, Korea) with a 7-MHz, 3-mm transducer to the forehead. Local anesthetic was applied to the target region. Depending on the width of the forehead, the HIFU device was applied along 9 to 11 vertical lines (Fig. 1). Each line consisted of 10 shots at an interval of about 5 mm. After

application of ultrasound transmission gel, the HIFU probe was accurately placed with equal pressure to connect to the skin surface. Ultrasound imaging functionality was used to check whether the probe acoustically connected to the skin tissue for treatment and whether the depth of focus was geometrically on the reticular dermis at an intermediate depth. For treatment, 90~110 shots of ultrasound exposure were applied along the lines, and irradiation was performed for 2 seconds or more per ultrasonic pulse. Ultrasonic exposure in the forehead region took about 5 to 10 minutes in total. Before treatment, 4 weeks, and 12 weeks after treatment, standardized photographs of front and side views, rating scale values of pain, adverse events, physical findings, and patient satisfaction were recorded. We measured average eyebrow height (AEH) and maximum eyebrow height

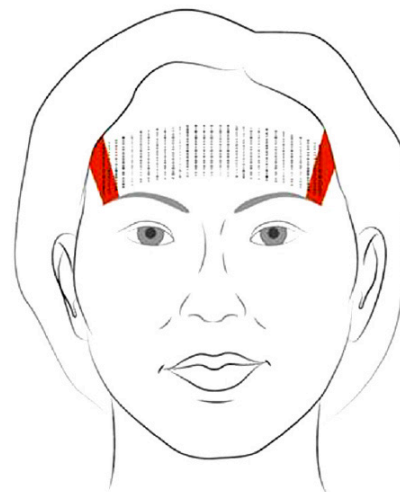


Fig. 1. Diagram showing proper distribution of line placement in the treatment region. Danger zones over the relative locations of the temporal branch of trigeminal nerves are highlighted in red.

Received August 4, 2017, Revised February 1, 2018, Accepted for publication February 28, 2018

Corresponding author: Beom Joon Kim, Department of Dermatology, Chung-Ang University Hospital, 102 Heukseok-ro, Dongjak-gu, Seoul 06973, Korea. Tel: 82-2-6299-1525, Fax: 82-2-823-1049, E-mail: beomjoon@unitel.co.kr ORCID: <https://orcid.org/0000-0003-2320-7621>

This is an Open Access article distributed under the terms of the Creative Commons Attribution Non-Commercial License (<http://creativecommons.org/licenses/by-nc/4.0>) which permits unrestricted non-commercial use, distribution, and reproduction in any medium, provided the original work is properly cited. Copyright © The Korean Dermatological Association and The Korean Society for Investigative Dermatology

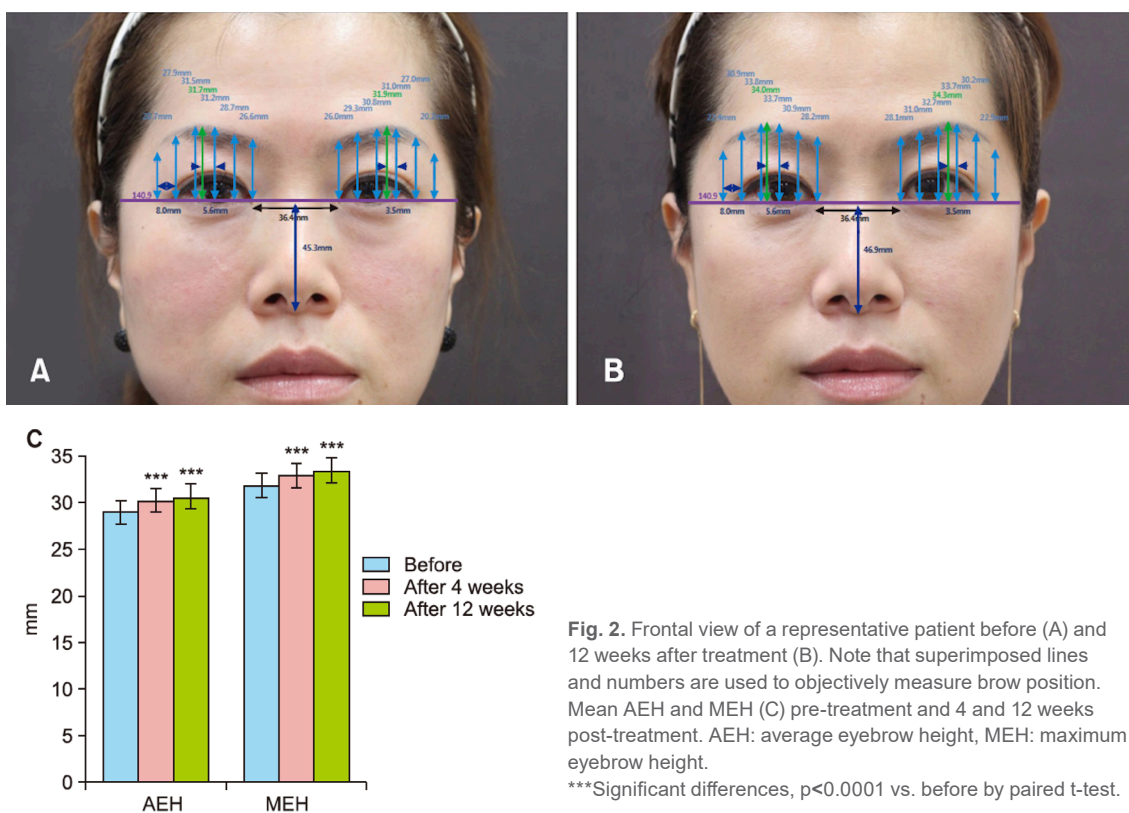


Fig. 2. Frontal view of a representative patient before (A) and 12 weeks after treatment (B). Note that superimposed lines and numbers are used to objectively measure brow position. Mean AEH and MEH (C) pre-treatment and 4 and 12 weeks post-treatment. AEH: average eyebrow height, MEH: maximum eyebrow height. ***Significant differences, $p < 0.0001$ vs. before by paired t-test.

(MEH) of the patients. Both medial canthi were connected on images of the facial region seen from the front. On the medial canthi connection line, five points were assigned incrementally at intervals of 8 mm from the inside of the eye and the distance to the top of the eyebrow from each point was measured. The calculated average of the measured values was taken as the AEH, and the maximum distance from the medial canthi connection to the eyebrow was taken as the MEH (Fig. 2). Patients also rated their pain according to a visual analog scale (VAS). All adverse events, including local ones in the facial region, were included in a safety evaluation, and were recorded in the case report form and abnormalities were evaluated.

After application of the HIFU device, mean values of AEH and MEH significantly and progressively increased at 4 weeks and 12 weeks post-treatment compared with 0 weeks ($p < 0.0001$). Mean AEH immediately after treatment (visit 1), at week 4 (visit 2) and week 12 (visit 3) were 29.08 ± 3.17 mm, 30.22 ± 3.24 mm and 30.64 ± 3.28 mm, respectively. The difference in mean AEH from baseline was 1.14 ± 0.29 mm at week 4 (visit

2–visit 1) and 1.56 ± 0.30 mm at week 12 (visit 3–visit 1); both changes were significant ($p < 0.0001$) (Fig. 2). Mean MEH immediately after treatment (visit 1), at week 4 (visit 2) and week 12 (visit 3) were 31.98 ± 3.40 mm, 33.04 ± 3.49 mm and 33.46 ± 3.50 mm, respectively. The difference in the mean MEH from baseline was 1.06 ± 0.34 mm at week 4 (visit 2–visit 1; $p < 0.0001$), and 1.48 ± 0.36 mm at week 12 (visit 3–visit 1; $p < 0.0001$) (Fig. 2). Immediately after treatment the mean VAS score for pain was 7.57 ± 1.59 , but no pain was reported at weeks 4 and 12. No permanent adverse effects were observed during the follow-up period. Skin tightening by delivery of non-ablative energy offers the promise of reduction of wrinkles and sagging with minimal downtime and no serious adverse events². Collagen is the primary protein in the dermis, together with subcutaneous fat septae and the superficial musculo-aponeurotic system (SMAS). Ultrasound energy has specific characteristics that may increase its suitability for skin tightening. First, it is widely believed that energy delivery to the deeper subcutaneous layers of the face, or even the SMAS, is most effective in inducing skin tightening³.

Furthermore, to the extent that this delivery can be divorced from secondary scatter and absorption in the epidermis and dermis, the risk of inadvertent cutaneous injury can be reduced. Besides ionizing radiation, ultrasound is the only type of inducible energy that can be delivered arbitrarily deeply into tissue in a selective manner⁴. Quantification of improved skin elasticity after treatment in a purely objective manner would be of great benefit for skin tightening procedures. As there is a limitation in scientific objectivity for subjective visual assessment from photographic documentation, eyebrow height was assessed using a standard measurement technique^{5,6}. In this study, to ensure uniform assessment of change in eyebrow elevation, we used AEH and MEH.

Several studies have reported that HIFU resulted in an improvement of facial laxity. Alam et al.² have reported that a single ultrasound treatment of the forehead produced average brow height elevation of 1.7 to 1.9 mm. Suh et al.⁴ have showed that 61.5% of eyebrows were lifted by at least 0.5 mm at 6 months. Compared with results of the above studies, our study demonstrated significant improvement of forehead

skin laxity. In conclusion, we suggest that HIFU would be useful for lax eyelid conditions such as ptosis, as it had a positive effect on eyebrow lifting in Asian people. Future studies could use intense ultrasound probes focused deeper into the tissue to achieve greater tightening efficacy. Higher resolution diagnostic ultrasound imaging would provide better intraoperative visualization of the facial tissue layers, thus facilitating precise treatment and giving better results for skin laxity. Further studies are planned in the field of skin tightening, wrinkle improvement, and skin lifting on other sites of the face.

CONFLICTS OF INTEREST

The authors have nothing to disclose.

ORCID

Won Jong Oh, <https://orcid.org/0000-0001-5201-7849>

Hyun Jung Kwon, <https://orcid.org/0000-0001-8376-2358>

Sun Young Choi, <https://orcid.org/0000-0003-0248-7708>

Kwang Ho Yoo, <https://orcid.org/0000-0002-0137-6849>

Kui Young Park, <https://orcid.org/0000-0001-5965-1754>

Beom Joon Kim, <https://orcid.org/0000-0003-2320-7621>

REFERENCES

1. Laubach HJ, Makin IR, Barthe PG, Slayton MH, Manstein D. Intense focused ultrasound: evaluation of a new treatment modality for precise microcoagulation within the skin. *Dermatol Surg* 2008;34:727-734.
2. Alam M, White LE, Martin N, Witherspoon J, Yoo S, West DP. Ultrasound tightening of facial and neck skin: a rater-blinded prospective cohort study. *J Am Acad Dermatol* 2010;62:262-269.
3. Har-Shai Y, Bodner SR, Egozy-Golan D, Lindenbaum ES, Ben-Izhak O, Mitz V, et al. Mechanical properties and microstructure of the superficial musculoaponeurotic system. *Plast Reconstr Surg* 1996;98:59-70; discussion 71-73.
4. Suh DH, Oh YJ, Lee SJ, Rho JH, Song KY, Kim NI, et al. A intense-focused ultrasound tightening for the treatment of infraorbital laxity. *J Cosmet Laser Ther* 2012;14:290-295.
5. Fitzpatrick R, Geronemus R, Goldberg D, Kaminer M, Kilmer S, Ruiz-Esparza J. Multicenter study of noninvasive radiofrequency for periorbital tissue tightening. *Lasers Surg Med* 2003;33:232-242.
6. Nahm WK, Su TT, Rotunda AM, Moy RL. Objective changes in brow position, superior palpebral crease, peak angle of the eyebrow, and jowl surface area after volumetric radio-frequency treatments to half of the face. *Dermatol Surg* 2004;30:922-928; discussion 928.



Non-invasive Arm Fat Reduction



Logan William Thomas, Margit Juhasz, Lance Chapman, Michele Van Hal,
Ruzica Conic¹, Ashley Magovern², Natasha Mesinkovska

Note: This article introduces new approaches for non-invasive procedures of the upper arm contouring including Low Level Laser Therapy, radiofrequency, high intensity focused ultrasound, radiofrequency, cryolipolysis to review those modalities and its efficacy. And the part of this article content is extracted as shown below.

© 2018 Journal of Dermatology and Dermatologic Surgery | Published by Wolters Kluwer - Medknow

Non-invasive Arm Fat Reduction

Logan William Thomas, Margit Juhasz, Lance Chapman, Michele Van Hal, Ruzica Conic, Ashley Magovern, Natasha Mesinkovska | USA

ABSTRACT

The demand for new approaches for non-invasive procedures of the upper arm is increasing. This review will present the most recent literature addressing modalities for arm fat reduction. Thirteen papers met inclusion criteria. The greatest arm circumference reduction (2.75 cm) is accomplished with the combination of cryolipolysis and shock therapy. Limited side effects are noted with each treatment modality. The most painful treatment is cryolipolysis. Physicians should be aware of the most common treatment modalities, new advances in devices, and possible side effects that may occur. There is a need to design and implement a universal patient satisfaction scale, such as the Global Aesthetic Improvement Scale. We recommend a standard approach to fat reduction measurement using three-dimensional imaging and suggest using US at a standardized location such as the midpoint between the olecranon and acromion processes. Although preliminary research suggests that non-invasive contouring of the upper arm is successful with limited adverse events, further research in this field will need to be completed to determine the long-term safety.

Key words: Arm contouring, cryolipolysis, high intensity focused ultrasound, low-level laser therapy, radiofrequency

INTRODUCTION

Societal views on the perfect body aesthetic have associated slimness with beauty; arm fat impacts how individuals perceive self-beauty and negatively impacts self-confidence.^[1] Traditional approaches to arm fat refractory life style modifications include invasive surgical procedures such as liposuction [Figure 1], carrying risks such as post anesthesia adverse events, hospitalization, and prolonged post operative recovery;^[2] the incidence of minor wound complications is 6.3%, and major morbidity is 6.8% 30 days after liposuction.^[3] Non-invasive approaches to body contouring have become popular, with the development of novel devices and protocols. In a plastic surgery report from 2015, cosmetic surgical procedures have decreased by 10% since 2000, while minimally invasive procedures have increased by 158%.^[4] Minimally invasive

approaches have reduced concern for severe side effects and complications such as scarring, decreased procedural discomfort and allowed faster recovery. Arm contouring is currently in demand with many approaches having been studied, and devices yielding promising results in the reduction of adipose tissue. In this review, we discuss evidence of non-invasive devices for arm contouring, including low level laser therapy (LLLT), high-intensity focused ultrasound (HIFU), radiofrequency (RF), and cryolipolysis.

HIFU (High-intensity Focused Ultrasound)

HIFU uses ultrasonic waves and negative acoustic pressure to achieve results. Focusing acoustic energy at a singular point causes cell membrane disruption, cavitation bubbles, and acoustic energy is transformed into heat with temperatures 57°C.^[19,20] Maintaining temperatures at a specific tissue depth, leads to adipose cell death and coagulative necrosis.^[21] Histopathology demonstrates fat necrosis with multicellular inflammatory infiltrates and foreign body giant cells; 4–5-month post treatment 95% of adipocytes are destroyed.^[19,20] Fortunately, surrounding tissue is unaffected. After adipocyte death, FFAs, inflammatory markers, and chemotactic factors are released, recruiting macrophages 3–4-day post-treatment; after 14–20 days, macrophages engulf and metabolize remaining cellular components. Inflammation and healing may take up to 90 days, with a clear reduction in subcutaneous fat on histology.^[21,23] Three papers were identified using HIFU to tighten arm and/or elbow skin [Table 2]. Choi et al. describe the Ultraformer® III, Shurink (Classys Inc., Seoul, Korea) on six females, Asian patients. Using a Global Aesthetic Improvement Scale (GAIS) (-3–3 with -3 = very much worse and 3 = very much improved) investigators and individuals rated 100% “improvement” and at least an “improved,” respectively, 4 weeks’ post-treatment. Pain was ranked 5.17 ± 2.48 out of 10 (with 10 being the worst) immediately post procedure; no pain was noted at follow-up.^[24] Rokhsar et al. demonstrate HIFU tightening skin over the elbow in 20 female patients. Physicians and patients noted a 94% and 81% improvement at follow-up, respectively. The mean pain score was 5.7 out of 10.^[25]



Efficacy of High Intensity Focused Ultrasound
(HIFU) for Lifting and Tightening Lax Facial &
Neck Skin



Sharmila Nayak

Efficacy of High Intensity Focused Ultrasound (HIFU) for Lifting and Tightening Lax Facial & Neck Skin

Sharmila Nayak | India

INTRODUCTION

To meet increasing public demand about facial wrinkles and laxity due to aging, various noninvasive skin tightening & lifting treatment options are utilized including chemical peeling, fractional laser, radiofrequency & high intensity focused ultrasound; however, the ideal treatment option has yet to be identified^{1,2,3,4}. Recently, High Intensity Focused Ultrasound (HIFU) was used as novel treatment for therapeutic and cosmetic purposes^{5,6}. Focused ultrasound is highly convergent and uses different frequencies of acoustic energy than medical ultrasound devices. The high-frequency focused ultrasound beam is allowed to target the subcutaneous tissues such as the superficial musculoaponeurotic system (SMAS) passing harmlessly through the upper layers of skin. This HIFU beam generate instant microthermal lesions where collagen around the focal point will reach over 65°C and be denatured & contract within milliseconds leading to additional de novo collagen synthesis and remodeling^{7,9,10}. HIFU has been demonstrated to be safe and effective in numerous clinical trials as a noninvasive aesthetic treatment and has been cleared by the United States Food and Drug Administration (FDA) to noninvasively lift tissues in the eyebrow, neck, and submentum, and improve lines and wrinkles of the décollete¹⁰.

In proposed study, efficacy evaluation of the Ultraformer III (HIFU) treatment was done on the basis of clinical improvement, adverse effects and patient satisfaction, these parameters were evaluated using clinical photographs and by a Subject Global Aesthetic Improvement Scale (SGAIS) and Physician Global Aesthetic Improvement Scale (PGAIS) scores at 3 months after treatment, in 20 patients older than 25 years of age.

MATERIALS & METHODS

20 healthy subjects consisting of 15 women & 5 men between 25 to 60 years of age with skin laxity and facial wrinkles were enrolled into the study. Each subject was given informed consent & express their willingness to comply with all study requirement. All patients were of Fitzpatrick skin types IV and V. They were treated with HIFU device (Ultraformer III, Classys, South Korea) to

the entire face, except for the nose and eyes, by using the following elliptical transducers, 4.5 mm focal depth (4 MHz), 3 mm focal depth (7 MHz) and 1.5 mm focal depth (7 MHz). The pitch (distance between the two high intensity focused ultrasound) was kept constant at 1.5 mm for all the focal lengths and it delivers a shot in less than 35 milliseconds. Before initiating treatment, prior assessment of subjects' skin tissue quality was done based on parameters such as age & gender, BMI & volume of subcutaneous soft tissue in the region to be treated. On the basis of assessment, a customized protocol was developed for the subjects. Mild thick layer of ultrasound gel was applied before starting the treatment on the skin. Treatment for each area was given in three passes (horizontally, vertically and diagonal) to form a grid pattern which will give a proper lifting and will minimizes the skipped area. The whole face was treated with three different focal depths depending on areas where shoots were given (4.5 mm, 4 MHz; 3 mm, 7 MHz and 1.5 mm, 7 MHz). On the whole face 60% of area was covered by 4.5 mm transducer, 30% area by 3.0 mm transducer and 10% by 1.5 mm transducer.

Standardized two-dimensional photographs of each subject in frontal and 45° angle views, along with profiles from each side, were obtained using fixed camera and lighting conditions before, and 3 months after the treatment. All the subjects were evaluated based on a blinded qualitative assessment compared 90-days post treatment photos with baseline photos and quantitative improvement in skin tissue lift. The Subject Global Aesthetic Improvement Scale (SGAIS), Physician Global Aesthetic Improvement Scale (PGAIS) & Patient Satisfaction Questionnaires (PSQ) were also completed on 90 days post-treatment. Efficacy evaluation criteria's- the primary evaluation criteria is the overall improvement in skin lifting & tightening using blinded qualitative assessment of before & after treatment photographs. Secondary efficacy evaluation was done using PGAIS & SGAIS scale based on PSQ. Using subject's 2D photographs taken on each follow-up visit quantitative assessment of brow & lower face tissue lift were done. Baseline & post-treatment photos were matched to ensure proper alignment. For lower face, an improved lift measurement

was defined as a submental lift ≥ 1.0 mm. For the upper face, a lift measurement was considered improved if the eyebrow was raised ≥ 0.5 mm.

RESULTS

Demographic information

This study included 20 Indian patients (15 women and 5 men), aged 25 to 60 years (mean, 42.5 years) and All

20 subjects returned for the 90-day follow-up (100%). The number of shots delivered with the HIFU tightening device was 500 ± 50 .

Efficacy evaluation results

Among the 20 evaluated subjects, photos of 5 patients were excluded from blinded photography assessment, efficacy results were positive for 15 patients (75%).

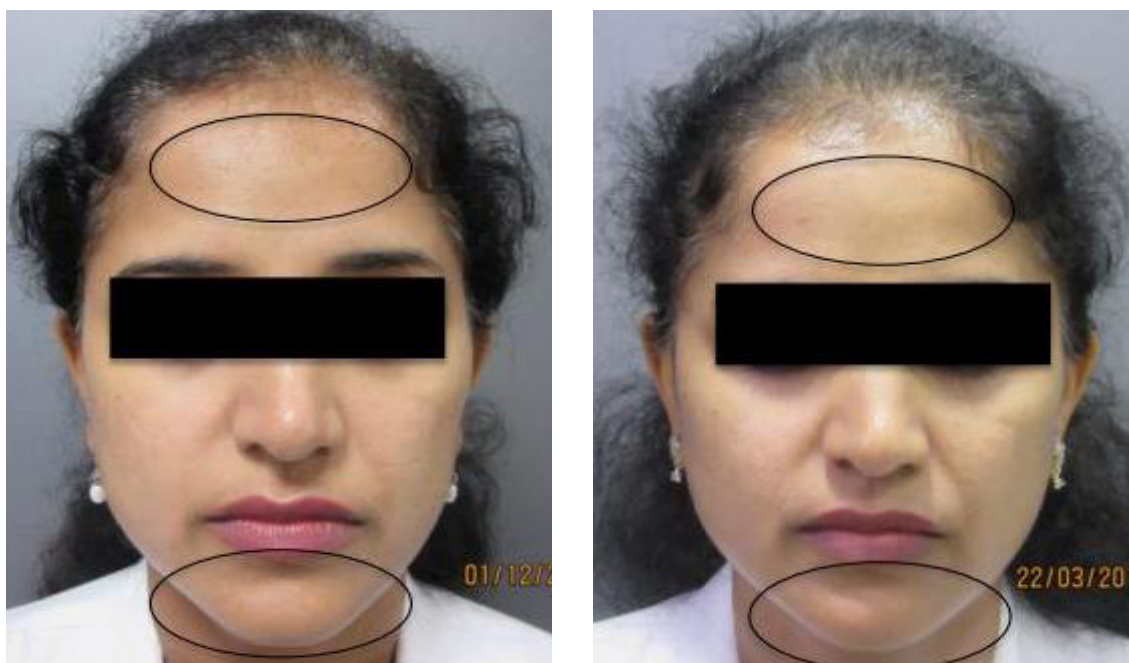

Fig-1 Frontal view of a representative subject at baseline and post-treatment Day 90

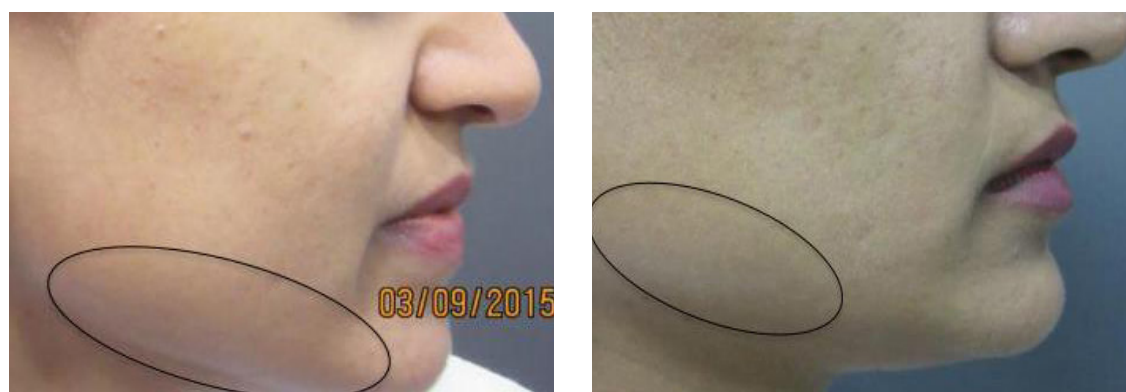

Fig-2 Lateral view of a representative subject at baseline and post-treatment Day 90

Substantial improvement after 90 days post treatment can be seen in frontal & lateral views of the treated subjects in Fig-1 & 2 respectively. Results of the PGAIS reflects that 100 percent of the subjects were having

aesthetic improvement after 90 days treatment, while SGAIS results indicated that 85 percent of subjects perceived aesthetic improvement after 90 days. Detailed PGAIS and SGAIS data are provided in Table 1.

Physician Scores	90 Days (N=20)
Very much improved	4 (20%)
Much improved	10 (50%)
Improved	6 (30%)
No change	0 (0%)
Worse	0 (0%)
All improved	20 (100%)
Subject Scores	
90 Days (N=20)	
Very Much improved	10 (50%)
Much improved	3 (15%)
Improved	2 (10%)
No change	2 (10%)
Worse	0
All improved	17 (85%)

Table-1 Global aesthetic improvement scale scores

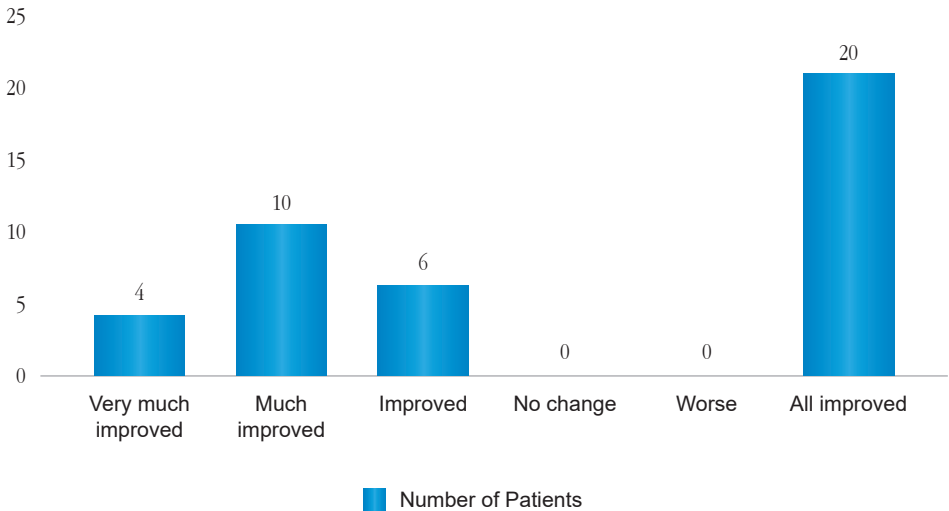


Fig-3 Physician aesthetic improvement scale score (PGAIS)

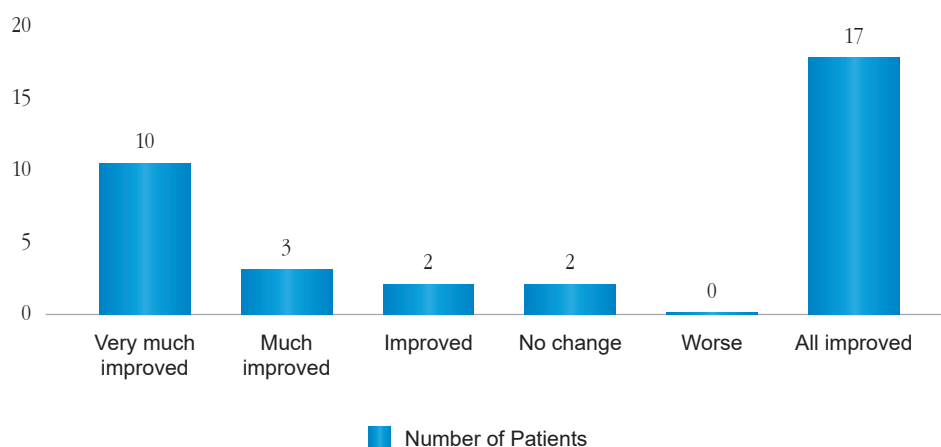


Fig-4 Subject aesthetic improvement scale score (SGAIS)

PATIENTS' SATISFACTION SCORE

Based on analysis of patient satisfaction questionnaires, 17 (85%) patients were found to have less sagging, 10 (50%) with less lines & wrinkles & 8 (40%) with smoother skin texture 8 (40%) (Fig-5).


We also assessed the efficacy and adverse effects 3 months after the treatment. Among 17 patients who replied, 5 patients answered that partial effects were still present in some areas.

Parameter	90 Days (N=20)
Patient Satisfaction	
Very Satisfied	15 (75%)
Satisfied	2 (10%)
Dissatisfied	3 (15%)
Very Dissatisfied	0 (0%)
Very Satisfied +Happy	17 (85%)
Improvement Noticed	
Lines / Wrinkles	10 (50%)
Less Sagging	17 (85%)
More Even Skin Tone	2 (10%)
Smoother Skin Texture	8 (40%)
Other	2 (10%)
No Improvement	3 (15%)
Would Continue & recommend treatment	
Yes	17 (85%)
No	3 (15%)


Table-2 Patient satisfaction Questionnaires

REFERENCES

1. Lee YB, Eun YS, Lee JH, Cheon MS, Cho BK, Park HJ. Effects of multi-polar radiofrequency and pulsed electromagnetic field treatment in Koreans: case series and survey study. *J Dermatolog Treat.* 2014;25:310–313.
2. Shapiro SD, Eros Y, Abrahami Y, Leviav A. Evaluation of safety and efficacy of the TriPollar technology for treatment of wrinkles. *Lasers Surg Med.* 2012;44:453–458.
3. Bloom BS, Emer J, Goldberg DJ. Assessment of safety and efficacy of a bipolar fractionated radiofrequency device in the treatment of photodamaged skin. *J Cosmet Laser Ther.* 2012;14:208–211.
4. Lee HS, Lee DH, Won CH, Chang HW, Kwon HH, Kim KH, et al. Fractional rejuvenation using a novel bipolar radiofrequency system in Asian skin. *Dermatol Surg.* 2011;37:1611–1619.
5. Kleinerman R, Whang TB, Bard RL, Marmur ES. Ultrasound in dermatology: principles and applications. *J Am Acad Dermatol.* 2012;67:478–487.
6. Suh DH, Oh YJ, Lee SJ, Rho JH, Song KY, Kim NI, et al. A intense-focused ultrasound tightening for the treatment of infraorbital laxity. *J Cosmet Laser Ther.* 2012;14:290–295.
7. White WM, Makin IR, Barthe PG, Slayton MH, Gliklich RE. Selective creation of thermal injury zones in the superficial musculoaponeurotic system using intense ultrasound therapy: a new target for noninvasive facial rejuvenation. *Arch Facial Plast Surg.* 2007;9:22–29.
8. Brobst RW, Ferguson M, Perkins SW. Ulthera: initial and six month results. *Facial Plast Surg Clin North Am.* 2012;20:163–176.
9. Laubach hJ, Makin Ir, Barthe Pg, et al. Intense focused ultrasound: evaluation of a new treatment modality for precise microcoagulation within the skin. *Dermatol Surg.* 2008;34:727–
10. Fabi Sg, goldman MP, Dayan Sh, et al. A prospective multicenter pilot study of the safety and efficacy of microfocused ultrasound with visualization for improving lines and wrinkles of the décolleté. *Dermatol Surg.* 2015;41:327–335.
11. Alam M, White LE, Martin N, Witherspoon J, Yoo S, West DP. Ultrasound tightening of facial and neck skin: a raterblinded prospective cohort study. *J Am Acad Dermatol.* 2010;62:262–269.
12. Suh DH, Shin MK, Lee SJ, Rho JH, Lee MH, Kim NI, et al. Intense focused ultrasound tightening in Asian skin: clinical and pathologic results. *Dermatol Surg.* 2011;37:1595–1602.
13. Chan NP, Shek SY, Yu CS, Ho SG, Yeung CK, Chan HH. Safety study of transcutaneous focused ultrasound for noninvasive skin tightening in Asians. *Lasers Surg Med.* 2011;43:366–



Efficacy and Safety of Non-invasive Body
Tightening with High Intensity Focused Ultrasound
(HIFU)



E. J. Ko | J. Y. Hong | T.-R. Kwon | E. J. Choi | Y.-J. Jang
S. Y. Choi | K. H. Yoo | S. Y. Kim | B. J. Kim

Efficacy and Safety of Non-invasive Body Tightening with High Intensity Focused Ultrasound (HIFU)

E.J. Ko et al. | South Korea

E. J. Ko^{1,2} | J. Y. Hong¹ | T.-R. Kwon¹ | E. J. Choi¹ | Y.-J. Jang^{1,3} | S. Y. Choi^{1,4} | K. H. Yoo⁵ | S. Y. Kim⁶ | B. J. Kim¹

¹Department of Dermatology, Chung-Ang University College of Medicine, Seoul, South Korea

²Department of Dermatology, Myongji Hospital, Seonam University College of Medicine, Goyang, Korea

³Department of Medicine, Graduate School, Chung-Ang University, Seoul, Korea

⁴Department of Dermatology, Seoul Paik Hospital, Inje University College of Medicine, Seoul, Korea

⁵Department of Dermatology, College of Medicine, Catholic Kwandong University, International St. Mary's Hospital, Incheon, Korea

⁶Classys Inc., Seoul, Korea

Correspondence

Beom Joon Kim, Department of Dermatology, Chung Ang University Hospital, 224-1 Heukseok-dong, Dongjak-ku, Seoul 156-755, South Korea. Email: beomjoon@unitel.co.kr

ABSTRACT

Background: Noninvasive skin-tightening devices have become increasingly popular in response to increasing demand for improvements in skin laxity and tightening with minimal risk and recovery time.

Objective: We evaluated the efficacy and safety of HIFU for skin tightening in the face and body.

Methods: A total of 32 Korean subjects enrolled in this prospective clinical trial. The subjects were treated with HIFU to both cheeks, lower abdomen, and thigh. Skin elasticity was measured before and after treatment using a Cutometer (CT575, Courage and Khazaka®, Cologne, Germany). Three blinded, experienced dermatologists evaluated paired pre- and post-treatment (week 4 and 12) photographs according to the Global Aesthetic Improvement Scale (GAIS). Participants also completed self-assessments using GAIS. Subjects rated their pain on a numeric rating scale (NRS) immediately, 7 days, 4 weeks, and 12 weeks after treatment.

Results: Skin elasticity measured via a Cutometer was significantly improved 12 weeks after treatment at all treated sites ($P < .05$). Both IGAI and SGAI showed significant improvements 12 weeks after treatment. Immediately after treatment the mean NRS score was 3.00 ± 1.586 , but no pain was reported at 4 and 12 weeks post-treatment. No serious adverse effects were observed during the follow-up period.

Conclusion: HIFU safely and effectively improves skin elasticity and clinical contouring of the face and body.

KEY WORDS: body tightening, high-intensity focused ultrasound

1. INTRODUCTION

The most common features of aging skin are laxity and loss of elasticity. As the skin ages, elastic fiber, collagen, and connective tissue in the dermis are reduced. Skin moisture and subcutaneous fat also decrease. There are many procedures to improve skin laxity, such as laser therapy, radiofrequency, botulinum toxin, fat autografts, and surgical lifting. Of these procedures, botulinum toxin and fat autografts are used for facial rejuvenation but are difficult to apply for improving body laxity. Radiofrequency and infrared laser devices which expose the dermis to controlled heat and stimulate neocollagenesis in dermis have inferior efficacy so that surgery still remains the treatment of choice in moderate to severe tissue laxity.¹ Although surgical face lifting is the most effective treatment to improve skin laxity, it is also a procedure that involves risks such

as scarring, infection, nerve damage, inherent risks of anesthesia, swelling, and bruising.² HIFU technology was originally used as a non-invasive modality for selectively destroying tumor cells of internal organs by thermal coagulative necrosis for many decades.³ HIFU was recently introduced as a new treatment modality for skin tightening and rejuvenation. The mechanism of HIFU is transcutaneous heat delivery to the deep dermis, subdermal connective tissue, and fibromuscular layer in precise micro-coagulation zones at consistent programmed depths without damage to the epidermis. This micro-coagulation is thought to cause gradual tightening of the skin through collagen contraction and remodeling.⁴ HIFU first received approval for eyebrow lifting, but dermatologists are using the technology for many off-label applications, such as facial rejuvenation, skin whitening, and lipolysis. HIFU has been used

safely and effectively to treat facial and neck skin in a variety of skin types, but some studies have examined its use for the body, including our pilot study.^{5–7} In this study, we sought to determine the clinical efficacy and safety of HIFU with novel transducers in both face and body regions.

2. SUBJECTS AND METHODS

Korean patients with skin laxity on the face, abdomen, and thigh were recruited for study entry. The study was approved by the Institutional Review Board of Chung-Ang University Hospital. Informed consent was obtained from all patients. Exclusion criteria were prior cosmetic or surgical treatments (e.g. laser, RF, surgical lifting, filler injections), skin infection or inflammation, pregnancy, skin diseases that may alter wound healing, open wounds, and scarring over the treatment area.

For pre-treatment preparation, we applied topical anesthetic cream to all treated areas including both cheeks, the lower abdomen, and the posterior thigh. The sizes of the involved areas were $5.0 \times 5.0 \text{ cm}^2$ on each cheek and $7.5 \times 7.5 \text{ cm}^2$ on each lower abdomen and thigh (Figure 1). We used a HIFU device (ULTRAFORMER III (SHURINK) CLASSYS INC., Seoul, Korea) with five different transducers: one basic transducer for facial skin tightening (MF1: 7-MHz, 1.5-mm focal depth), and four newly developed transducers for body skin tightening (MF3: 2-MHz, 3.0-mm focal depth, MF4: 2-MHz, 4.5-mm focal depth, MF6: 2-MHz, 6.0-mm focal depth and MF9: 2-MHz, 9.0-mm focal depth). Ultrasound gel was applied to the treated area and the transducer of HIFU was pressed perpendicularly, uniformly, and firmly to the skin surface (Figure 2). Treatment exposure was

initiated with a line of individual ultrasound pulses. The pulse duration for each individual exposure ranged from 25 to 40 milliseconds. The 25-mm-long exposure lines of ultrasound pulses were manually delivered adjacent and parallel to one another approximately 3–5 mm apart. We treated subjects with several types of transducers appropriate to the thicknesses of facial and body skin. Three transducers (MF1, 3, and 4) were applied to the face and all five transducers (MF1, 3, 4, 6, and 9) were applied to the body. The energy per ultrasound pulse ranged from 1.0 to 1.5 J. When patients reported feeling pain, we reduced exposures to 0.1–0.3 J per time, and did not increase exposures up to 1.5 J. The treatment lines included a total of 120 shots for the cheek, distributing a total 537.6 J, and 450 shots for the abdomen and thigh, distributing a total 900 J. The time required for complete HIFU treatment of the face and body was over 40 minutes.

All patients were followed up at 4 and 12 weeks after treatment, at which times we obtained clinical photographs using consistent patient positioning, camera settings (Canon EOS 600D, high-resolution setting, 5760×3840 pixels, Canon Inc., Tokyo, Japan), and room lighting. Baseline and post-treatment photographs were randomly displayed, and independently evaluated by three dermatologists who were masked to the study protocol. Investigator Global Aesthetic Improvement Scale (IGAIS) scores were determined using side-by-side comparisons of 4- and 12-week post-treatment photographs to baseline. The subjects also evaluated the tightening effects using the Subject Global Aesthetic Improvement Scale (SGAIS)

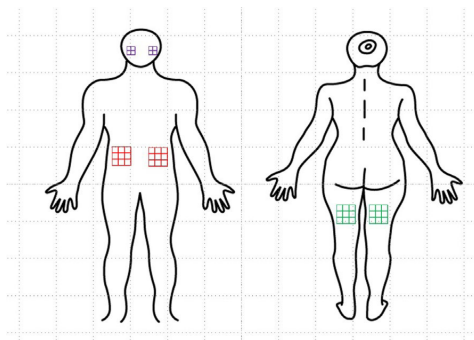


Figure 1 Face and body treatment areas

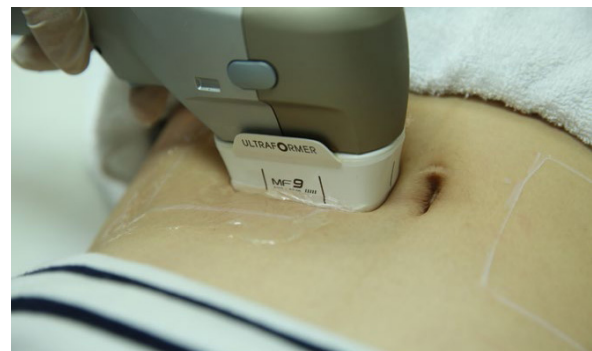

Figure 2 The ULTRAFORMER III (SHURINK) HIFU device MF9 (2 MHz, 9.0 mm) tip applied on the abdomen (obtained from Classys Inc., with permission)

at 4 and 12 weeks post-treatment. We used the Cutometer (Courage+Khazaka Electronic GmbH, Cologne, Germany) to measure skin elasticity and objectively evaluate skin tightening. Among the cutometer-specific R values (R0–R9), the R7 value is the ratio of elastic recovery to the total deformation.

2.1 Statistical analyses

Statistical analyses were performed using SPSS version 21.0 for Windows (SPSS Inc., Chicago, IL, USA) and R version 3.2.3 (2015-12-10). We used Hochberg step-up methods to adjust values for multiple comparisons. and represents biological elasticity. Adverse effects were assessed at each visit after treatment. A numeric rating scale (NRS) was used to score pain immediately, 7 days, 4 weeks, and 12 weeks after the application of HIFU. Statistical comparisons before and after treatments were performed using paired t tests. Data are presented as mean±standard deviation. P values <.05 were considered statistically significant.

3. RESULTS

3.1 Efficacy

This study included 32 Korean patients (29 females and 3 males), aged 21–59 (mean±SD: 44.47±9.73) with Fitzpatrick skin types III and IV. All patients completed the 3-month study. The mean R7 value according to the Cutometer was significantly increased at 4 and

12 weeks post-treatment compared to baseline in all treated areas (Figure 3). The change of the mean R7 value at the thigh was 0.054 ± 0.032 , which represented the greatest change among the treated areas. IGAI scores also showed good results (Table 1). Of the three treated areas, the cheek demonstrated the greatest improvements after treatment. At 4 weeks post-treatment, the improvement rates of subjects who were assessed as either improved (IGAI score 1) or much improved (IGAI score 2) were 96.9%, 84.4%, and 78.1% on the cheek, abdomen, and thigh respectively. At 12 weeks post-treatment, the improvement rate of the cheek area was reduced to 90.6%, but the body areas did not change significantly. Most subjects were satisfied with the results of treatment (Table 2). At 4 weeks post-treatment, all subjects rated SGAIS scores as greater than 1 on the cheek and thigh. The improvement rate assessed for the abdomen as greater than SGAIS 1 was 93.8%. At 12 weeks post-treatment, the improvement rates of cheek and thigh were reduced from 100% to 96.9%. However, the improvement rate of the abdomen increased to 96.8%.

3.2 Safety

The mean pain scores immediately and at 7 days after treatment were 3.00 ± 1.586 and 0.031 ± 0.177 , respectively. The degree of pain decreased substantially within the first week post treatment. All patients were able to complete the treatment. No subjects

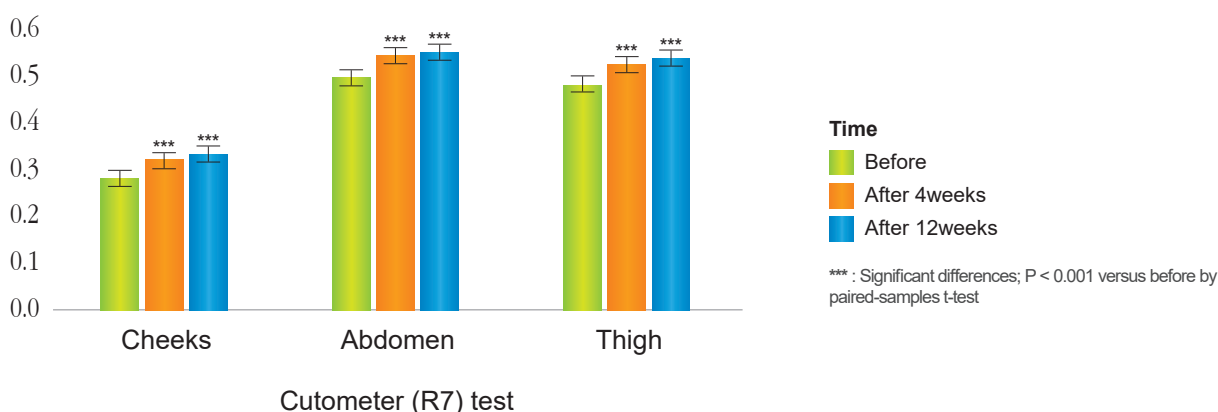


Figure 3 Mean pre-and post-treatment R7 values of skin elasticity measured using Cutometers

		IGAIS			
		0	1	2	3
Cheek					
Post-treatment(4W)	n	1	29	2	0
	%	3.1	90.6	6.3	0
Post-treatment(12W)	n	3	29	0	0
	%	9.4	90.6	0	0
Abdomen					
Post-treatment(4W)	n	5	27	0	0
	%	15.6	84.4	0	0
Post-treatment(12W)	n	5	26	1	0
	%	15.6	81.3	3.1	0
Thigh					
Post-treatment(4W)	n	7	25	0	0
	%	21.9	78.1	0	0
Post-treatment(12W)	n	7	25	0	0
	%	21.9	78.1	0	0

0=No change, 1=Mild improvement, 2=Moderate improvement, 3=Significant improvement.

Table 1 Investigator Global Aesthetic Improvement Scale(IGAIS)

		SGAIS			
		0	1	2	3
Cheek					
Post-treatment(4W)	n	0	13	13	6
	%	0	40.6	40.6	18.8
Post-treatment(12W)	n	1	10	10	8
	%	3.1	31.3	40.6	25
Abdomen					
Post-treatment(4W)	n	2	15	11	4
	%	6.3	46.9	34.4	12.5
Post-treatment(12W)	n	1	13	13	5
	%	3.1	40.6	40.6	15.6
Thigh					
Post-treatment(4W)	n	0	14	13	5
	%	0	43.8	40.6	15.6
Post-treatment(12W)	n	1	13	11	7
	%	3.1	40.6	34.4	21.9

0=No change, 1=Mild improvement, 2=Moderate improvement, 3=Significant improvement.

Table 2 Subject Global Aesthetic Improvement Scale (SGAIS)

experienced persistent pain over the treatment areas at 3 months follow-up. Erythema was seen in up to 9.38% of the treatment sessions immediately post-treatment, but mostly subsided within 5 days (Figure 4). No patients showed surface injury or thermal damage on the treatment site. Ecchymosis was seen in up to 6.25% of treatment sessions immediately post-treatment. By 3 days post-treatment, all cases of ecchymosis had resolved. We observed no serious or delayed adverse effects during the follow-up period.

4. DISCUSSION

There are many noninvasive options of body sculpting, such as radiofrequency ablation, cryolipolysis, injection lipolysis, external low-level lasers, laser ablation, non-thermal ultrasound, and HIFU. Each of these treatments has no admission for treatment without anesthesia or analgesia and typically fewer complications than liposuction. However, with the exception of HIFU, patients have to visit the hospital several times for multiple treatments to achieve meaningful. Injection lipolysis and cryolipolysis have significant potential for AEs, which is largely unregulated and may cause significant pain, hematoma, allergic reactions, necrosis, scarring, panniculitis, and rapid release of lipids into the bloodstream.

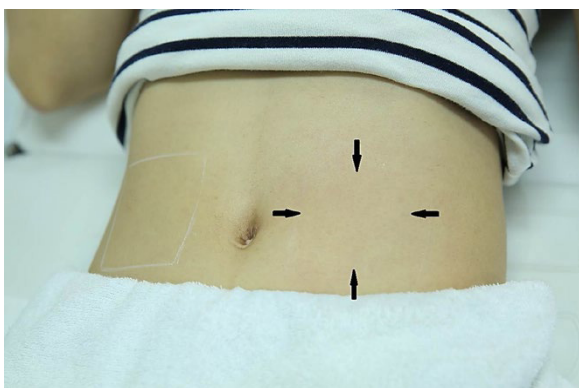


Figure 4 Post-procedural mild erythema on the HIFU application site immediately after the treatment (black arrows). Erythema was resolved within 5 days

In contrast, previous clinical studies supported thermal HIFU for body sculpting have had no serious AEs including alterations in lipid profiles or other laboratory parameters⁵⁻⁸. Therefore, many clinicians are keeping

an eye on the HIFU technique as purpose of body sculpting. Studies of HIFU facilitate the understanding of mechanisms of action for body sculpting. When used for body sculpting, HIFU delivers focused, high intensity ultrasonic energy to deep subcutaneous tissue, producing heat capable of effectively ablating adipocytes and thermally modifying collagen within the tissue matrix. In addition to local adipocyte necrosis, evidence of collagen remodeling from the thermal effects of HIFU has been observed.⁹ Application of HIFU at a frequency of 1 MHz to adipose tissue leaves collagen fibers intact, but at frequencies of 2–3 MHz, diffuse contraction of collagen fibers occurs. Histological analyses performed after the procedure confirm that HIFU disrupts or denatures collagen fibers, resulting in new collagen formation accompanied by a general tightening of the septal fibers and skin.⁹ Based on these results, newly developed transducers for application to body sites at a variety of focal depths (3.0–9.0 mm) are deemed to be suitable for body tightening. Also, we found no thermal damage on the skin surface of the HIFU treatment site. Kwon et al. has reported the temperature changes of the porcine model during HIFU procedure, which showed targeted subcutaneous fat to be around 70°C, while the skin surface temperature only went up to 33.1–35.6°C.¹⁰ Therefore, we hypothesized that newly developed transducers could effectively and safely deliver HIFU energy deeper into the skin and eventually show body sculpting effects due not only to skin tightening but also to the reduction of subcutaneous fats. In this study, we used the Cutometer to evaluate the skin tightening effects of HIFU. Objective measurements of skin elasticity after laser, radiofrequency, and HIFU treatments are desirable. The use of uniform photographic documentation has improved, but there are often still inconsistencies in patient position and lighting. Physician-based grading systems are characterized by inherent elements of subjectivity. The purely objective quantification of results would be of great benefit for the evaluation of skin tightening procedures.

There are several reports describing the quantification of facial rejuvenation results using Cutometers. These include Shin et al., who used Cutometers to assess

the effectiveness of photographic rejuvenation with intense pulsed light (IPL).¹¹ Similarly, Naouri et al. assessed improvements in skin tightness after applying CO₂ fractional lasers.¹² Ahn et al. demonstrated a stronger relationship between aging and skin elasticity parameters (R2, R7) than between aging and skin viscoelasticity parameters using Cutometers (R6),¹³ while Kruger et al. made similar observations by conducting cutometric tests in a group of 120 females treating various parts of the body (cheek, neck, neckline, forearm, and back of the hand). They recommended the application of parameters R2 and R7 to evaluate the process of skin aging.¹⁴ Thus, this study determined the R7 value from nine parameters of Cutometer.

In this study, we observed significant improvements in two body regions (abdomen and thighs) as well as

the cheek when targeted for HIFU treatment. Adverse effects were limited to transient pain in most patients and occasional erythema or ecchymosis in some patients. HIFU can be safely and effectively used to improve the clinical appearance of the abdomen and thighs. Therefore, HIFU could meet current demands for significant, noninvasive skin lifting and tightening. Tightening and lifting of facial and body skin laxity can be achieved by inducing collagen fiber contraction and stimulating de novo collagenesis. By using newly developed transducers with different energy outputs and focal depths, HIFU treatment can be tailored to meet the unique physical characteristics of each patient.

CONFLICTS OF INTEREST

Not declared.

REFERENCES

1. MacGregor JL, Tanzi EL. Microfocused ultrasound for skin tightening. *Semin Cutan Med Surg*. 2013;32:18-25.
2. Northington M. Patient selection for skin-tightening procedures. *J Cosmet Dermatol*. 2014;13(3):208-211.
3. Laubach HJ, Makin IR, Barthe PG, Slayton MH, Manstein D. Intense focused ultrasound: evaluation of a new treatment modality for precise microcoagulation within the skin. *Dermatol Surg*. 2008;34(5):727-734.
4. Minkis K, Alam M. Ultrasound skin tightening. *Dermatol Clin*. 2014;32(1):71-77.
5. Choi SY, No YA, Kim SY, Kim BJ, Kim MN. Tightening effects of high-intensity focused ultrasound on body skin and subdermal tissue: a pilot study. *J Eur Acad Dermatol Venereol*. 2016;30(9):1599-1602.
6. Alster TS, Tanzi EL. Noninvasive lifting of arm, thigh, and knee skin with transcutaneous intense focused ultrasound. *Dermatol Surg*. 2012;38(5):754-759.
7. Solish N, Lin X, Axford-Gatley RA, Strangman NM, Kane M. A randomized, single-blind, postmarketing study of multiple energy levels of high-intensity focused ultrasound for noninvasive body sculpting. *Dermatol Surg*. 2012;38(1):58-67.
8. Shek SY, Yeung CK, Chan JC, Chan HH. Efficacy of high-intensity focused ultrasonography for noninvasive body sculpting in Chinese patients. *Lasers Surg Med*. 2014;46(4):263-269.
9. Fatemi A. High-intensity focused ultrasound effectively reduces adipose tissue. *Semin Cutan Med Surg*. 2009;28:257-262.
10. Kwon TR, Im S, Jang YJ, et al. Improved methods for evaluating pre-clinical and histological effects of subcutaneous fat reduction using high-intensity focused ultrasound in a porcine model. *Skin Res Technol*. 2017;23(2):194-201.
11. Naouri M, Atlan M, Perrodeau E, et al. Skin tightening induced by fractional CO₂ laser treatment: quantified assessment of variations in mechanical properties of the skin. *J Cosmet Dermatol*. 2012;11:201-206.
12. Hedelund L, Due E, Bjerring P, Wulf HC, Haedersdal M. Skin rejuvenation using intense pulsed light: a randomized controlled split face trial with blinded response evaluation. *Arch Dermatol*. 2006;142(8):985-990.
13. Ahn S, Kim S, Lee H, Moon S, Chang I. Correlation between a Cutometer® and quantitative evaluation using Moire topography in age-related skin elasticity. *Skin Res Technol*. 2007;13(3):280-284.
14. Krueger N, Luebberding S, Oltmer M, Streker M, Kerscher M. Age-related changes in skin mechanical properties: a quantitative evaluation of 120 female subjects. *Skin Res Technol*. 2011;17(2):141-148.

How to cite this article: Ko EJ, Hong JY, Kwon T-R, et al. Efficacy and safety of non-invasive body tightening with high-intensity focused ultrasound (HIFU). *Skin Res Technol*. 2017;00:1–5. <https://doi.org/10.1111/srt.12371>



High Speed Low-pain Micro Focused Ultrasound
Tightening of the Lower Face and Neck



Adrian Lim, MD

High Speed Low-pain Micro Focused Ultrasound Tightening of the Lower Face and Neck

Adrian Lim, MD | Australia

Dr Adrian Lim MBBS FACD FACP
Royal North Shore Hospital, uRepublic Cosmetic Dermatology
and Veins NSW Australia

INTRODUCTION

There is strong demand for non-surgical tightening procedures, especially to the jowl and neck areas, for a more youthful mandibular and neck contour (jawline). Popular procedures such as filler and botulinum toxin injections mainly target the face leaving the jowl and neck areas increasingly lagging with time. Non-surgical jowl and neck lifting procedures include skin resurfacing and various skin heating devices such as infrared, radiofrequency and micro-focused ultrasound (MFU).¹⁻⁴ Ablative resurfacing can tighten the skin but is largely limited by the recovery time and potential complications such as pigmentary alteration and scarring. On the other hand, non-invasive skin tightening devices are limited by subtle and inconsistent results, long treatment times and significant procedural discomfort.⁵ In 2016, the Australian Therapeutic Goods and Services (TGA) approved a new high-speed, low-pain MFU device (Ultraformer 3) for skin tightening. This study is an evaluation of the safety, efficacy and patient satisfaction rate of Ultraformer 3 on lower face and neck laxity.

Mechanism of action of Ultraformer 3

MFU can visibly tighten skin laxity in excess of 80% of cases.⁶⁻⁸ MFU targets the SMAS (face lifting plane) for more natural and durable skin tightening. The delivery of the MFU is not associated with any epidermal injury and therefore does not require any recovery or down time. The focused and precise energy delivery is associated with significantly less side-effects such as burns, blisters, diffuse heating with collateral damage to adjacent epidermis or adipose tissue.

The Ultraformer 3 has a patented ultrasound focusing and delivery method that precisely targets tissue at adjustable depths of 4.5mm, 3mm and 1.5mm depending on the transducer cartridge selected, with corresponding frequencies of 4MHz, 7Mhz and 7 MHz respectively. In accordance to ultrasound physics, the higher frequency transducer cartridge corresponds to a more superficial focal depth. The Ultraformer 3 uses a proprietary mechanism enabling targeting a

depth of 1.5mm without exceeding 7Mhz compared to conventional non-Ultraformer technology. The thermal injury zone (TIZ) is spaced between 1-2mm apart and the energy can be varied from 0.1J to 1.5J. The pulse duration for the 4.5mm cartridge range from 22ms (0.1J) to 33ms (1.5J) and the pulse duration for the 3mm cartridge range from 43ms (0.1J) to 65ms (1.5J). The relatively low pulse duration combined with adjustable energy allows precise and focused energy delivery without excessive collateral damage beyond the TIZ. The patented technology also enables faster treatment times with less procedural discomfort.

The objective of this study is to prospectively evaluate the efficacy and safety of the latest MFU (Ultraformer 3) for mandibular and neck contouring in patients with age-related laxity. We also undertook a patient satisfaction survey on the Ultraformer 3 procedure.

METHODS

All 20 enrolled patients satisfied the inclusion/ exclusion criteria of: age 40 years or more, no previous skin tightening treatment in last 12 months, no neck or lower face botulinum injections for the last 6months and during the follow up period. Standardised face and neck photography was taken at baseline, immediately post-procedure and at subsequent follow-up at 6 weeks or more post-procedure. Patient satisfaction was assessed by a standardised survey performed at subsequent post-treatment follow-up visit (4 – 20 weeks). Procedural efficacy was rated by 2 blinded dermatologists examining baseline and post-procedural photos. The skin tightening treatment was administered by 2 trained registered nurses using the Ultraformer 3 (Classys, Korea). All patients were pre-treated with 60 minutes of compound anaesthetic to the lower face and neck and intra-operative chilled air cooling (Cryojet) and the additional options of using inhaled nitrous oxide if required. The treatment areas were: (A) lower face and (B) upper neck: submental and submandibular regions (avoiding thyroid). The method of treatment is as follows: (A) lower face: 2 passes – 2 columns down and 2 columns across – first pass is parallel to the jawline and second pass is perpendicular (90 degrees) to the jawline, and (B) upper neck: 2 passes parallel to the mandibular jawline (bilateral) and submental region.

RESULTS

The patient demographics were: 19 females and 1 male, age range: 49 to 69 years-old (mean 58.7 years-old). Almost all patients commented on some degree of skin contraction and improvement in facial and neck contours immediately post procedure. At follow-up (4 – 20 weeks), 75% of patients continue to report a high degree of satisfaction. 95% of patients found the procedure tolerable requiring only topical anaesthesia and chilled air (Cryojet) for pain control during treatment. None required oral or injectable anaesthesia and only one third of patients requested additional inhaled nitrous oxide. 85% of patients would consider having the Ultraformer 3 again in the future and 75% would recommend the procedure to a friend. The patient satisfaction survey is summarized in table 1. Two blinded dermatologists were asked to study a

series of subject images consisting of baseline images, immediately post-procedure images and one or more follow-up images ranging from 4- to 20- weeks post-procedure (figures 1-4). The blinded dermatologists were then asked to pick out the 'best' (most improved) image, which correlated with the follow-up images in 71.4% of cases (5 out of 7 patients). The blinded dermatologists (D1 and D2) were also asked to pick out the 'worse' image, which correlated with the pre-procedure baseline images in 72.5% of cases. The blinded dermatologists' survey is summarised in table 2. There were no long term adverse events noted. Mild to moderate transient erythema is commonly seen post-procedure lasting approximately 30 minutes. One patient on fish oil developed mild bruising that resolved fully after a few days. There were 2 transient but notable post-treatment effects: one patient had transient

Strongly Disagree (-2)	Disagree (-1)	Uncertain (0)	Agree (1)	Strongly Agree (2)	Weighted Mean (-2 to 2)	Median Score
Q1. I am satisfied with the outcome of the procedure						
0 respondents	1 respondent	4 respondents	7 respondents	8 respondents	1.1	Strongly Agree
Q2. I would consider having the procedure again in the future						
0 respondents	0 respondents	3 respondents	7 respondents	10 respondents	1.35	Strongly Agree
Q3. I would recommend this procedure to a friend						
0 respondents	0 respondents	5 respondents	6 respondents	9 respondents	1.2	Strongly Agree
4. I find the comfort level of the procedure to be						
'very uncomfortable'	'uncomfortable but bearable'	'slightly uncomfortable'	'comfortable'	'very comfortable'	-0.15	Slightly uncomfortable but bearable
1 respondent	7 respondent	7 respondent	4 respondent	1 respondent		
Q5. I find the duration of treatment						
'much longer than expected'	'longer than expected'	'about right'	'shorter than expected'	'much shorter than expected'	0.3	About right
0 respondent	1 respondent	14 respondent	3 respondent	2 respondent		

Table 1 Ultraformer patient satisfaction survey.

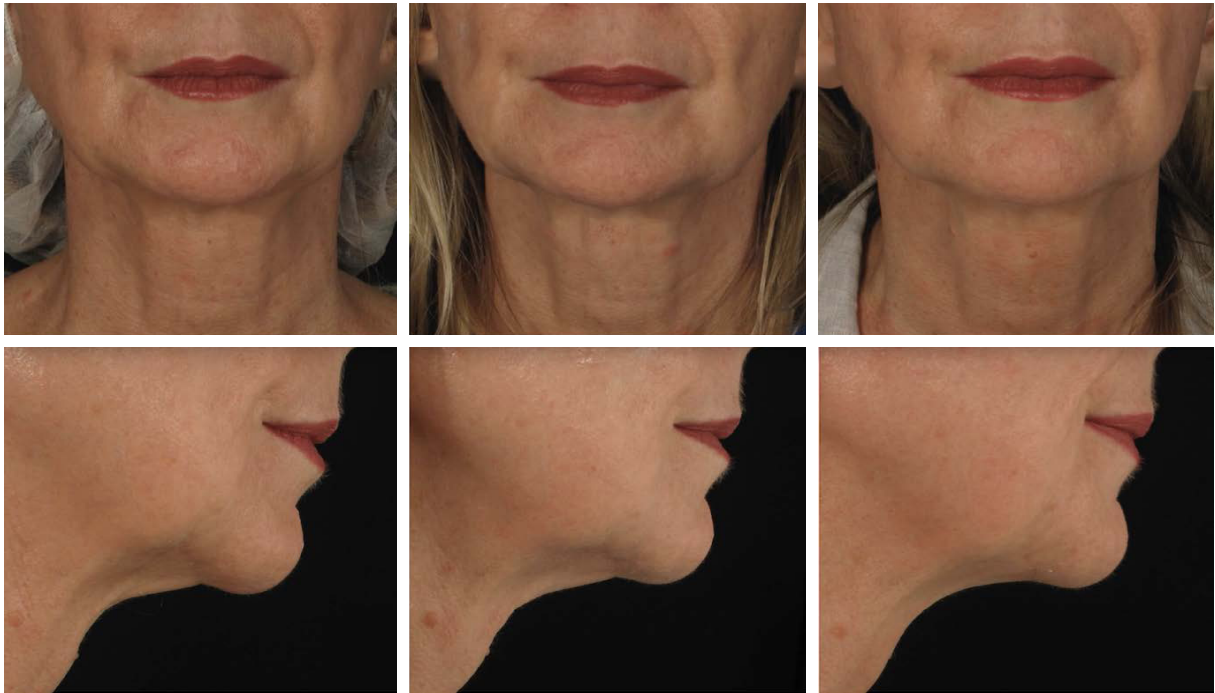

Figure 1 59 year-old female at baseline, 1-month, 2-months post-procedure (left to right).

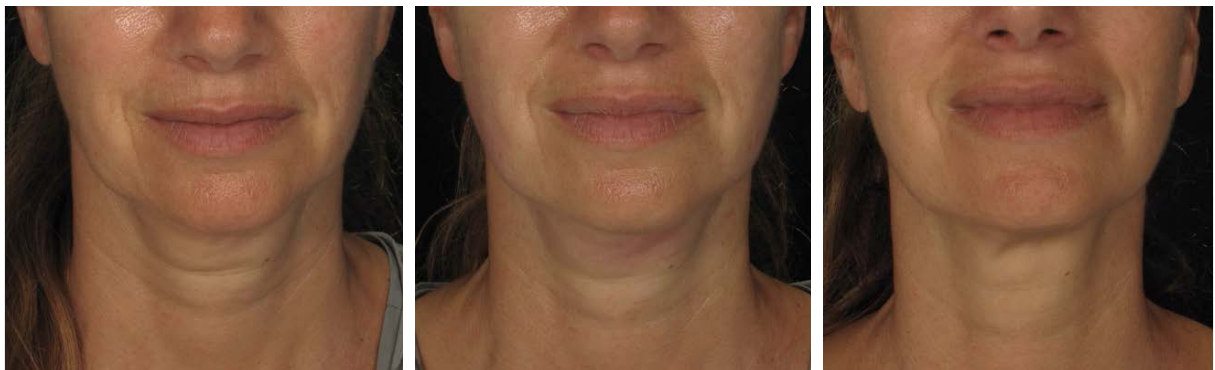

Figure 2 50 year-old female at baseline, immediately post, and 3-months post procedure (left to right).

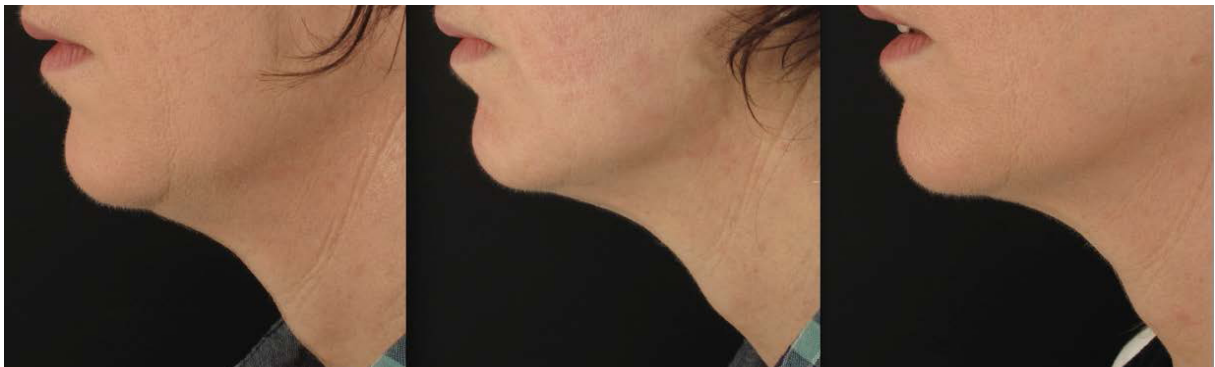

Figure 3 50-year old female at baseline, immediately post, and 3-months post-procedure (left to right).

Case	Post (Week)	D1 * 'worse'	D2 * 'worse'	D1 ** 'best'	D2 ** 'best'
1	0, 6, 20	0	0	1	0
2	0, 10	1	1	1	1
3	0, 4	0	1	0	1
4	0, 4	1	1	0	1
5	0, 6	1	0	1	0
6	0, 4, 8	1	0	1	1
19	0, 8	1	1	1	1
7	0	0	1		
8	0	1	1		
9	0	1	1		
10	0	1	1		
11	0	0	0		
12	0	0	0		
13	0	1	1		
14	0	1	1		
15	0	1	1		
16	0	0	1		
17	0	1	1		
18	0	1	1		
20	0	1	1		
		14/20 *	15/20 *	5/7 **	5/7 **

* correctly identifies the baseline ('worse') picture. D1, D2 mean = 72.5%

** correctly identifies the best ('lasest') picture. D1, D2 mean = 71.4%

Table 2 Blinded physician (dermatologists D1 and D2) survey.

mild linear erythematous plaques for 24 hours after treatment and another patient had subtle asymmetry of smile for a few days after treatment, which fully resolved after one week.

DISCUSSION

MFU has been used for skin tightening in facial and non-facial sites.^{5,6,9,10} Upper face tightening for brow and eyelid laxity are easier to objectively measure using fixed landmarks such as pupils and eyebrows and have been subjected to studies with various skin tightening procedures including MFU.⁶ The jowl and neck areas are more difficult to consistently measure in the absence

of an objective grading scale or readily identifiable landmark and studies have to rely on photographic changes and subjective patient self-assessment. We elected to study jowl and neck tightening because this is an area that is not easily treatable by other non-invasive techniques such as cosmetic injectables and non-MFU skin tightening procedures. The aging jowl and neck is therefore of great concern to all cosmetic patients, with progressive lagging in these areas with the passage of time, relative to the mid to upper face, resulting in strong patient demand in our practice for jowl and neck tightening procedures.

The limitations of skin tightening devices include

inconsistent results, need for multiple treatments, procedural discomfort, durability of results and costs.⁵ Patient satisfaction rate for skin tightening procedures range from 31% for monopolar radiofrequency to 80% for MFU.^{8,11} In our study, 75% of patients are satisfied with the treatment outcome and this high patient satisfaction rate in part translates to a desire for repeat procedures (85%) and referring the procedure to others (75%). Procedural tolerability is another important patient consideration for return visits. In this regard, Ultraformer 3 is notably different from non-Ultraformer MFU in that it is well tolerated - 95% reported the experience as either 'very comfortable', 'comfortable' or 'slightly uncomfortable but bearable'. The average treatment time is less than 20 minutes and 70% of patients rated the treatment time to be 'about right' while another 25% rated the treatment time to be 'shorter' or 'much shorter' than expected. Pre-Ultraformer devices tend to be associated with a significant discomfort requiring oral anxiolytics and oral / intramuscular narcotic analgesics and is clearly a significant barrier to the uptake of pre-Ultraformer MFU treatments.⁴

The safety of MFU is well established with a very low reported incidence of adverse events. Overheating of the skin with inappropriately high energy settings can result in blisters and reticulate scars but the associated pain will usually prevent this from happening and indeed there are no reports of MFU related scarring.⁴ In our study, there were 2 transient post-treatment effects that deserve further comment: firstly, transient mild linear erythematous plaques can occur but these generally last for less than 24 hours although there has been report of these lasting for days with subsequent full resolution with topical steroids. When linear plaques become noticeable during treatment, a decrease in fluence is recommended. Another patient had transient thermal neuropraxia from inadvertent MFU targeting of the left marginal mandibular nerve resulting in subtle transient lip weakness. The temporal nerve and marginal mandibular nerve are vulnerable to MFU effects at the temple and lateral chin respectively, and are 'caution areas' during MFU therapy. Transient sensory thermal neuropraxia presenting as tingling and numbness can also uncommonly occur.

Blinded physician assessment of the before-and-after

photos show a noticeable change post-procedure (1- to 4.5- months, mean: 8.6 weeks). Although there is an initial non-response rate of up to 27.5%, based on blinded 2-dimensional photo-ratings, these 'non-responders' may subsequently show a noticeable tightening response at a later time-point (figure 4), consistent with delayed collagen remodeling effects.

The durability of results has not been well studied and there is no data on the effects of regular MFU treatment on skin ageing. Although MFU is generally considered a single session treatment, others have anecdotally observed better patient results with up to 3 treatment sessions at 4-6 month intervals, followed by annual maintenance sessions (personal communication, Korea). We hypothesize that regular maintenance MFU treatments may slow down skin laxity and aging and we will examine this with longitudinal data on the effect of regular MFU on skin laxity over time. Our commercial experience with Ultraformer 3 has been very favourable. There is a market gap for a non-surgical lower face and neck tightening procedure that delivers consistent results without being too uncomfortable or protracted. Patients are often very receptive to procedural recommendation for jowls and facial sagging and will be prepared to have repeat treatments and recommend the procedure to others if the procedure meets their expectation in efficacy and tolerability. From the practitioner's perspective, the Ultraformer 3 is easy to handle and drive and can be performed by doctors, nurses, dermal therapists and other trained allied health practitioners. Ultraformer 3 can be delegated to suitably trained staff because of its dependable, non-laser technology coupled with a low incidence of adverse events. The device affordability and low running cost makes it an attractive business and commercial proposition, which adds value for the patient. The limitations of this study are a relatively small sample size, a relatively short follow-up period of less than 6-months and potential investigator bias from using an industry-sponsored device (Cryomed Australia).

CONCLUSION

MFU therapy with the Ultraformer 3 is a safe, effective high-speed, low-pain procedure that meets a clear

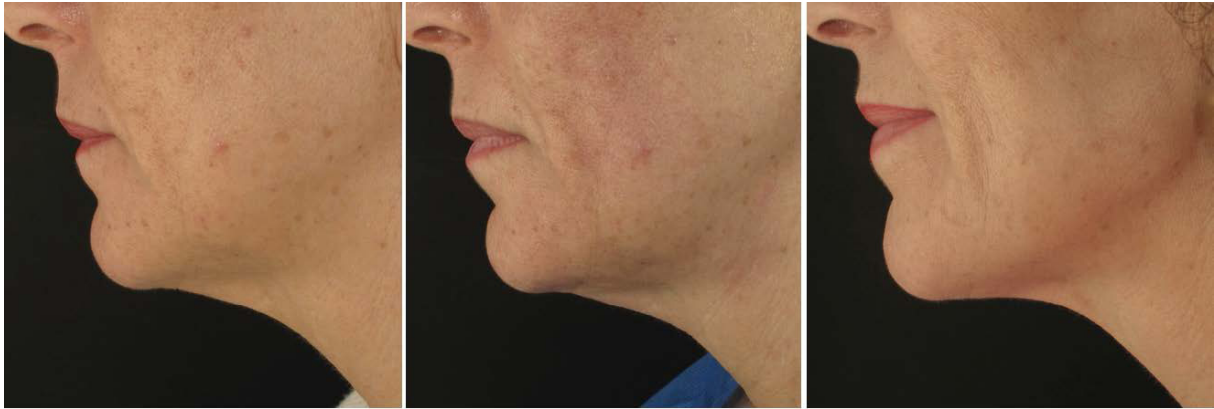

Figure 4. 50 year-old female at baseline, immediately post- and 1-month post-procedure (left to right) highlighting gradual neck and jawline tightening even though there was no observable change immediately post-procedure (centre image).

need amongst patients seeking skin tightening. The procedure induces noticeable skin tightening post-procedure with a 75% patient satisfaction rate that is independently and objectively verifiable. Patients tolerated the procedure well with only topical

anaesthesia and chilled air cooling. The favourable procedural experience and results convert to an 85% reported desire for repeat procedures and 75% referral rate to others.

REFERENCES

1. Fitzpatrick RE, Rostan EF, Marchell N. Collagen tightening induced by carbon dioxide laser versus erbium:YAG laser. *Lasers Surg Med.* 2000; 27:395-403.
2. Tanzi EL, Lupton JR, Alster TS. Lasers in dermatology: Four decades of progress. *J Am Acad Dermatol.* 2003;49:1-31.
3. Zelickson BD, Kist D, Bernstein E, et al. Histological and ultrastructural evaluation of the effects of a radiofrequency-based nonablative dermal remodeling device: A pilot study. *Arch Dermatol.* 2004;140:204-209.
4. MacGregor JL1, Tanzi EL. Microfocused ultrasound for skin tightening. *Semin Cutan Med Surg.* 2013 Mar;32(1):18-25.
5. Alster TS, Tanzi EL. Noninvasive lifting of arm, thigh, and knee skin with transcutaneous intense focused ultrasound. *Dermatol Surg.* 2012; 38:754-759.
6. Alam M, White LE, Martin N, et al. Ultrasound tightening of facial and neck skin: A rater-blinded prospective cohort study. *J Am Acad Dermatol.* 2010;62:262-269.
7. Suh DH, Shin MK, Lee SJ, et al. Intense focused ultrasound tightening in Asian skin: Clinical and pathologic results. *Dermatol Surg.* 2011;37:1595-1602.
8. Lee HS, Jang WS, Cha YJ, et al. Multiple pass ultrasound tightening of skin laxity of the lower face and neck. *Dermatol Surg.* 2012;38:20-27.
9. Fabi SG. Microfocused ultrasound with visualization for skin tightening and lifting: my experience and a review of the literature. *Dermatol Surg.* 2014 Dec;40 Suppl 12:S164-7.
10. Fabi SC, Massaki A, Eimpunth S, Pogoda J, et al. Evaluation of microfocused ultrasound with visualization for lifting, tightening, and wrinkle reduction of the décolletage. *J Am Acad Dermatol.* 2013;69:965-71 .
11. Hsu TS1, Kaminer MS. The use of nonablative radiofrequency technology to tighten the lower face and neck. *Semin Cutan Med Surg.* 2003 Jun;22(2):115-23.



Face Lifting and Body Modeling without a Scalpel



Radosław Rzepnikowski

Face Lifting and Body Modeling without a Scalpel

Radoslaw Rzepnikowski, MD | Poland

Ultraformer III is an innovative device used in the field of aesthetic medicine for facelift and body modeling and face without scalpel. Thanks to HIFU technology, the skin of the body is firmly nourished and rejuvenated. HIGH means High Intensity Focused Ultrasound is a technology that uses a focused ultrasonic wave that is responsible for heating the tissues of the skin, muscles and fat, which in turn leads to their shrinking and micro-stimulation stimulating the formation of new collagen.

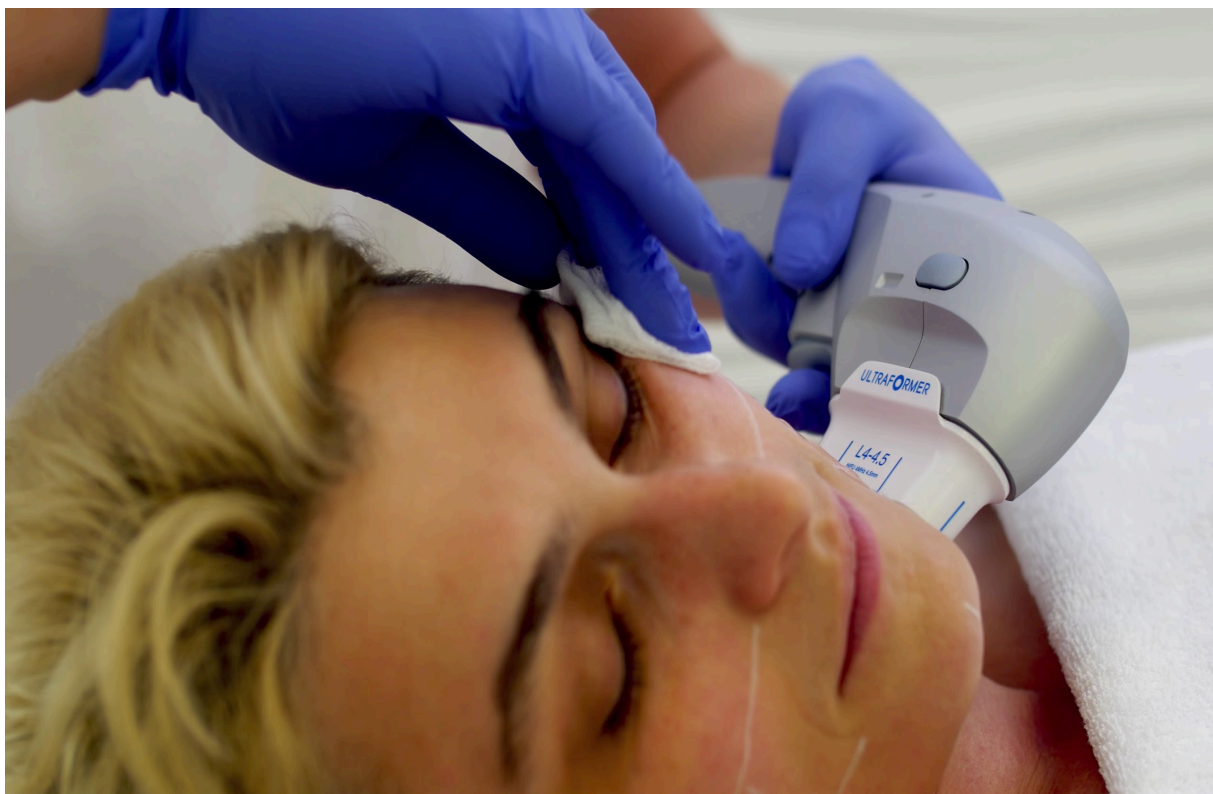The Ultraformer III machine, which allows for a non-operative lifting, is a milestone in the treatment of skin pruritis, especially in the most sensitive areas such as breast, buttocks, abdomen, thighs and shoulders . The ultrasound method is safe, noninvasive, clinically tested and above all effective. It gives spectacular results that satisfy every patient. After just one treatment the skin becomes more elastic and taut.

The non-invasive Ultraformer III machine is an incredible American equipment for skin lifting without the use of a scalpel. This is the latest aesthetic medicine

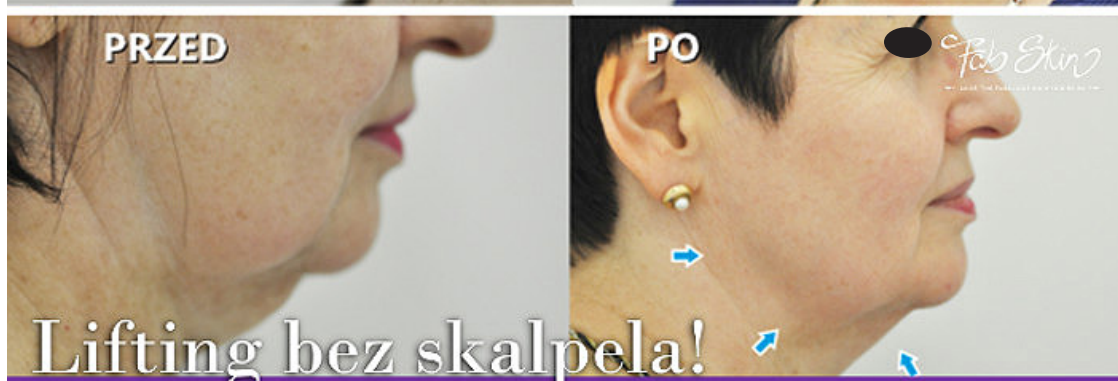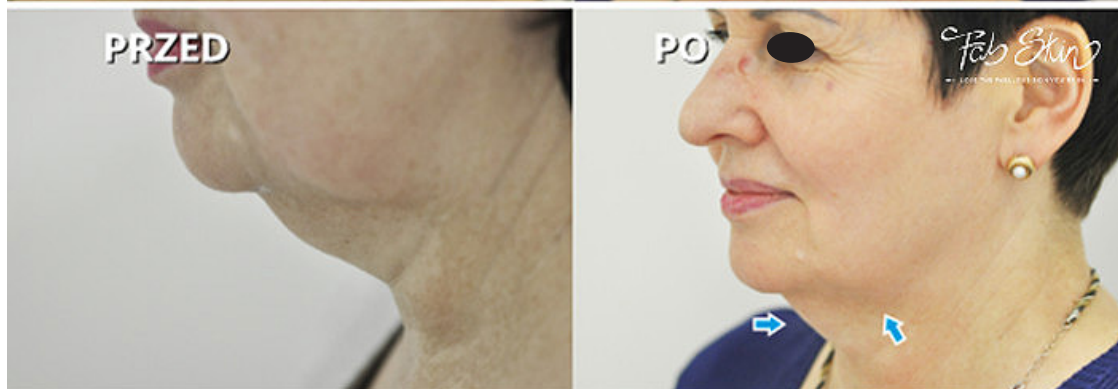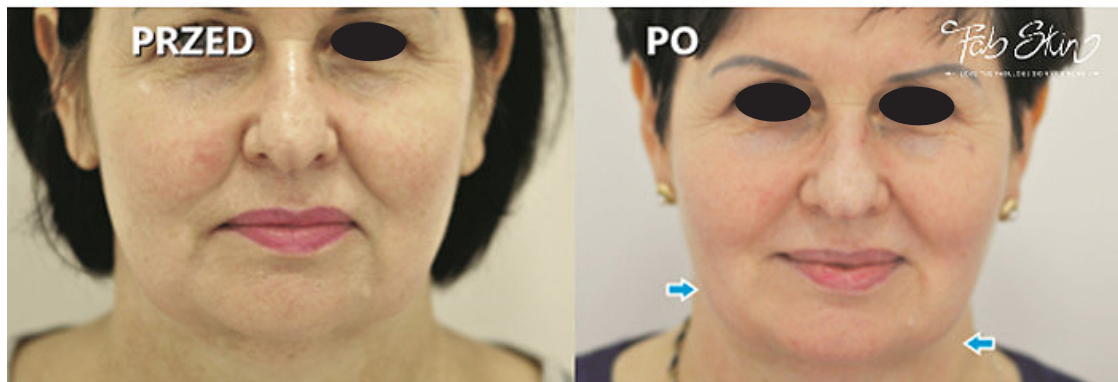
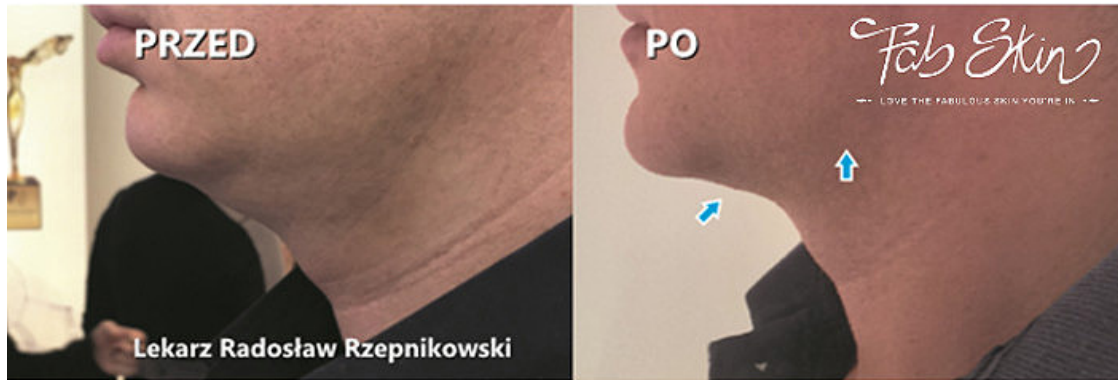solution utilizing a highly concentrated ultrasound beam to penetrate deeply into the tissues, allowing for the non-operative facelift of the body and face. One of its many advantages is the ability to perform surgery on any part of the body.

During the modeling process, a special head emitting ultrasonic waves is applied to the selected area of the patient's body that penetrates into the tissue. The heated tissues shrink, resulting in tension and increased skin tension. Skin smoothes, tightens, firms - giving spectacular effects like lifting. Ultraformer helps effectively eliminate slack, unsightly skin from places such as the abdomen, thighs, shoulders, neckline, neck.

The Ultraformer III has transducers of varying penetration depths ranging from 1.5 to 9 mm and therefore adapt to any skin type and age. Accurate power regulation makes the treatment perfectly suited to the conditions and needs of the patient.



ULTRAFORMER III





SMAS Face Lift with HIFU technology (High Intensity Focused Ultrasound) for the ULTRAFORMER Unit



Klaus FRITZ

SMAS Face Lift with HIFU Technology (High Intensity Focused Ultrasound) for the ULTRAFORMER III Unit

Klaus Fritz, MD | Germany

Speech at IECTC (International Educational Course-Training for Cosmetologists)
Dermatology
President German Academy of Dermatology (DDA)
Past President ESLD (European Society of Laserdermatology)
Lecturer and Consultant at University Osnabrueck(D)
AssociatUniv.-Professor at University of Medicine and Pharmacy Carol Davila (Ro)

BACKGROUND

As human gets older, skin and its under structural tissues constantly get ageing process. Typically, number of fibroblast on the skin decreases and collagen synthesis also decreases and functions and numbers of many skin appendages are also dropped. In the past, ablative laser or chemical peeling was used for face lifting. Recently, HIFU was introduced as a new treatment modality for skin tightening and rejuvenation. HIFU (High Intensity Focused Ultrasound)

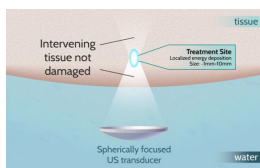
The deposition of acoustic energy can cause different bio-effects, such as transiently increasing cell and vessel permeability, tissue heating and irreversible tissue destruction. Achieving Non-invasive lifting procedure, temperature is critical factor. Micro-focused ultrasound heats tissue to $>60^{\circ}\text{C}$, to denature collagen and cause contraction of the collagen structure without damage surrounding area.

INTRODUCTION

Face and scalp are composed of several layers and these can be specifically composed into five standard layers: Skin, Subcutaneous layer, Musculoaponeurotic layer (SMAS: Superficial Muscular Aponeurotic System), Loose areolar tissue (spaces and retaining ligaments), fixed periosteum and deep fascia.

For the face lifting effect, target tissue is dermis, connective tissue in fat layer and SMAS (at a depth of 4.5mm beneath the skin. The HIFU (High Intensity Focused Ultrasound) is irradiated fractionally at a depth of 3.0 or 4.5mm). The SMAS at a depth of 4.5mm is coagulated by the focused beams of light (fascia, SMAS, fibrous tissue). Skin regeneration and lifting effect by newly formed collagen and elastin.

Focused ultrasound heat up 65~70 (only focal area)



vessel permeability, tissue heating and irreversible tissue destruction.

Achieving Non-invasive lifting procedure, temperature is

and coagulate the tissue at the target lifting-4.5mm, 3.0mm and 1.5mm depth.

METHOD

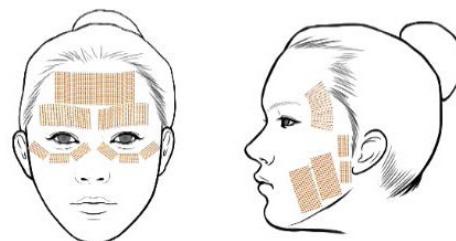
The best indications for face contouring are Forehead wrinkles, eyebrow, cheek, Jowl line, wrinkle lifting, skin tone improvement, V-line forming, double chin and neck wrinkle.

Focused ultrasound heat up 65~70°C (only focal area) and coagulate the tissue at the target lifting-4.5mm, 3.0mm, 2.0mm and 1.5mm depth standard treatment segments are as below. SIDE EFFECTS

The skin might appear flushed at first and the redness should disappear within a few hours factors affecting treatment response.

CONCLUSION

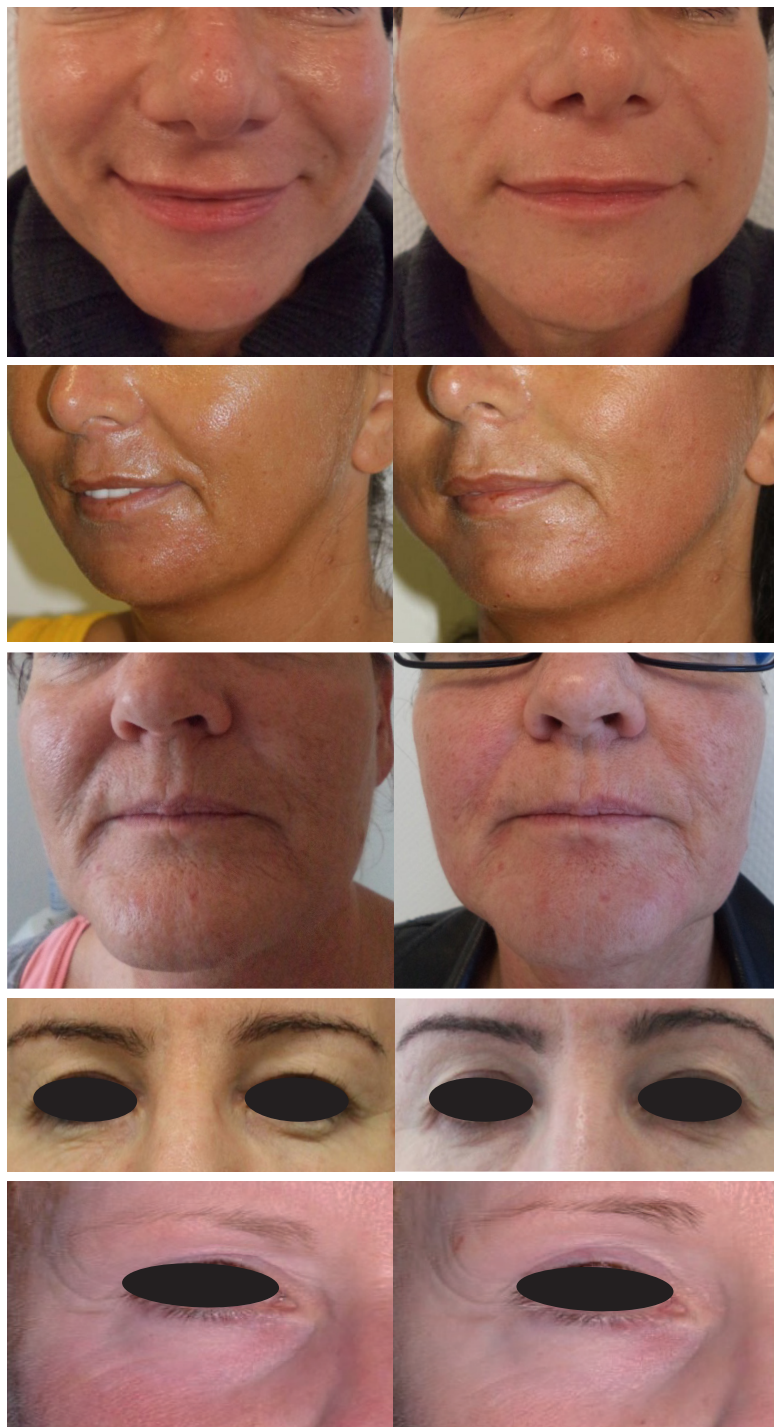There will always be patients who are candidates for surgery but just don't want to go under the knife. HIFU treatment will not provide them drastic results like face lifting surgery. However, it is the only non-invasive procedure which reaches the same layers of skin as are addressed in a surgical facelift. There are some factors affecting HIFU treatment response; skin laxity- amount



	Treatment Cartridge
Forehead	1.5mm
Around eyes	1.5mm
Cheek	3.0mm/4.5mm
Lateral neck	3.0mm/4.5mm
Submentum	3.0mm/4.5mm

of excess, loose skin on the face or neck, Volume: Degree and distribution of fat on the face, Skin quality: extent of lines, wrinkles, crepiness and sun damage. And Age and the lifestyle/health (smoker or nonsmoker, underlying health issues) can be the factors as well.

HIFU treatment creates new collagen at multiple depths within the skin for a more multi-dimensional approach. Patients will likely need more than one treatment to get the results and will keep them coming back every 1~2 years for continued maintenance.





The Most Exciting International Evolution in the
Non-surgical Facelift



Serena Lim, MD

The Most Exciting International Evolution in the Non-surgical Facelift

Serena Lim, MD | Australia

Hailed as the 'next evolution' in aesthetic science, the Ultraformer has taken the anti-ageing world by storm by performing the same procedure as cosmetic surgeons – but without cutting or disrupting the skin.

Necks, eyelids, chins, jawlines, brows and areas of the body that are wrinkling or sagging, such as armpits, stomachs, thighs, will lift under the ultrasound technology of the Ultraformer. And the bonus is that it can be performed over 30 minutes in a lunchtime break with no down-time, minimal side-effects and is almost completely pain free.

"Turkey necks, droopy eyelids, lowered brow lines, surface pores, even flabby arms and thighs: these are all areas the Ultraformer treats with immediate and ongoing results," says Dr. Serene Lim. "Plastic surgeons in Europe are raving about this treatment due to the results in face and body contouring and tightening."

After years of research and working in the industry, Dr. Serene has long steered away from treatments in facial rejuvenation that have possible side-effects. So Ultraformer ticks all the boxes and is an affordable and less-frequent alternative to many procedures on the market.

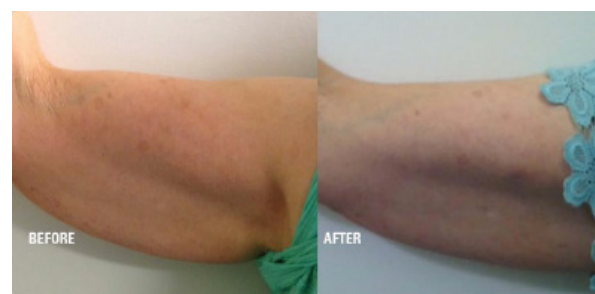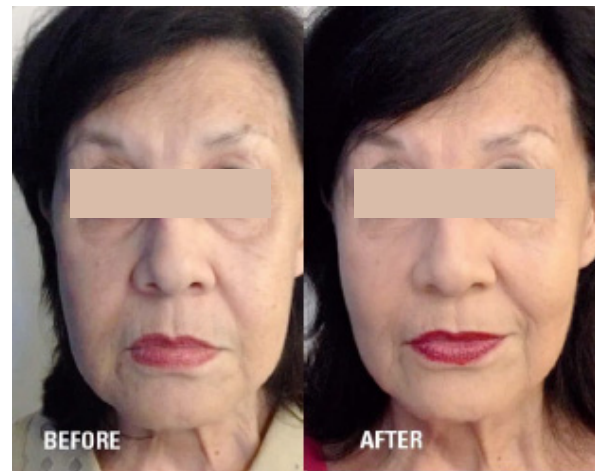"It is very precise, so the fat layer of the skin can be spared and fat necrosis avoided. All other modalities in facial rejuvenation treat the surface of the skin to the deep layers, so there is potential for more wrinkle formation when fat is destroyed, and pain when the nerve-rich dermis is affected. That won't happen with the Ultraformer, and it is almost pain-free," she says.

The treatment takes about 30 minutes and is completely safe. It works through the ultrasound, which has been used in medicine for more than 70 years, contracting and shortening muscle fibres, which causes the lifting effect, stimulating collagen for a plumping youthful appearance or reducing fat for stubborn fatty deposits like under the chin.

"I am always after a natural face and one that can be achieved with minimal side-effects (some people may experience short term redness and/or tenderness). Ultraformer ticks all the boxes for me.

It's a really exciting treatment in the facial rejuvenation area and my clients are more than happy with the results we are achieving," says Dr Serene.

The Ultraformer is the only treatment on the international market that works on the muscle fascia (SMAS) deep below the skin, which is the area surgeons tighten for face and neck lifts. Rather than using a needle or knife, the Ultraformer harnesses ultrasound technology to radiate energy to this layer to tighten and lift.





ULTRAFORMER Achieves Effective Non-surgical
Face Lifting, Tightening and Whitening



Klaus Fritz | Franco Lauro | Beom-Joon Kim

ULTRAFORMER Achieves Effective Non-surgical Face Lifting, Tightening, and Whitening

Klaus Fritz et al. | Germany, Italy & South Korea



Klaus Fritz, M.D.
Director
Dermatology and Laser
Centers Landau, Germany
Lecturer
University of Osnabrueck
Germany



Franco Lauro, M.D.
Plastic Surgeon
Private Practice
Bologna, Italy



Beom-Joon Kim, M.D., Ph.D.
Department of Dermatology
College of Medicine
Chung-Ang University
Seou I, Korea

Ever since its recent entrance in the aesthetic market, the Ultraformer device from Classys, Inc. globally continues to impress physicians and their patients with excellent face and neck lifting treatment outcomes. This innovative device offers cosmetic patients a variable non-invasive option to more traditional surgical lifting and tightening treatment approaches.

"In my opinion, the Ultraformer device is going to have a significant impact in the aesthetic industry," said Klaus Fritz, M.D., director of the Dermatology and Laser Centers in Landau, Germany, lecturer at the University of Osnabrueck, Germany, and former president of the European Society of Laser Dermatology. "The treatment outcomes one can achieve for face lifting and skin tightening with this device are remarkable."

Based on mature, time-tested High Intensity Focused Ultrasound (HIFU) technology, Ultraformer effectively treats the superficial and deeper dermis, as well as the superficial muscular aponeurotic system (SMAS) with a triple layer lifting effect. Heating the targeted area to between 65 and 75°C, the highly focused acoustic energy creates thermal coagulation zones at 1.5mm, 3.0mm and 4.5mm depths, optimally penetrating the skin with geometric precision, while completely sparing the epidermis.

"HIFU affects all three layers of the superficial and mid-dermis as well as the SMAS, a method that may be more effective than one-pass protocols for skin tightening," said Beom Joon Kim, M.D., ph.D., a professor in the department of dermatology, at the

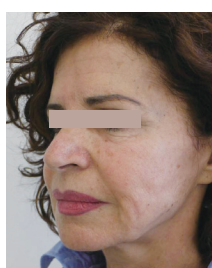College of Medicine, Chung-Ang University, Seoul, Korea.

Certified by the Korean FDA for eyebrow lifting and CE marked, Ultraformer can also achieve excellent aesthetic outcomes in molar augmenting jowl lifting, nasolabial fold reduction and periorbital wrinkle reduction, as well as overall skin tightening and rejuvenation in targeted areas. "In my experience, the speed and simplicity of the treatment, coupled with the excellent cosmetic results one can achieve, distinguish the Ultraformer device from any other laser treatments employed for the same indications;"

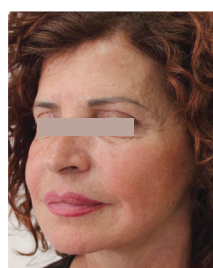Dr.Fritz stated.

Collagen is the primary protein in the dermis, along with subcutaneous fat and the SMAS. It is a family of structural proteins responsible for the strength and resilience of the skin and other tissues. HIFU energy heats the collagen fibers leading to denaturation. This in turn results in a thickening and shortening of the collagen fibers, greater tissue tension due to the rubber elastic properties of collagen, and ultimately, tissue tightening.

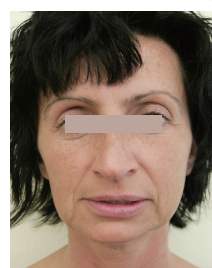Soon after an Ultraformer treatment session, patients will appreciate a firmer feel to the skin, along with a smoothing of fine lines. While this immediate plumping effect is temporary, it signals the initiation of the neocollagenesis process."Following the initial effects, a wound healing response is initiated in the skin, resulting in the formation of new collagen fibers, which provides tightening of the skin in a longer term.



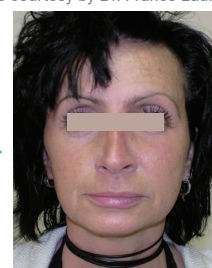BeforeTx



Post 2 months



BeforeTx



Post 2 months


Photo courtesy by Dr. Franco Lauro

After four weeks of treatment, patients' facial contours and fine wrinkles show significant improvement. Additional skin firming and tightening has shown over the next two to three months after treatment," Dr. Kim reported. This non-invasive procedure is associated with no downtime, allowing patients to return to daily activities immediately after the treatment, and dramatic results can be achieved as well with improvements seen in facial skin tightening and fine wrinkles up to six months after. Maintenance treatments could then be performed at three or six month intervals, depending on the degree of lifting and tightening that needs to be addressed in the individual patient at baseline.

"In my experience, the Ultraformer is the best device I have ever used for soft tissue and skin tightening," said Franco Lauro, M.D., a plastic surgeon in private practice in Bologna, Italy. Treatments are extremely quick, with a typical face and neck tightening procedure lasting approximately 20 minutes, allowing patients to quickly return to their daily routine."

According to Dr. Lauro, there is no downtime associated with the Ultraformer procedure and to date, he has not seen any complications from treatment underscoring the device's safety. "Using the Ultraformer, I can easily and safely treat every part of the body, and all Fitzpatrick skin types without hesitation, he added, "we can even combine treatment with other complementary aesthetic procedures in the same session."

Featuring dual handpiece, the Ultraformer device offers a fluence of 0.1 to 1 J, and is equipped with three different cartridges ideal for the triple layer HIFU treatment approach, namely L7-3: 7 Mhz(3 mm), L4-4.5: 4 Mhz(4.5mm), and L2-1.5:7 Mhz(1.5 mm). Beyond its benefits in skin tightening, as well as face and neck lifting, the Ultraformer device has also shown its effectiveness in lightening skin, further demonstrating its versatility in cosmetic treatments. Dr. Kim, who



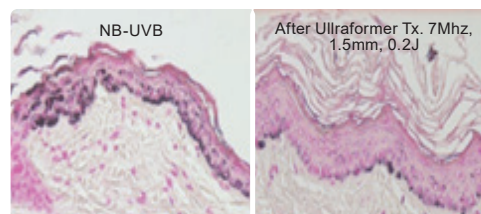
[Meat Test]

[Plastic Test]

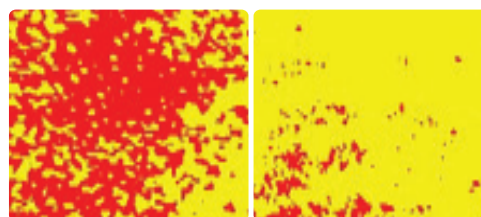
is also a professor at the R&D Center of the Chung-Ang University Hospital-appointed by The Ministry of Education of the Republic of Korea for the Brain Korea 21 Plus project team in the arena of dermatological science (2013-2020) - has explored the Ultraformer's effectiveness for this indication.

"I have performed NB-UVB examinations for the treatment of pigmentation in brown guinea pigs. From our research, my team and I have observed significant changes in skin pigmentation and can confirm the Ultraformer's efficacy in lightening the skin of animal models. We emitted both 0.1 J and 0.2J of the device's L7-1.5 settings in the study. Using these parameters, the lightening effect was observed three weeks following a protocol of four treatments per week for a month period." Dr. Kim[®] reported.


Numbers of melanin have been reduced after Ultraformer treatment by 7Mhz 1.5mm depth at 0.2J. The results were observed by Fontana Masson Stain, Image Pro Analysis and Folliscope as following picture of [1] [2] [3].



[1] Fontana Masson Stain



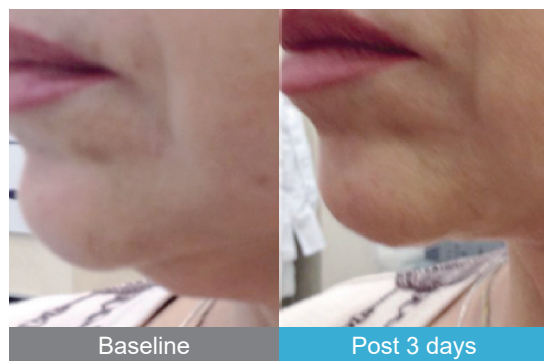
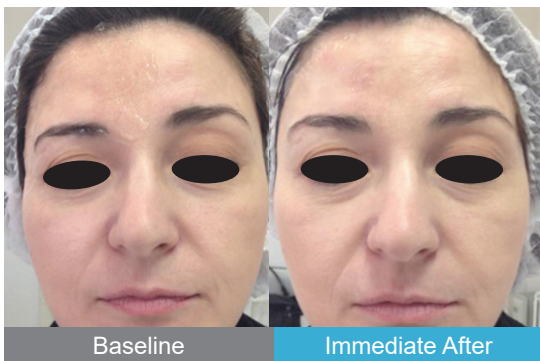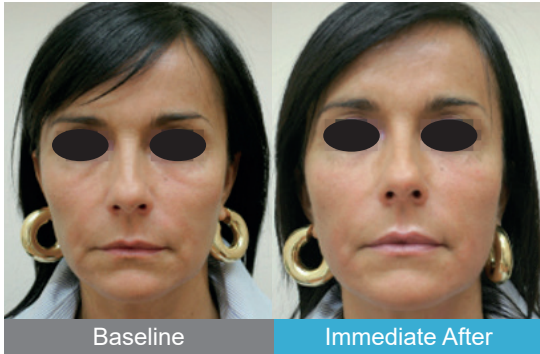[2] Image Pro Analysis



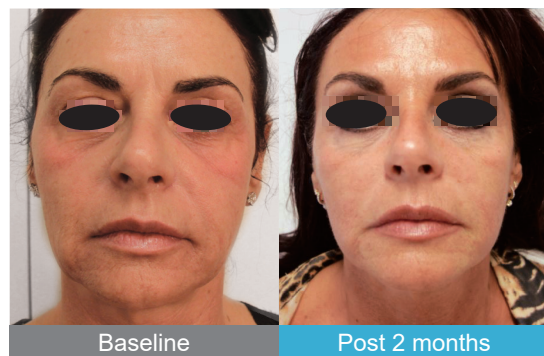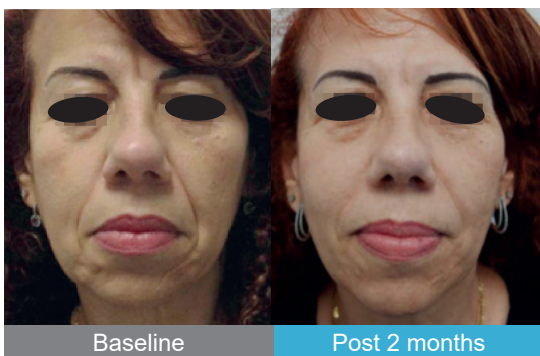
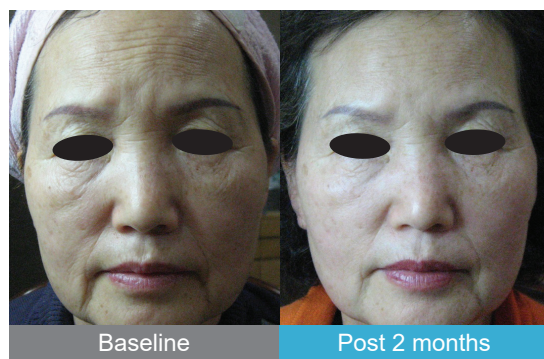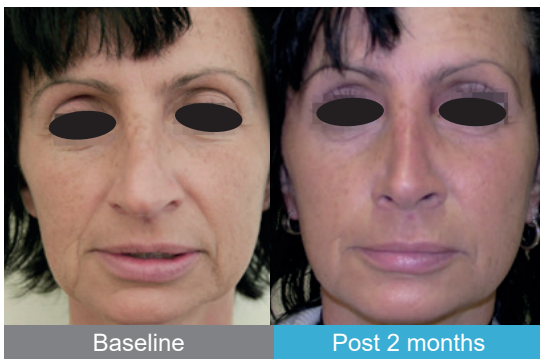[3] Folliscope

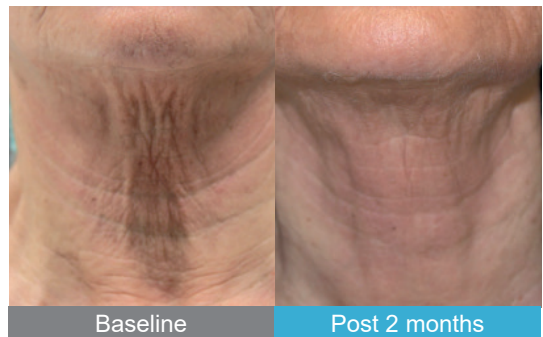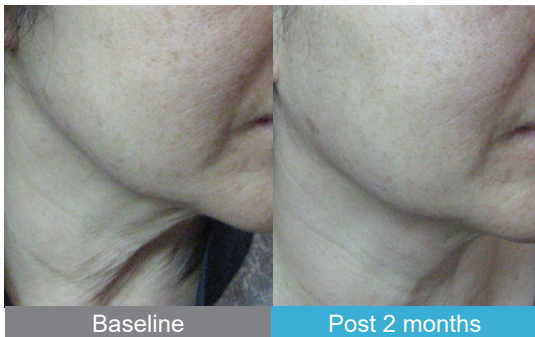
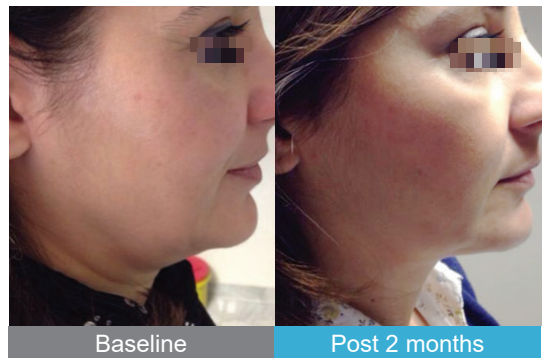
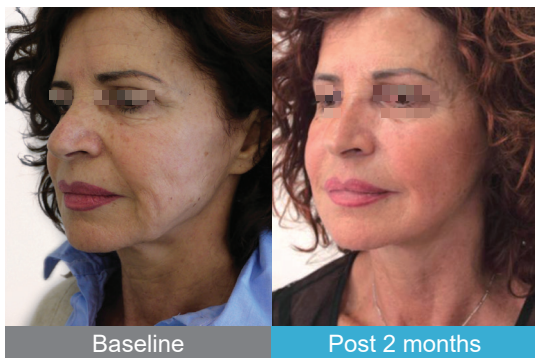
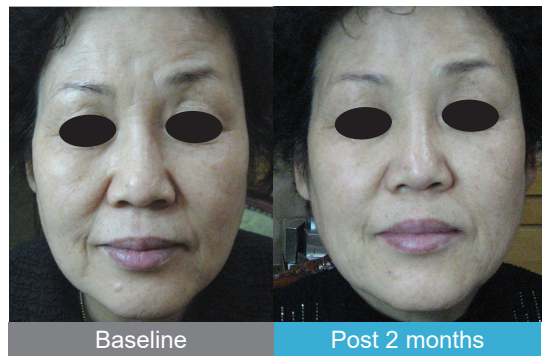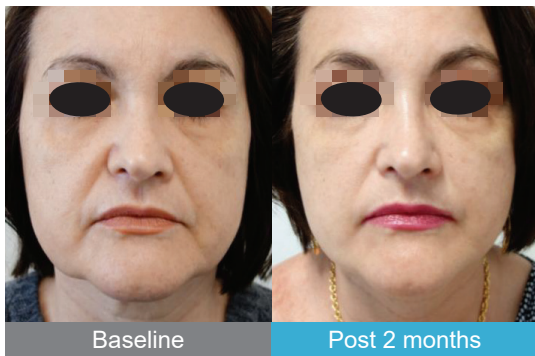[®] Dr. Beam June Kim, professor at R&D Center of the Chung-Ang University Appointed by The Ministry of Education of the Republic of Korea for the Brain Korea 21 Plus project team in the arena of dermatology science (2013-2020)

Face & Neck lifting immediate and post few days

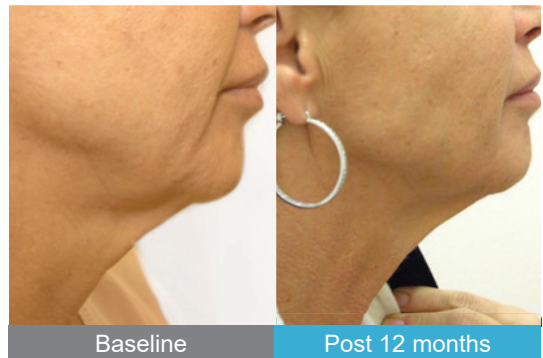
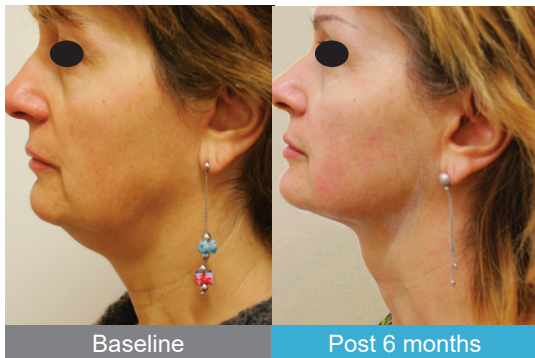
Results post 2 month





Results post 6 month and 12 month





Evaluation of Micro Focused Ultrasound for Lifting and Tightening the Face



In Ho Lee | Seung Min Nam | Eun Soo Park | Yong Bae Kim

Evaluation of Micro-focused Ultrasound for Lifting and Tightening the Face

In Ho Lee et al. | South Korea

Background Micro-focused ultrasound (MFU) has developed as an effective, noninvasive, skin-tightening method. However, certain factors have limited its replacement of invasive surgical procedures, including a relative lack of efficacy, persistence, and reliability. The purpose of this study was to evaluate the efficacy and safety of MFU for noninvasive skin tightening and to determine how long the skin tightening can be maintained.

Methods Between October 2013 and November 2014, 41 patients with sagging and laxity of the facial skin were treated with MFU. The treatment was performed following the manufacturer's recommended protocol that called for 300 treatment lines. We evaluated the patients using an automatic skin diagnosis system at pretreatment, and 2 and 4 months after treatment.

Results Of the 41 patients treated using MFU, 3 patients were lost to follow-up for nonstudy-related reasons. In our study, 38 patients (1 male and 37 female) were evaluated and ranged in age from 37 to 52 years. The median skin grade scores were 5 at pre-treatment, 3 at 2 months post-treatment and 3 at 4 months post-treatment. After comparing pre-treatment and 2 months post-treatment, pre-treatment and 4 months post-treatment, and both 2 and 4 months post-treatment, there were statistically significant differences ($P < 0.01$).

Conclusions This study suggests that the aging face, with wrinkling and sagging, can be improved using MFU, while minimizing injury to the epidermis and dermis.

Keywords Micro-focused Ultrasound, Aging face, Lifting

INTRODUCTION

The signs of aged facial skin are not only fine lines and

surface irregularities, but also sagging and wrinkling [1]. Noninvasive skin tightening is superior to invasive or surgical skin tightening in terms of rapid return to work, short recovery time, and low risk of adverse events. Because of these advantages, patients who desire a skin-tightening procedure prefer noninvasive skin tightening to invasive or surgical skin tightening [1,2].

To meet the demand of patients for noninvasive skin tightening, numerous devices have been developed. Laser and radiofrequency devices have been developed to resolve skin wrinkling and sagging [1-8]. Recently, micro-focused ultrasound (MFU) was developed as an effective noninvasive skin-tightening method. MFU is able to heat tissue greater than 60°C and produce a small thermal coagulation zone (<1 mm³) to reach the mid- to deep reticular layers of the dermis and subdermis while minimizing overlying papillary dermal and epidermal injury [9-11]. The delivery of MFU to a targeted zone in the superficial musculoaponeurotic system (SMAS) provokes immediate contracture of denatured collagen and the initiation of neocollagenesis and collagen remodeling [10,12]. This action of MFU provokes noninvasive skin tightening and lifting of sagging facial skin. Certain factors have limited its replacement of invasive surgical procedures, including a relative lack of efficacy, persistence, and reliability. The purpose of this study was to evaluate the efficacy and safety of MFU for noninvasive skin tightening and to determine how long the skin tightening can be maintained.

METHODS

Between October 2013 and November 2014, 41 patients with sagging and laxity of the facial skin were treated

Received: May 13, 2015 Revised: May 27, 2015 Accepted: May 27, 2015

Correspondence: Seung Min Nam Department of Plastic and Reconstructive, Soonchunhyang University Bucheon Hospital, 170 Jomaru-ro, Wonmi-gu, Bucheon 420-767, Korea. E-mail: zodiac1003@naver.com

Copyright © 2015 The Korean Society for Aesthetic Plastic Surgery. This is an Open Access article distributed under the terms of the Creative Commons Attribution Non-Commercial

License (<http://creativecommons.org/licenses/by-nc/3.0/>) which permits unrestricted non-commercial use, distribution, and reproduction in any medium, provided the original work is properly cited. www.e-aaps.org This is an Open Access article distributed under the terms of the Creative Commons Attribution Non-Commercial License (<http://creativecommons.org/licenses/by-nc/4.0/>) which permits unrestricted non-commercial use, distribution, and reproduction in any medium, provided the original work is properly cited.

with MFU using 4-MHz, 4.5 mm and 7-MHz, 3.0 mm depth transducers (Ultraformer®, Classys Inc., Seoul, Korea). Treatment was performed following the manufacturer's recommended protocol that called for 300 treatment lines. Patients with active systemic or local infections, local skin diseases that might alter wound healing, history of psychiatric illness, and soft tissue augmentation material were excluded from this study.

Pretreatment preparation

Five percent lidocaine, as a topical anesthetic ointment (EMLA, AstraZeneca, Sdertlje, Sweden), was applied to the face for 45 minutes before the procedure. The ointment was washed off with mild soap and water immediately before the procedure.

Ultrasound exposure protocol

The ultrasound gel was applied to the skin. The transducer was placed firmly on the targeted skin surface and pressed uniformly for coupling to the skin. Treatment exposure was initiated (4-MHz, 4.5 mm depth transducers; 0.9 J/mm² and 7-MHz, 3.0 mm depth transducers; 0.8 J/mm²), with a line of individual ultrasound pulses being delivered within approximately 2 seconds. Then, the transducer slid to the next location and was repositioned 3 to 5 mm laterally such that it was adjacent and parallel to the previous treatment line. Complete treatment of the face required 15 to 20 minutes.

Post-treatment care

The ultrasound gel was washed off. Patients experienced mild redness and swelling that could persist for several days. Patients were instructed to visit our hospital promptly if they encountered any other adverse effects.

Table 1. Patients Characteristics

Characteristic	Value
Sex (Female, Male)	37, 1
Mean Age (range)	46 (37-52)

Outcome evaluation

We evaluated the patients using an automatic skin diagnosis system(A-One Lite®, BOMTECH Electronics

Co., Seoul, Korea) at pretreatment, and 2 and 4 months after treatment. The automatic skin diagnosis system evaluated skin laxity using a scanner. The sagging and laxity of the skin were graded from 1 to 6 using the system. A high skin grade score means that the sagging and laxity of the skin are severe. The clinician examined the skin for evidence of edema, erythema, hypopigmentation, and hyperpigmentation after treatment.

Statistical analysis

Statistical analyses were performed using SPSS version 20.0 (SPSS Inc., Chicago, IL, USA). The Friedman test was used to compare the grade scores of patients at pretreatment, and 2 and 4 months after treatment. A P value less than 0.05 was considered statistically significant.

RESULTS

All patients were treated using MFU and three patients were lost to follow-up for non-study related reasons. In our study, 38 patients (1 male and 37 female) were evaluated and ranged in age from 37 to 52 years (Table 1).

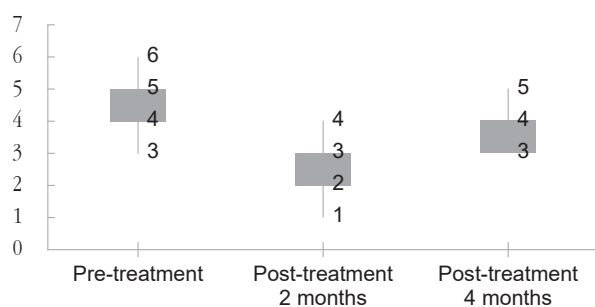


Fig. 1. Comparisons of skin grade scores at pre-treatment and 2 months post-treatment, pre-treatment and 4 months post-treatment 4 months, and 2 and 4 months post-treatment.

Table 2. The skin grade score

Time	Pre-treatment (Median)	Post-treatment 2 months (Median)	Post-treatment 4 months (Median)	P-value*, †, ‡
Skin grade score	5*, † (4-5)	3*, † (2-3)	3†, ‡ (3-4)	< 0.01

*, †, ‡P-value by Wilcoxon signed rank test.

Thirty-five patients immediately presented with slight erythema and edema after treatment, and three patients immediately presented with moderate erythema and edema after treatment. In all affected patients, both erythema and edema completely resolved by 2 days after treatment. Two patients presented with red linear striations of the cheek after treatment with the 3 mm transducer. They were treated using focal cooling without sequelae such as pigmentation and textural

abnormalities. Hypopigmentation, hyperpigmentation, ulceration, and erosion were not present in any patients. There were no adverse events, such as nerve or muscle dysfunction, severe pain, bruising, and bleeding. The median skin grade scores were 5 (4-5) at pretreatment, 3 (2-3) at 2 months post-treatment, and 3 (3-4) at 4 months post-treatment (Fig. 1 and Table 2). After comparing pre-treatment and 2 months post-treatment, pre-treatment and 4 months post-treatment,

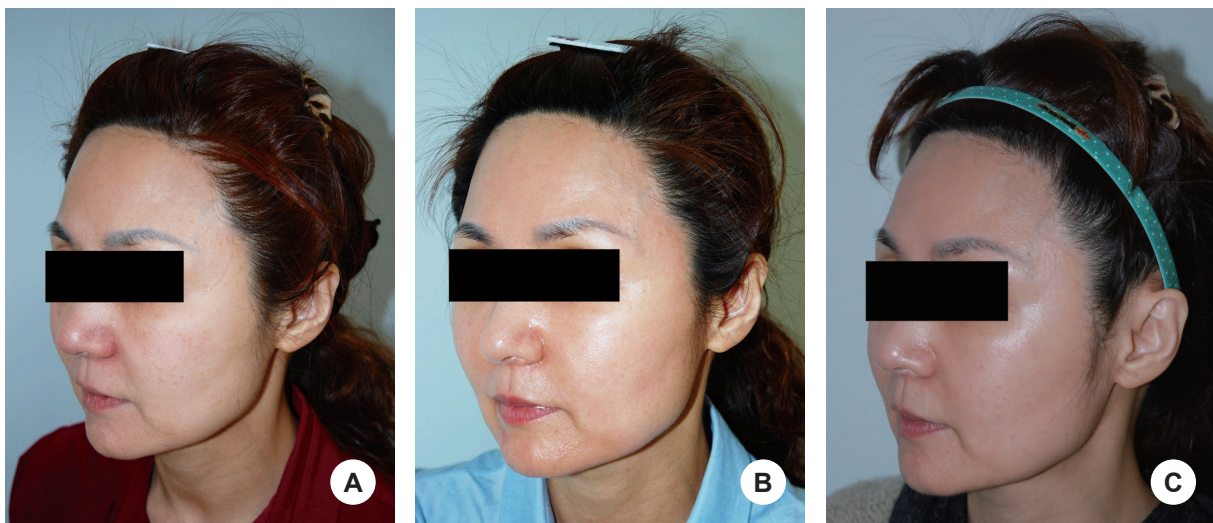


Fig. 2. A 46-year-old female patient with moderate skin sagging and wrinkling. At pre-treatment, she was examined by the automatic skin diagnosis system and was given a skin grade score of 5 (A). At 2 months post-treatment, the skin grade score was 2 (B). At 4 months post-treatment, the skin grade score was 4 (C).

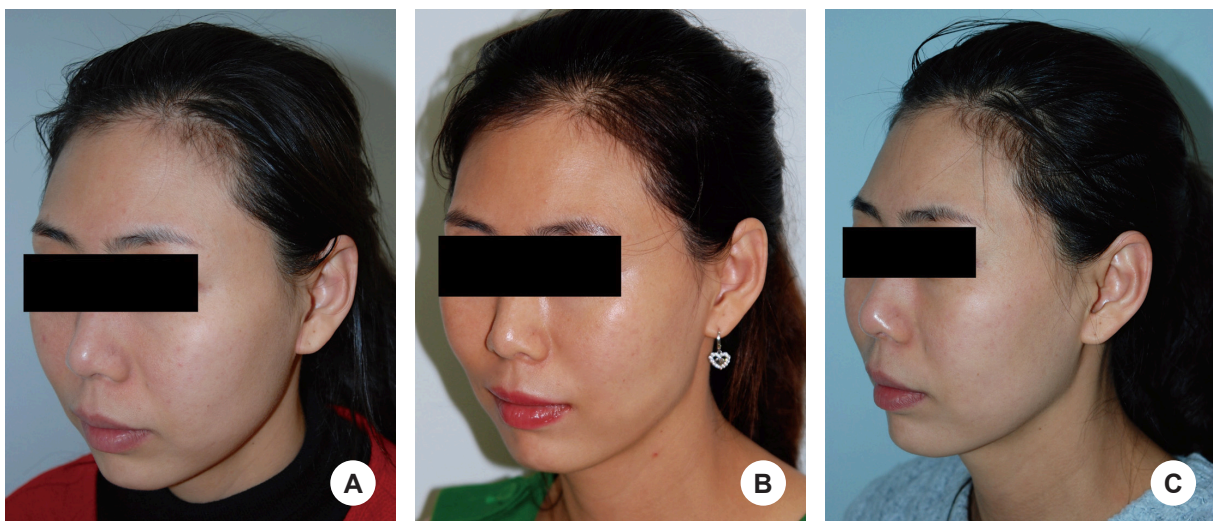


Fig. 3. A 38-year-old female patient with moderate skin sagging and wrinkling. At pre-treatment, she was examined by the automatic skin diagnosis system and was given a skin grade score of 4 (A). At 2 months post-treatment, the skin grade score was 2 (B). At 4 months post-treatment, the skin grade score was 3 (C).

and both 2 and 4 months post-treatment, there was a statistically significant difference in skin grade score ($P < 0.01$) (Fig. 2 and 3).

DISCUSSION

The SMAS consists of viscous, elastic fibers and extracellular matrix [10,13,14]. It is associated with specific facial muscles, such as the platysma, orbicularis oculi, and levator labii superioris. Collagen within SMAS decreases 6% every decade [10]. This decrease in collagen contributes to a prominent nasolabial fold, and hooding of the brow and jowl [10,15,16]. To minimize post-treatment adverse events, clinicians have developed various non-ablative skin-tightening procedures to induce collagen shrinkage and remodeling [3,6,17]. Furthermore, ultrasound is able to penetrate into the subdermis layer and SMAS, and induce thermal coagulation to avoid undesired post-treatment adverse events compared with carbon-dioxide laser resurfacing [17-19].

Ultrasound energy has characteristics that are suitable for skin lifting and tightening. First, it is believed that ultrasound energy can be transmitted into the deeper subcutaneous layer of the face or even the SMAS, and is the most effective method for skin lifting and tightening [13,14,20-23]. Second, both the epidermis and dermis can be protected from ultrasound energy during its transmission, reducing the risk of advertent cutaneous layers [1].

Ultrasound used in medicine is classified into two types. One is high-intensity focused ultrasound (HIFU) and the other is MFU. HIFU uses high energy and is mainly used for nonsurgical ablation of tumors. HIFU can also be used to ablate adipose tissue for body contouring [10]. MFU uses much lower energy to treat the superficial layer of the skin [9] and is able to elevate the local temperature higher than 60°C to cause collagen contracture [24]. When energy is targeted to discrete areas within dermal and subdermal tissues,

MFU induces discrete thermal coagulation zones while sparing adjacent non-target tissues [9,11,12,25]. In addition, the heat induces the denaturation and contraction of collagen fibers in the subcutaneous fat layer [26].

According to the results of our study, skin tightening at 2 and 4 months post-treatment was improved compared to pretreatment. However, skin tightening at 2 months post-treatment was better than at 4 months post-treatment, suggesting the efficacy of MFU gradually decreases treatment. Based on our results, we recommend that retreatment should be performed after 3 months for greater efficacy.

Our study had limitations. First, our study did not include patients who had severe skin sagging and wrinkling. We recommended the surgical face-lift procedure for these patients. Second, the post-treatment results were evaluated with an automatic skin diagnosis system, but the reliability of the system has not been established. Therefore, discrepancies may occur between the automatic skin diagnosis system and realistic skin conditions. Third, our study did not include any histologic evaluations. Fourth, the MFU device that we used in our study is not capable of clearly imaging the targeted facial anatomy. We cannot ensure proper acoustic coupling between the transducer and skin before the application of MFU energy. Despite these limitations, the results were evaluated objectively.

CONCLUSION

This study suggests that the aging face, with wrinkling and sagging, can be improved using MFU, while minimizing injury to the epidermis and dermis. In addition, retreatment is recommended after 3 months to maintain the efficacy of the results.

PATIENT CONSENT

Patients provided written consent for the use of their images.

REFERENCES

1. Alam M, White LE, Martin N, et al. Ultrasound tightening of facial and neck skin: a rater-blinded prospective cohort study. *J Am Acad Dermatol* 2010;62:262-9.
2. Dover JS, Zelickson B. Results of a survey of 5,700 patient monopolar radiofrequency facial skin tightening treatments: assessment of a lowenergy multiple-pass technique leading to a clinical end point algorithm. *Dermatol Surg* 2007;33:900-7.
3. Fitzpatrick R, Geronemus R, Goldberg D, et al. Multicenter study of noninvasive radiofrequency for periorbital tissue tightening. *Lasers Surg Med* 2003;33:232-42.
4. Fitzpatrick RE, Goldman MP, Satur NM, et al. Pulsed carbon dioxide laser resurfacing of photo-aged facial skin. *Arch Dermatol* 1996;132:395-402.
5. Goco PE, Stucker FJ. Subdermal carbon dioxide laser cutaneous contraction. *Arch Facial Plast Surg* 2002;4:37-40.
6. Kim KH, Geronemus RG. Nonablative laser and light therapies for skin rejuvenation. *Arch Facial Plast Surg* 2004;6:398-409.
7. Kirsch KM, Zelickson BD, Zachary CB, et al. Ultrastructure of collagen thermally denatured by microsecond domain pulsed carbon dioxide laser. *Arch Dermatol* 1998;134:1255-9.
8. Zelickson BD, Kist D, Bernstein E, et al. Histological and ultrastructural evaluation of the effects of a radiofrequency-based nonablative dermal remodeling device: a pilot study. *Arch Dermatol* 2004;140:204-9.
9. Fabi SG. Noninvasive skin tightening: focus on new ultrasound techniques. *Clin Cosmet Investig Dermatol* 2015;8:47-52.
10. Fabi SG, Goldman MP. Retrospective evaluation of micro-focused ultrasound for lifting and tightening the face and neck. *Dermatol Surg* 2014;40:569-75.
11. Laubach HJ, Makin IR, Barthe PG, et al. Intense focused ultrasound: evaluation of a new treatment modality for precise microcoagulation within the skin. *Dermatol Surg* 2008;34:727-34.
12. White WM, Makin IR, Barthe PG, et al. Selective creation of thermal injury zones in the superficial musculoaponeurotic system using intense ultrasound therapy: a new target for noninvasive facial rejuvenation. *Arch Facial Plast Surg* 2007;9:22-9.
13. Ghassemi A, Prescher A, Riediger D, et al. Anatomy of the SMAS revisited. *Aesthetic Plast Surg* 2003;27:258-64.
14. Har-Shai Y, Bodner SR, Egozy-Golan D, et al. Mechanical properties and microstructure of the superficial musculoaponeurotic system. *Plast Reconstr Surg* 1996;98:59-70.
15. Kikkawa DO, Lemke BN, Dortzbach RK. Relations of the superficial musculoaponeurotic system to the orbit and characterization of the orbitomalar ligament. *Ophthal Plast Reconstr Surg* 1996;12:77-88.
16. Psillakis JM, Rumley TO, Camargos A. Subperiosteal approach as an improved concept for correction of the aging face. *Plast Reconstr Surg* 1988;82:383-94.
17. Fabi SG, Massaki A, Eimpunth S, et al. Evaluation of microfocused ultrasound with visualization for lifting, tightening, and wrinkle reduction of the décolletage. *J Am Acad Dermatol* 2013;69:965-71.
18. Alster TS, Tanzi E. Improvement of neck and cheek laxity with a nonablative radiofrequency device: a lifting experience. *Dermatol Surg* 2004;30:503-7.
19. Kennedy JE, Ter Haar GR, Cranston D. High intensity focused ultrasound: surgery of the future? *Br J Radiol* 2003;76:590-9.
20. Har-Shai Y, Sela E, Rubinstien I, et al. Computerized morphometric quantitation of elastin and collagen in SMAS and facial skin and the possible role of fat cells in SMAS viscoelastic properties. *Plast Reconstr Surg* 1998;102:2466-70.
21. Mendelson BC. Surgery of the superficial musculoaponeurotic system: principles of release, vectors, and fixation. *Plast Reconstr Surg* 2001;107:1545-52.
22. Mitz V, Peyronie M. The superficial musculo-aponeurotic system (SMAS) in the parotid and cheek area. *Plast Reconstr Surg* 1976;58:80-8.
23. Thaller SR, Kim S, Patterson H, et al. The submuscular aponeurotic system (SMAS): a histologic and comparative anatomy evaluation. *Plast Reconstr Surg* 1990;86:690-6.
24. Hayashi K, Thabit G, 3rd, Massa KL, et al. The effect of thermal heating on the length and histologic properties of the glenohumeral joint capsule. *Am J Sports Med* 1997;25:107-12.
25. Gliklich RE, White WM, Slayton MH, et al. Clinical pilot study of intense ultrasound therapy to deep dermal facial skin and subcutaneous tissues. *Arch Facial Plast Surg* 2007;9:88-95.
26. Ferraro GA, De Francesco F, Nicoletti G, et al. Histologic effects of external ultrasound-assisted lipectomy on adipose tissue. *Aesthetic Plast Surg* 2008;32:111-5.



Tightening Effects of High Intensity Focused Ultrasound on Body Skin and Subdermal Tissue: A Pilot Study



S.Y. Choi | Y.A. No | S.Y. Kim | B.J. Kim | M.N. Kim

Tightening Effects of High Intensity Focused Ultrasound on Body Skin and Subdermal Tissue: A Pilot Study

S.Y. Choi et al. | South Korea

S.Y. Choi,¹ Y.A. No,¹ S.Y. Kim,² B.J. Kim,^{1,*} M.N. Kim¹

¹Department of Dermatology, Chung-Ang University College of Medicine, Seoul, South Korea

²Department of Applied Statistics, Chung-Ang University, Seoul, South Korea

*Correspondence: B.J. Kim. E-mail: beomjoon@unitel.co.kr

ABSTRACT

Background High Intensity Focused Ultrasound (HIFU) has been introduced as a new treatment modality for skin tightening through application mainly to the face and neck.

Objectives This pilot study assessed the efficacy and safety of HIFU for body tightening in Asian females.

Methods Six Asian female adults were enrolled in this pilot study. All subjects were treated with HIFU to the both cheek, upper arm, lower abdomen, thigh and calf using the following probes: 7 MHz, 1.5 mm focal depth; 2 MHz, 3.0 mm focal depth; 2 MHz, 4.5 mm focal depth; 2 MHz, 6.0 mm focal depth and 2 MHz, 9.0 mm focal depth. Three blinded independent dermatologists assessed results using the Investigator Global Aesthetic Improvement Scale (GAIS) using paired pre- and post-treatment (week 4) standardized photographs. Also, we evaluated skin elasticity at all treated sites using a cutometer. Participants used the subject GAIS to assess their clinical improvement after treatment and rated their pain using a visual analogue scale (VAS) immediately, 1 and 4 weeks after treatment.

Results The three blinded evaluators judged all treated

sites as showing clinical improvement 4 weeks after treatment. Skin elasticity measured via cutometer was significantly improved 4 weeks after treatment at all treated sites ($P < 0.05$). All patients scored themselves subjectively as more than 'improved' on the GAIS. Immediately after treatment the mean VAS score was 5.17–2.48, but no pain was reported at weeks 1 and 4. No permanent adverse effects were observed during the follow-up period.

Conclusion For body tightening, we applied HIFU using transducers with a lower frequency and deep focal depth to effectively deliver ultrasound energy to skin tissues. HIFU appears to be a safe and effective treatment modality for dermal and subdermal tightening. Received: 29 October 2015; Accepted: 15 March 2016

CONFLICTS OF INTEREST

None declared.

FUNDING SOURCES

None declared.

INTRODUCTION

As skin tissue ages, its elasticity decreases and redundant facial, neck and body laxity are commonly seen. Various treatment modalities including surgical, laser and radiofrequency approaches have been used to improve skin laxity. Surgical lifting procedures for skin laxity are effective, but can leave visible surgical scars and are associated with risk and lengthy recovery times. Recently, patients seeking skin tightening are requesting safe and effective non-invasive alternatives associated with low risks and minimal downtime.

High Intensity Focused Ultrasound (HIFU) has been investigated as a tool for the treatment of solid benign and malignant tumours for the past several decades.¹ HIFU can produce small, micro-thermal lesions at

precise depths in the dermis up to the fibromuscular layer, causing thermally induced contraction of collagen and tissue coagulation with subsequent collagenesis, while sparing the epidermis.^{2–4} Recently, HIFU has been introduced as a new treatment modality for skin tightening and rejuvenation, primarily for the face and neck.⁵ This pilot study was performed to assess the efficacy and safety of HIFU treatment for skin tightening treatment of body skin laxity in Asian females.

PATIENTS AND METHODS

Patients

This pilot study was approved by the Institutional Review Board of Chung-Ang University Hospital and followed the guidelines of the 1975 Declaration of Helsinki.

Based on the suggestion of a statistical committee, we referred to a previous study⁶ to determine the number of subjects required for the current study. Six female adults were enrolled in the study.

HIFU device

The HIFU device used in this study was the ULTRAFORMER III, SHURINK (CLASSYS INC., Seoul, Korea). In this study, we used five different types of transducers. One of the transducers was a basic transducer for facial skin tightening (T1: 7 MHz, 1.5 mm focal depth). Four other transducers utilizing a lower frequency and deeper focal depths were newly developed for body skin tightening (T2: 2 MHz, 3.0 mm focal depth, T3: 2 MHz, 4.5 mm focal depth, T4: 2 MHz, 6.0 mm focal depth and T5: 2 MHz, 9.0 mm focal depth). Each transducer delivered a series of ultrasound pulses along 25-mm long exposure lines. The pulse duration for each individual exposure ranged from 25 to 40 milliseconds.

Treatment procedures

Before treatment, we checked the patients, the thickness of skin components and all patients underwent treatment in five different areas including the both cheek, upper arm, lower abdomen, thigh and calf after topical anaesthetic cream. The sizes of the treated areas were 5.0 x 5.0 cm² on each cheek and 7.5 x 7.5 cm² on the lower abdomen as well as each upper arm, thigh and calf (Fig. 1).

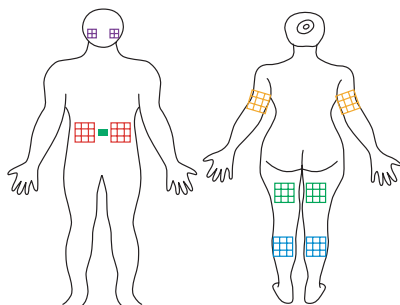


Figure 1 Face and body treatment areas.

Ultrasound gel was applied to the treated skin and the transducer was pressed perpendicularly, uniformly and firmly to the skin surface. Treatment exposure was initiated with a line of individual ultrasound pulses being

delivered over approximately 2s. Next, the probe was moved approximately 3 to 5 mm laterally so as to be parallel and adjacent to the line previously treated and the ultrasonic exposure was repeated.

Each side of the face was treated with three types of transducers (T1, T2 and T3), distributing a total of 552.5 J. Each side of the body was treated with five types of transducers (T1, T2, T3, T4 and T5), distributing a total of 817.2 J. We operated the powers with 1.0–1.5 J at each transducer. When patient feel pain, we reduced 0.1–0.3 J per time, but not increased up to 1.5 J. Complete HIFU treatment of the face and body occurred over 50–60 min. We prefer to use the shallow depth tips to deep depth tips. Because patient's pains are usually proportional to depth of tips.

Efficacy and pain evaluation

We evaluated the skin tightening effect of HIFU using photography and a cutometer. The investigator gathered digital photographs using identical cameras and camera settings (Canon EOS 600D, high-resolution setting, 5760 x 3840 pixels, Canon Inc., Tokyo, Japan) before and 4 weeks after the treatment. Three blinded independent dermatologists evaluated paired before and after photographs in a randomized fashion using the Investigator Global Aesthetic Improvement Scale (IGAIS). Subjects assessed the tightening effects using the Subject Global Aesthetic Improvement Scale (SGAIS) 4 weeks after treatment.

The Cutometer (Courage+Khazaka Electronic GmbH, Cologne, Germany) was used to measure skin elasticity. Among the cutometer-specific R values (R0–R9), we used the R7 value, which is defined as the ratio of elastic recovery to the total deformation and represents the biological elasticity. Pain was evaluated by visual analogue scale (VAS) immediately after week 0 and on weeks 1 and 4 after the application of HIFU. VAS is a simple and reproducible tool for the assessment of pain severity which consisted of 11 levels (0–10 points).

Statistical analysis

Statistical analyses were performed using SPSS version 18.0 for Windows (SPSS Inc., Chicago, IL). We used Hochberg step-up methods to adjust the values for multiple comparisons. Statistical comparisons between

before and after treatments were performed using paired t tests. Data are presented as means ± standard deviation. $P_s < 0.05$ were considered statistically significant.

RESULTS

Six Asian female subjects (Fitzpatrick skin types III–V) with skin laxity were enrolled in this study. Their ages ranged from 43 to 54 years (mean ± SD: 48.17 ± 4.45 years) and showed similar skin depth. All subjects completed the HIFU treatments and follow-up for 4 weeks. The mean value of skin elasticity measured by cutometer was significantly increased at 4 weeks after treatment compared to baseline in all treated sites on the face and body (Fig. 2). The change in the mean value of skin elasticity measured by cutometer was greatest in the lower abdomen (Fig. 3). Three blinded independent dermatologists judged all patients as showing clinical improvement 4 weeks after treatment. In terms of cheek outcomes, 5 (83.3%) of 6 subjects were assessed as improved (IGAIS score 1), and 1 (16.7%) of 6 subjects as much improved (IGAIS score 2).

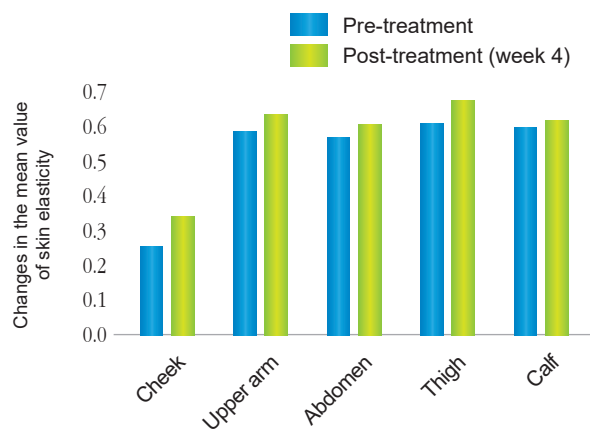


Figure 2 Changes in the mean value of skin elasticity measured via cutometer (R7, mean ± SD).

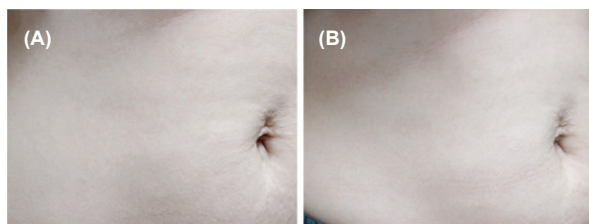


Figure 3 The change in the skin elasticity in the lower abdomen (a) 0 week and (b) after 4 weeks.

In terms of body outcomes, including the upper arm, lower abdomen, thigh and calf, 6 (100%) of 6 subjects were assessed as improved (IGAIS score 1).

All subjects scored the SGAIS as more than score 1 in all treated sites. The mean SGIAS score in the calf was the highest. In the calf, 2 (33.3%) of 6 subjects were assessed as improved (SGAIS score 1), 2 (33.3%) of 6 subjects as much improved (SGAIS score 2) and 2 of (33.3%) 6 subjects as very much improved (SGAIS score 3).

We evaluated pain using the VAS immediately after treatment (week 0) and at weeks 1 and 4. Immediately after treatment, the mean VAS score was 5.17 ± 2.48 (range: 3–8). Three (50%) of six subjects rated their pain as mild, and 3 of (50%) 6 subjects rated their pain as moderate. One and 4 weeks after treatment, all subjects reported a VAS score of 0 (no pain).

One subject experienced edema on the right upper arm and one subject had muscle pain on the right calf after HIFU treatment. Both edema and muscle pain were mild and transient, and resolved within 1 week without any treatment. There were no serious or delayed adverse effects during the follow-up period.

DISCUSSION

Recently, minimally invasive or non-invasive procedures have been gradually replacing surgical intervention in cosmetic dermatology. For the treatment of skin laxity, non-invasive, non-ablative thermal therapeutic devices can immediately denature collagen fibres and contract collagen fibres in the dermis and subcutaneous tissues and induce delayed neocollagenesis and elastogenesis.^{7,8} Radiofrequency, infrared light sources and HIFU have shown clinical effects for skin tightening and rejuvenation on the face and neck. However, there have been fewer clinical trials or reports of skin and subdermal tightening effects of non-ablative thermal devices in sites on the body, compared to the face and neck.

In this pilot study, we sought to assess the efficacy and safety of HIFU treatments using transducers that were newly developed to be suitable for use on the body skin and subdermal tissue for the purpose of skin tightening in body laxity in Asian people. A previous clinical report on the effects of HIFU on tightening of

the periorbitum and body sites, which enrolled a total of 82 patients including 8 Asians, has been published. However, this previous clinical study used conventional HIFU transducers (10 MHz, 1.5 mm focal depth; 7 MHz, 3.0 mm focal depth and 4 MHz, 4.5 mm focal depth). We applied newly developed transducers to body sites with a lower frequency (2 MHz) and deeper focal depths (3.0–9.0 mm) compared with conventional transducers. Therefore, we expected that newly developed transducers could effectively deliver HIFU energy deeper into the skin and subdermal tissues of the body and show tightening effects and safety. Of course, it may effect to subcutaneous areas with 9.0 mm transducer. But it can reduce subcutaneous fats and lead to skin rejuvenation. Also, other reports said that if practitioner consider skin depths and regulate transducers well, 1.1–1.6 mm transducers are safe to use.⁹

Although we applied topical anaesthetic cream on treated sites, most subjects complained of a mild to moderate degree of pain during treatment in proportion to depth or power of transducers. Their pain subsided without the use of analgesics, but the injection of small amounts of local anaesthesia into the subcutaneous tissue should be considered for pain reduction.

In conclusion, HIFU treatment using transducers with a lower frequency and greater focal depth could be an effective and safe treatment modality for skin and subdermal tightening of the body. The limitations of this pilot study were the small number of subjects and the short-term follow-up period. Based on the results of this pilot study, well-designed controlled clinical studies with greater subject enrolment and long-term follow-up will be necessary to establish optimal treatment parameters.

REFERENCES

1. Laubach HJ, Makin IR, Barthe PG et al. Intense focused ultrasound: evaluation of a new treatment modality for precise microcoagulation within the skin. *Dermatol Surg* 2008; 34: 727–734.
2. Alam M, White LE, Marin N et al. Ultrasound tightening of facial and neck skin: a rater-blinded prospective cohort study. *J Am Acad Dermatol* 2010;62: 262–269.
3. Suh DH, Shin MK, Lee SJ et al. Intense focused ultrasound tightening in Asian skin: clinical and pathologic results. *Dermatol Surg* 2011; 37: 1595–1602.
4. Lee HS, Jang WS, Cha YJ et al. Multiple pass ultrasound tightening of skin laxity of the lower face and neck. *Dermatol Surg* 2012; 38: 20–27.
5. Lee HJ, Lee KR, Park JY et al. The efficacy and safety of intense focused ultrasound in the treatment of enlarged facial pores in Asian skin. *J Dermatology Treat* 2015; 26: 73–77.
6. DiBernardo BE, Evaluation of skin tightening after laser-assisted liposuction. *Aesthet Surg J*. 2009;29:400–407.
7. Chua SH, Ang P, Khoo LS et al. Nonablative infrared skin tightening in Type IV to V Asian skin: a prospective clinical study. *Dermatol Surg* 2007;33: 146–151.
8. Hantash BM, Ubeid AA, Chang H et al. Bipolar fractional radiofrequency treatment induces neoelastogenesis and neocollagenesis. *Laser Surg Med* 2009; 41: 1–9.
9. Solish N, Lin X, Axford-Gatley RA et al. A Randomized, Single-Blind, Postmarketing Study of Multiple Energy Levels of High-Intensity Focused Ultrasound for Noninvasive Body Sculpting. *Dermatol Surg* 2012; 38:58–67.

ULTRAFORMER III

Lifting Tightening Contouring